

## Case Report

# Uncommon variant of pre-axial polydactyly and its surgical management: a case report

Alejandro Quiroga-Garza<sup>1,2\*</sup>, Kouatzin Aguilar-Morales<sup>1</sup>, Fabian Contreras-Gonzalez<sup>2</sup>,  
Rodrigo Enrique Elizondo-Omaña<sup>1</sup>, Santos Guzmán-López<sup>1</sup>

<sup>1</sup>Human Anatomy Department, Universidad Autonoma de Nuevo Leon, Facultad de Medicina, Monterrey, Nuevo Leon, Mexico

<sup>2</sup>Instituto Mexicano del Seguro Social, Cirugía General, México

**Received:** 10 October 2019

**Accepted:** 16 November 2019

### \*Correspondence:

Dr. Alejandro Quiroga-Garza,  
E-mail: [dr.aquirogag@gmail.com](mailto:dr.aquirogag@gmail.com)

**Copyright:** © the author(s), publisher and licensee Medip Academy. This is an open-access article distributed under the terms of the Creative Commons Attribution Non-Commercial License, which permits unrestricted non-commercial use, distribution, and reproduction in any medium, provided the original work is properly cited.

## ABSTRACT

We report the case of an adult patient with thumb polydactyly. The pre-axial thumb is in a non-functional flexion, while the 1<sup>st</sup> thumb maintains normal function. X-ray of the hand reveals a “T” shape 1<sup>st</sup> metacarpus bone, giving origin to the pre-axial polydactyly. Although this variation is not specifically described in the Wassel classification, we classify it as a type V of the Rotterdam’s classification. Patient is managed surgically, using a dynamic incision for polydactyly amputation. The polydactyly thumb has no identifiable muscle/tendon structures responsible of this unique deformation. The procedure results in good post-operative evolution with aesthetic scarring, and integral thumb function.

**Keywords:** Polydactyly, Pre-axial, Duplicated thumb, Anatomy, Radiology

## INTRODUCTION

Polydactyly is an axial malformation defined as supernumerary fingers in the foot or hand. It has a prevalence of 1.73 per every 1,000 live births worldwide, with a higher incidence in blacks (up to 13 cases per 1,000 births). The majority occurs sporadically as an isolated trait, however, it may be associated to genetic alternated syndromes, or environmental factors such as exposure to teratogenic agents during embryonic development.<sup>1</sup> The diagnosis is clinical and should be made at birth or at first contact. A radiological evaluation is essential during early stages of life to classify the pathology and determine the best surgical treatment.<sup>2</sup>

Characterization may be classified into 3 regions, according to its location: pre-axial (1<sup>st</sup> finger or toe), central (2<sup>nd</sup> to 4<sup>th</sup> fingers or toes) and post-axial (5<sup>th</sup> finger or toe). Post-axial polydactyly is the most common, with

a higher incidence in male gender, and 50% of cases bilateral.<sup>1</sup>

The most common thumb polydactyly consists of a duplication of both, the proximal and distal phalanges, originating from a single metacarpal. It is most commonly observed on the right hand, when the case is unilateral. Familial thumb polydactyly has low genetic penetrance, even though it has an autosomal dominant inheritance pattern.<sup>3</sup>

This pre-axial deformation can be sub-classified based on the phalanx duplication. The Wassel classification developed in 1969, is commonly used by pediatric surgeons and popular worldwide for its simplicity.<sup>4</sup> The classification is simple, however, it does not provide information on the dominant thumb, stability, or joint functionality.<sup>2</sup> Likewise, the classification itself does not provide the location and origin of the accessory phalanx,

which contributes fundamental morphological information, necessary for surgical planning.<sup>5</sup>

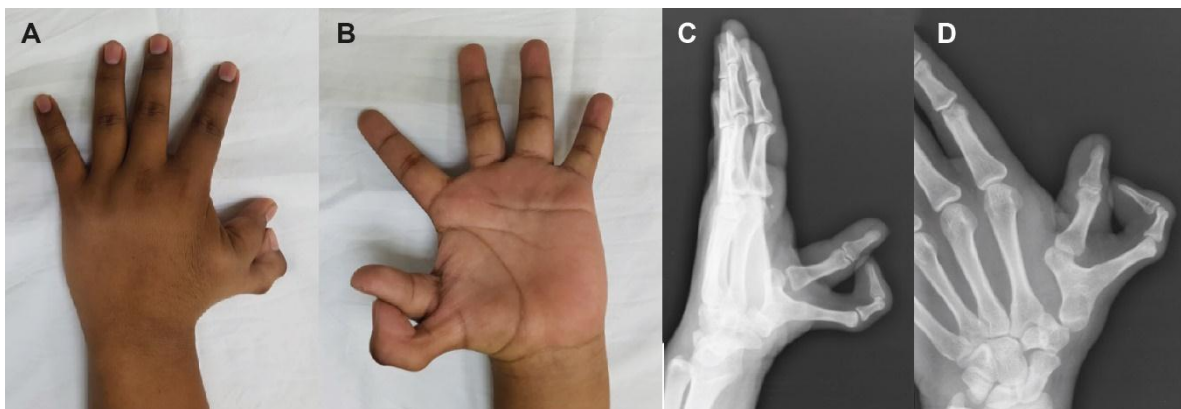Several of the previous scales proposed presented the limitation of leaving several variants of polydactyly unclassified.<sup>4,6</sup> Zuidam et al, proposed a classification that integrated the essential elements to incorporate all the defects of the thumb: the Rotterdam classification. It includes all types of tri-phalangeal and triplication of fingers, and provides a clear description of joint participation and aberrant components in all radial polydactyly.<sup>6</sup> The most common pre-axial types reported in the literature are IV y VI.<sup>6-9</sup>

Pre-axial polydactyly management is surgical, preferably during early stages of life. If left untreated, it can lead to angular deformity due to: shared flexor and extensor tendons with a common origin and a distal "Y" division, bridge connections between them, eccentric insertions, or alteration in the shape of the articular surface.<sup>9</sup> Adding to this, the psycho-social factors for the child, if left untreated.

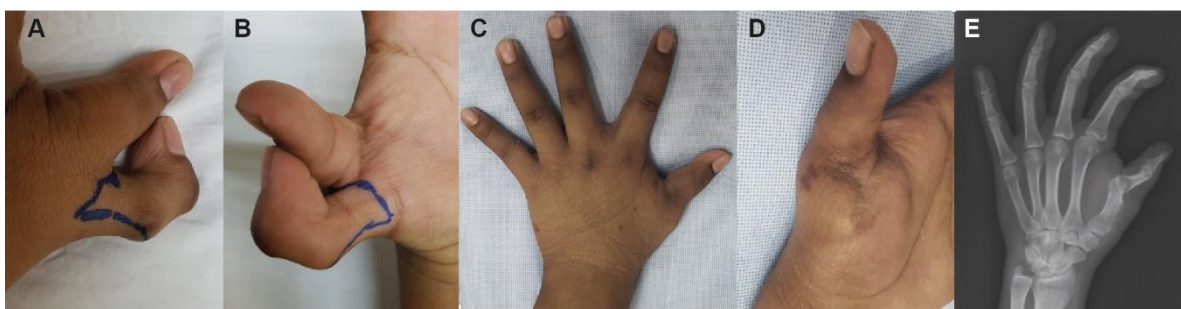
We discuss the morphological aspects of an adult patient attended with a Rotterdam type V pre-axial polydactyly, and its surgical management.

## CASE REPORT

An 18 year-old man is evaluated for polydactyly of the left thumb. Patient denies familiar history of previous polydactyly cases or any other important malformation and syndromes. The patient has a history of strabismus, operated during youth and was born from a teen-pregnancy. Denies any other important medical history. On physical examination, a pre-axial polydactyly of the left hand is identified (Figure 1). The pre-axial thumb is in a non-functional flexion, with forced movement at the interphalangeal and metacarpophalangeal joints. Metacarpal base without movement. Medial thumb with normal function. X-ray of hand in 2 positions reveals a "T" shape bone extension from the middle of the 1<sup>st</sup> metacarpus, giving origin to the pre-axial polydactyly (Figure 1). Carpometacarpal joint without evident pathological data. Metacarpophalangeal joint of functional thumb with slight dislocation or increased space, without clinical symptoms.



**Figure 1: Pre-axial polydactyly of left hand. (A) dorsal view; (B) Palmar view; (C) lateral X-ray projection; (D) posterior-anterior X-ray projection.**



**Figure 2: Surgical planning and post-surgical results of polydactyly amputation; blue line marks the planned incision; (A) dorsal view of incision; (B) palmar view of incision; (C) dorsal view of post-surgical hand; (D) lateral-anterior view of hand and scar; (E) oblique X-ray projection of post-surgical hand.**

The patient accepts surgical treatment and signs informed consents. Under the effects of sedation and local anesthesia, a dynamic incision (Figure 2) is made,

allowing amputation of pre-axial thumb, leaving a flap for wound closure. Procedure was performed by dissecting the soft tissue. No tendons or muscle structures

of the pre-axial thumb are identified. Pre-axial metacarpus is dissected with osteotomy and remodeling of its base. Procedure is performed without complications, and minimal bleeding. Post-surgical management included thumb splint immobilization. Patient continues good post-operative evolution, without significant pain, and satisfactory aesthetic result at the one-month postoperative check-up (Figure 2). Control X-ray shows satisfactory resection with improvement of dislocation of thumb and decrease of space in metacarpophalangeal joint (Figure 2). Functional evaluation of thumb without alterations, mobility integrated, normal grip strength, no loss of sensibility, no other evident pathological clinical data.

## DISCUSSION

Polydactyly has a broad range of incidence depending of race, genetics, etiology and other associated factors.<sup>1</sup> Previous studies demonstrate a wide variability regarding classification, which are important for morphological classification. A proper understanding of the anatomy involved leads to effective surgical planning and better post-surgical outcomes. The Rotterdam classification is the most accepted, as it differentiates types of polydactyly.<sup>4-6</sup> The most common type reported is type IV preaxial (29% Rotterdam, 30% Wassel).<sup>7,8</sup>

We report a case of pre-axial bi-phalangeal thumb polydactyly that is not symmetrical nor parallel to the phalange, but rather with a perpendicular 90° angulation, forming a “T” shape. Although this exact variation is not described in the Rotterdam classification, we consider it would apply as a type V (7% incidence), due to its morphological origin from the 1<sup>st</sup> metacarpus, respecting the carpometacarpal joint.<sup>7,8</sup> The deformity could have been exacerbated with time, due to the tendons and muscles shared with the thumb, however none of these were found during surgical dissection, suggesting a possible atrophy.<sup>9</sup> However, the polydactyly had a fixed flexion that could not be extended without external aid, which could be due to fibrosis of the atrophic muscles.

Several genetic syndromes could be related to this case and should be considered as differential diagnosis, due to the relationship between polydactyly and strabismus. The most likely are SALL4 (Sal-like protein 4)-related disorders, such as the Okihiro, Duane-radial ray, acro-renal-ocular, and IVIC syndromes. Many of these are autosomal dominant, mostly associated with family history. Deafness, renal anomalies, and imperforate anus may also be co-inherited, however, our patient did not present any of these, nor did he have family history of polydactyly.<sup>3</sup>

Other genetic syndromes related to polydactyly and strabismus may be accompanied with renal/urogenital abnormalities, nervous system malformations and impairments, developmental delays, episodic tachypnea or apnea, liver disease, cardiac defects, hypogonadotropic

hypogonadism, macrocephaly, distinctive facial features and deformities.<sup>10</sup> None of these have been identified or diagnosed in our patient, nor has there been any suspicion of, therefore no further studies were indicated.

There are several options for polydactyly amputation and reconstruction. We conducted a dynamic incision allowing for reconstruction of the thumb, and closure of the wound with a cutaneous skin flap from the amputated phalange. The outcome had satisfactory aesthetic scarring (Figure 2) and functional results.

Although psychosocial evaluation was not performed in this case, it was noted that the patient constantly held his hand out of plain sight or placed his thumb inside a closed fist. The latter could be the motive why the pre-surgical X-rays demonstrate an increased space in the metacarpophalangeal joint. This improved after amputation. Surgical treatment is recommended from 1 to 2.5 years of age to avoid complication, both functional and psychosocial, improving quality of life.<sup>2,11</sup>

*Funding: No funding sources*

*Conflict of interest: None declared*

*Ethical approval: Not required*

## REFERENCES

1. de Oliveira R, Ribak S, Irisarri C. Polidactilias del pulgar. Tratamiento quirúrgico. Rev Iberoam Cirugía la Mano. 2016;44(02):118-30.
2. Pacheco YD, Lorca-García C, Berenguer B, De Tomás E. Preaxial polydactyly of the hand: 15 years of experience. Cir Pediatr. 2015;28(4):188-92.
3. Umair M, Ahmad F, Bilal M, Ahmad W, Alfadhel M. Clinical Genetics of Polydactyly: An Updated Review. Front Genet. 2018; 1-9.
4. Van Wyhe RD, Trost JG, Koshy JC, Pederson WC. The duplicated thumb: A review. Semin Plast Surg. 2016;30(4):181-7.
5. Chung MS, Baek GH, Gong HS, Lee HJ, Kim J, Rhee SH. Radial polydactyly: Proposal for a new classification system based on the 159 duplicated thumbs. J Pediatr Orthop. 2013;33(2):190-6.
6. Dijkman RR, Van Nieuwenhoven CA, Selles RW, Habenicht R, Hovius SER. A multicenter comparative study of two classification systems for radial polydactyly. Plast Reconstr Surg. 2014;134(5):991-1001.
7. Wassel H. The results of surgery for polydactyly of the thumb. A review. Clin Orthop Relat Res. 1969;64:175-93.
8. Zuidam JM, Selles RW, Ananta M, Runia J, Hovius SER. A Classification System of Radial Polydactyly: Inclusion of Triphalangeal Thumb and Triplication. J Hand Surg Am. 2008;33(3):373-7.
9. Netscher DT, Baumholtz MA. Treatment of congenital upper extremity problems. Plast Reconstr Surg. 2007;119(5):101e-129e.

10. Abu-Amero KK, Kondkar AA, Hellani AM, Bosley TM, Khan AO. Chromosome 6 microdeletion in a patient with syndromic congenital cranial dysinnervation disorder. *Neurosciences*. 2016;21(1):72-4.
11. Jia ZW, Bai DM, Long JT, Guo XS, Tian Y, Zhang LQ, et al. Optimal surgical timing and treatment of thumb duplication in children. *Zhonghua Zheng Xing Wai Ke Za Zhi*. 2013;29.5:336-40.

**Cite this article as:** Quiroga-Garza A, Aguilar-Morales K, Contreras-Gonzalez F, Elizondo-Omaña RE, Guzmán-López SE. Uncommon variant of pre-axial polydactyly and its surgical management: a case report. *Int Surg J* 2019;6:4535-8.