

Original Research Article

Peripheral vascular emergencies-clinicopathological co-relation with outcome in a tertiary care centre

Ankita Jain*, Uday Jadhav, Dwarkanath Kulkarni, Balaji Aironi,
Sushrut Potwar, Prashant Patil

Department of Cardiovascular and Thoracic Surgery, Seth GS Medical College and King Edward Memorial Hospital, Mumbai, Maharashtra, India

Received: 04 October 2023

Revised: 09 November 2023

Accepted: 17 November 2023

***Correspondence:**

Dr. Ankita Jain,

E-mail: nishunest@gmail.com

Copyright: © the author(s), publisher and licensee Medip Academy. This is an open-access article distributed under the terms of the Creative Commons Attribution Non-Commercial License, which permits unrestricted non-commercial use, distribution, and reproduction in any medium, provided the original work is properly cited.

ABSTRACT

Background: Peripheral arterial disease represents a major caseload in emergency department and also is major cause of distress and socio-economic burden to patient and his/her family due to risk of complications. It has a multifactorial etiology and requires prompt treatment to salvage the limb and prevent complications. This study is a clinic-pathological correlation between various factors and surgical outcome.

Methods: It is a prospective study involving 75 patients who had presented with peripheral vascular disease with different mode of presentations. All patients underwent surgical procedure and were given inj. heparin and tab. Aspirin in post operative period. Their surgical outcome was studied and co-related with etiological factors and clinical presentation.

Result: Time from onset till presentation was one of the most important factors in deciding outcome. COVID-19 also emerged as one of the important risk factors in 12 cases. Patients who had been given prior anticoagulation therapy had better outcomes.

Conclusions: Outcome in peripheral vascular disease patient depends on variable factors, however starting patients prior on anticoagulants has shown more possibility of salvaging the limb.

Keywords: Peripheral vascular disease, COVID-19, ALI

INTRODUCTION

Peripheral vascular disease represents a large number of cases presenting to our emergency department. The spectrum ranges from acute arterial occlusions, to trauma and venous thrombosis also. Acute lower limb ischemia (ALI) is a sudden deficit of limb perfusion, threatening extremity viability. Of all ALI patients, 80-85% suffer from arterial thrombosis, whereas the remaining 15-20% from embolic occlusions.¹ The clinical presentation is considered to be acute if it occurs within 14 days after symptom onset.² The incidence of ALI is approximately 1.5 cases out of 10,000 people per year.³ These patients experience increased in-hospital major adverse events including myocardial infarction, congestive heart failure

exacerbation, deterioration in renal function and respiratory complications.⁴ The sudden ischemia affects all the metabolically active tissues of the limb: skin, muscles, and nerves. Thus, urgent recognition with prompt revascularization is required to preserve limb viability.⁵ This study aims to establish clinic-pathological correlation of peripheral vascular disease with its outcome in a tertiary care centre.

METHODS

It is a prospective observational study conducted at department of CVTS, K. E. M. hospital, Mumbai from January 2021 to November 2022 with sample size-75.

Ethical approval was taken from institutional ethical committee.

Inclusion criteria

Both traumatic and non traumatic cases involving upper and lower limbs are included.

Exclusion criteria

Venous diseases like deep vein thrombosis-chronic arterial diseases presenting to OPD-AV malformations, arterial diseases involving neurovascular, gastrointestinal territory, pathology related to aorta like aneurysm or dissection and patients not suitable for surgical therapy were excluded from study.

Following factors have been studied in these patients and co- related with surgical outcome-1. Mode of presentation, 2. Time of presentation, 3. Co-morbidities, 4. Administration of pre-op anticoagulants and 5. Pre-op status of the limb.

All the patients presenting to Emergency department underwent USG- Colour Doppler and were given appropriate surgical treatment according to the mode of presentation.

All the post op cases were given injection heparin infusion for 48 hours and Tab. Aspirin 75 mg for 3 months.

All these above factors are co related with surgical outcome of the patient with statistical representation, to come to a conclusion.

The study was retrospective in nature. The patients were retrospectively analysed after

institutional ethical approval as no prospective intervention was planned further. The statistical software used was SAS version 6.09 on the Unix platform. Considering the observational nature of the study, no other computational software was required.

RESULTS

Mode of presentation

The following spectrum of cases presented to the emergency department during the study period, the highest being spontaneous thrombosis followed by penetrating injury to arterial wall in case of the polytrauma.

Time of presentation

Most of the traumatic cases presented within 6 hours of injury.

Table 1: Mode of presentation (n=75).

Cases	N	Management
Blunt trauma-contused segment	4	Interposition vein grafting
Transected arterial segment	8	End to end anastomosis using vein grafts
Penetrating injury to artery	14	Thrombectomy followed by primary repair of arterial wall.
Crush injuries	10	Interposition vein grafting
Spontaneous thrombosis	36	Thromboembolectomy
AV fistula rupture	3	AV fistula takedown

Table 2: Time of presentation (n=75).

Variables	<6 hours	>6 hours	Total
Upper limb	22	7	29
Lower limb	30	16	46

Associated co-morbidities

Most of the patients had multiple co-morbidities. History of recent COVID-19 infection was noted in 30 patients and emerged out to be an independent risk factor for development of spontaneous thrombosis.

Table 3: Associated comorbidities.

Co- morbidity	Upper limb	Lower limb
Diabetes mellitus	7	10
Hypertension and atherosclerosis	15	34
History of COVID-19 infection	16	14
Smoking	8	20
Chronic Renal disease	3	5

Pre-op anticoagulant administration

The 42 out of 75 patients were started on some form of anticoagulant or anti platelet therapy at primary care level before presenting to emergency room.

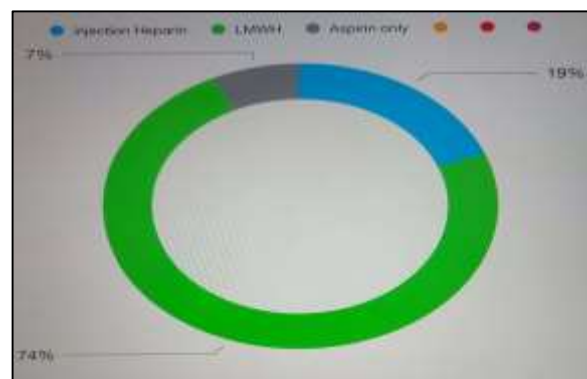

Figure 1: Pre-op anticoagulant administration.

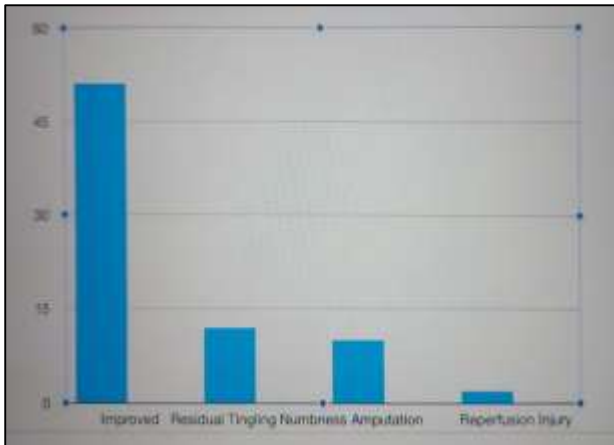


Figure 2: Pre-op status of the limb.

Pre-op status of the limb

At the time of presentation, 12 out of 75 patients had developed some form of ischemic changes ranging from skin discoloration to tingling numbness.

Out of 75 vascular emergencies-46 were lower limb vascular emergencies and 29 were involving upper limb. Time from onset till presentation was one of the most important factors in deciding outcome. Apart from trauma, COVID-19 also emerged as one of the important risk factors in 12 cases. Patients who had been given prior anticoagulation therapy had better outcomes.

DISCUSSION

Peripheral arterial disease has diversified etiology and multiple treatment options. Patients presenting in the golden period of 6 hours have better outcomes.

Associated co-morbidities like diabetes mellitus significantly impact the outcome due to development of microangiopathy. Presence of coronary artery disease is associated with increased incidence of peripheral vascular disease due to development of atherosclerotic changes in arteries. Valvular heart disease with atrial fibrillation predisposes to embolization of thrombus leading to acute arterial thrombosis of peripheral arteries. History of COVID-19 infection has emerged as an independent predisposing factor for spontaneous thrombosis.

SARS-CoV-2 is a novel RNA virus associated with the outbreak of a coronavirus-associated acute respiratory disease called coronavirus disease-19 (COVID-19) in humans.⁶ COVID-19 is a hypercoagulable and thrombogenic disease, characterized by a high incidence of venous and arterial thrombotic events, in particular in the most severely affected patients.⁷

The virus causes an immune cross reaction with the endothelium leading to endothelial inflammation and an inflammatory occlusive thrombus.⁸ Arterial thrombosis

has been reported in 3.7% of patients with severe COVID despite prophylactic anticoagulation.⁹

Smoking is one of the most important preventable factors causing peripheral arterial disease. Cigarette smoke extracts induce endothelial cell dysfunction, smooth muscle cell remodelling and macrophages phenotypic transformation through multiple molecular mechanisms.¹⁰

Patients given some form of anticoagulant therapy in pre-operative period showed better outcome with near full restoration of limb function. This is usually done to prolong time to surgery secondary to delayed patient presentation and delay in patient transfer to proper tertiary care centre.¹¹

The 51 out of 75 patients showed improvement in the post op period. Distal pulsations were palpable in the immediate post op with restoration of normal limb function. However, 12 patients complained of residual tingling numbness. Patients who had already developed ischemic changes like skin discoloration and tingling numbness complained of residual neurological deficit after surgery.

Ten patients developed complications like rethrombosis and gangrene and had to undergo amputation of the affected limb. Two out of 75 patients developed reperfusion injury with symptoms of severe pain, skin discoloration and reduced sensation over the limb.

Limitation of study were single centre study and small sample size.

CONCLUSION

Peripheral vascular emergencies represent significant amount of patient caseload in a tertiary care centre and the outcome depends on variable factors, however starting patients prior on anticoagulants has shown more possibility of salvaging the limb.

ACKNOWLEDGEMENTS

Authors would like to thank all the patients who willingly participated in the study and the concerned hospital for support in implementing a multidimensional approach.

Funding: No funding sources

Conflict of interest: None declared

Ethical approval: The study was approved by the Institutional Ethics Committee

REFERENCES

1. Walker TG. Acute Limb Ischemia. Tech Vasc Interv Radiol. 2009;12(2):117-29.
2. Creager MA, Kaufman JA, Conte MS. Clinical practice. Acute Limb Ischemia. N Engl J Med. 2012;366(23):2198-206.

3. Norgren L, Hiatt WR, Dormandy JA, Nehler MR, Harris KA, Fowkes FGR. Inter-society consensus for the management of peripheral arterial disease (TASC II). *J Vasc Surg.* 2007;45(S):S5-67.
4. Baril DT, Patel VI, Judelson DR, Goodney PP, McPhee JT, Hevelone ND et al. Vascular Study Group of New England. Outcomes of lower extremity bypass performed for acute limb ischemia. *J Vasc Surg.* 2013;58(4):949-56.
5. Eliason JL, Wainess RM, Proctor MC, Dimick JB, Cowan JA Jr, Upchurch GR et al. A national and single institutional experience in the contemporary treatment of acute lower extremity ischemia. *Ann. Surg.* 2003;238(3):382-9.
6. Debut B, Smadja DM. Is COVID-19 a new hematologic disease? *Stem Cell Rev Rep.* 2021;17(1):4-8.
7. Connors JM, Levy JH. COVID-19 and its implications for thrombosis and anticoagulation. *Blood.* 2020;135(23):2033-40
8. Varga Z, Flammer AJ, Steiger P, Martina H, Rea A, Annelies SZ et al. Endothelial cell infection and endotheliitis in COVID-19. *Lancet.* 2020;395(10234):1417-8.
9. Klok FA, Kruip MJ, Van der Meer NJ, Arbous MS, Gommers DAMP, Kant KM et al. Incidence of thrombotic complications in critically ill ICU patients with COVID-19. *Thromb Res.* 2020;191:145-7.
10. Wang W, Zhao T, Geng K, Yuan G, Xu Y. Smoking and the Pathophysiology of Peripheral Artery Disease. *Front Cardiovasc Med.* 2021;8:704106.
11. Nixon ME, Pinto KG, Kostalas MS, Williams DJ, Taylor JV. Anticoagulation in the Surgical Management do Peripheral Arterial Embolic Disease. *J Vasc Endovasc Surg.* 2017;2:31.

Cite this article as: Jain A, Jadhav U, Kulkarni D, Aironi B, Potwar S, Patil P. Peripheral vascular emergencies-clinicopathological co-relation with outcome in a tertiary care centre. *Int Surg J* 2023;10:1947-50.