

Case Report

Hepato biliary pancreatic ascariasis: a rare case report

Siva Subramanian K. A.*, Chandrabose A. M. Jayaraman,
Selvaraj Thangasamy, Jeswanth Sathyanesan

Institute of Surgical Gastroenterology and Liver Transplantation, Government Stanley Medical College and Hospital, Chennai, Tamil Nadu, India

Received: 26 July 2023

Accepted: 19 August 2023

***Correspondence:**

Dr. Siva Subramanian K. A.,

E-mail: sivailakia@gmail.com

Copyright: © the author(s), publisher and licensee Medip Academy. This is an open-access article distributed under the terms of the Creative Commons Attribution Non-Commercial License, which permits unrestricted non-commercial use, distribution, and reproduction in any medium, provided the original work is properly cited.

ABSTRACT

Ascariasis is an infection caused by *Ascaris lumbricoides*. Most of these infections are in the gastrointestinal tract. Its extraluminal infestations involving the liver, pancreas and biliary tract are rare and its complications are usually morbid. This aspect of extra intestinal manifestation is termed hepato biliary and pancreatic ascariasis. We report a 65 years old female with history of recurrent abdominal pain and on evaluation found to have Ascarial infection with complications involving liver, biliary and pancreas. She was optimized and taken up for surgery and she recovered well. The ascarial infections are generally seen in the paediatric populations and most of them are intestinal. Here we presented an adult with extraintestinal Ascariasis who had complications of hepatobiliary and pancreatic system which was managed successfully and she was presented for its rarity.

Keywords: *Ascaris lumbricoides*, Hepato biliary pancreatic ascariasis

INTRODUCTION

Ascariasis is present worldwide with an estimated 1.4 billion populations affected. They are more common in the Indian, China, African and Latin American countries.¹ In the Indian subcontinent the endemic area is Kashmir, Tamil Nadu and Andhra Pradesh with some high prevalence rural areas with as estimate of 20%.² Ascariasis infections are more common in children and their symptoms are mostly intestinal with non-specific abdominal colicky pain and vomiting. Most of them present with easy fatigability due to anemia. The adult manifestations are less compared to children and especially the extraintestinal manifestations are extremely rare. The large case studies from Kashmir by Kuhoor et al showed an incidence of 0.45% (endemic areas).¹

Here we present a case of adult ascarial HBP infestation with all complications in the same patient which was managed surgically.

CASE REPORT

A 65 years old female born and lives in Chennai near the coastal region, came with history of recurrent upper abdominal pain with vomiting for 2 weeks. She is a homemaker by occupation. She gives history of right upper quadrant abdominal dull aching pain for three weeks, colicky in nature, lasting for 1-2 hours and starts 1-2 hours following feeds. History of radiation to back present. History of associated vomiting with occasional worms in the vomitus was seen. No history of fever, jaundice, hematemesis or melena. No history of loss of weight or appetite. No comorbid medical illness. Patient has undergone sterilisation 36 years back. On examination, ECOG is 1, conscious oriented febrile not icteric hydration is normal, no pedal oedema, no left supraclavicular lymphadenopathy. Cardiovascular system is normal except for tachycardia. Respiratory system is normal per abdominal examination showed soft abdomen with mild right hypochondrial and epigastric tenderness, no mass was felt, no organomegaly, sterilisation scar was healthy, bowel sounds decreased. Per rectal examination was

normal. She was in cholangitis with raised total counts, enzymes and alkaline phosphatase with features of pancreatitis Table 1. She underwent upper GI scopy which showed antral gastritis with normal duodenum first and second part. She was treated with intravenous piperacillin tazobactam 4.5 gm intravenous TDS along with pantoprazole and paracetamol. Since she could tolerate oral feeds she was advised oral soft diets. Ultra sonogram (Figure 1) was done as a baseline investigation which showed the following features. Common bile duct was dilated with intraluminal echogenic flat tubular structures, which was extending to bilobar intrahepatic biliary radicles with periportal oedema and gall bladder sludge. Pancreas body and tail appears bulky with prominent main pancreatic duct. An impression of biliary ascariasis with cholangitis and pancreatitis was given. Contrast enhanced computed tomography (CT) was taken which showed multiple left lobe dilated intrahepatic biliary radical with small cholangitic abscess restricted to left lateral lobe and long tubular structures in common bile duct with multiple calcified stones in lower CBD suspected round calculi or worms in the CBD (Figure 2). Main pancreatic duct was dilated and bulky distal body and tail of the pancreas with peripancreatic fat stranding. Impression of recurrent pyogenic cholangitis with biliary ascariasis with pancreatitis was made. MR with MRCP was taken which showed, multiple tubular filling defect in the CBD, common hepatic duct and intrahepatic radicles and main pancreatic duct was noted (Figure 3). CBD-13 mm and MPD-6.7 mm, linear calcified defect in the lower CBD suspected worm or linear calculi. Gall bladder is distended with sludge in the fundus. Fat stranding in the distal body and tail of the pancreas noted. Impression of biliary ascariasis with pancreatitis was made. She was optimised with intravenous antibiotics and anthelmintics. Her counts became normal in the following week as mentioned above. Since patient had multiple left ductal stones limited to lateral segment she was planned for surgical approach rather than endoscopy for worms and CBD stone retrieval. On the third week of admission she underwent elective laparotomy. Intraoperative findings were distended GB with dilated CBD 1.3 cm with multiple intraluminal dead worms and multiple pigmented calculi. Left lateral lobe cholangitic abscess with minimal atrophy (Figure 4).

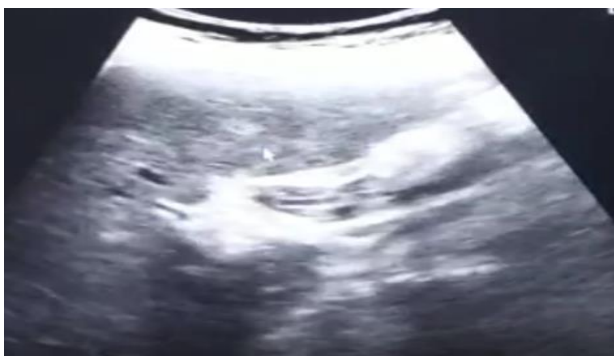

Figure 1: Ultrasonogram showing dilated CBD with intraluminal echogenic tubular structures, extending to bilobar biliary radicles.

Table 1: Hemogram renal and liver function test.

Parameters	At admission	After two weeks of admission
Total counts (cells/mm ³)	22300	13300
Haemoglobin (gms/dl)	11.3	11.1
Platelet counts (in lakhs)	3.2	1.86
Bilirubin total/direct (mgs/dl)	0.7/0.3	1.1/0.6
SGOT/SGPT/ALP (U/I)	157/90/374	29/36/212
Total protein/albumin (gms%)	6.1/2.4	5.5/2.6
Prothrombin time/INR	13/1.0	14/1.1
Blood urea/Sr. creatinine (mgs%)	21/0.9	
Serum amylase/lipase U/I	83/183	

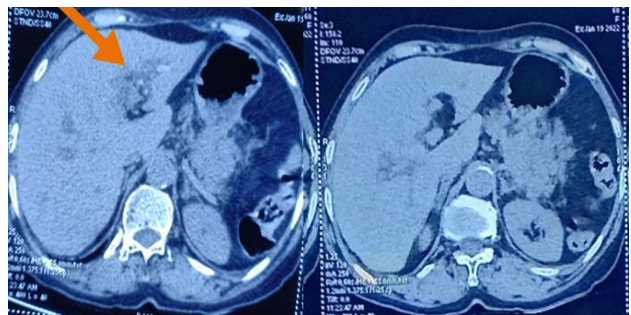


Figure 2: CT scan- multiple dilated left lobe intrahepatic biliary radicles with cholangitic abscess with edematous and bulky distal body and tail of pancreas.

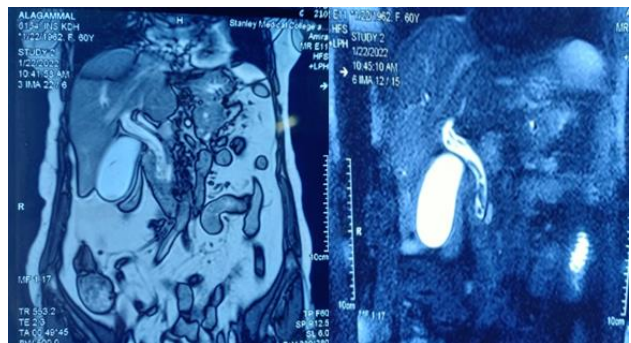


Figure 3: MRI/ MRCP- showing multiple tubular filling defects in the CBD and CHD extending to bilobar intrahepatic biliary radicles and inside the pancreatic duct. CBD-13 mm, MPD-6.7 mm, linear calcified defect in the lower CBD calculi/calcified worms.

Procedure done was open CBD exploration with choledochoduodenostomy with left lateral sectionectomy. Intraoperatively free passage of IFT and saline lavage confirmed the clearance of CBD. The total duration of surgery was 3½ hours and blood loss was around 100 ml. No intraoperative complication occurred. Post-operative

cut open specimen of the liver showed multiple dilated left lateral segment dilated ducts with pigmented calculi (Figure 5). In the post op period she was given oral liquids on day 3 and soft diets on day 4. She had superficial SSI was treated with culture based antibiotics and dressing. She was discharged on POD-11 after suture removal. She is on regular follow up as OPD basis and she is asymptomatic.

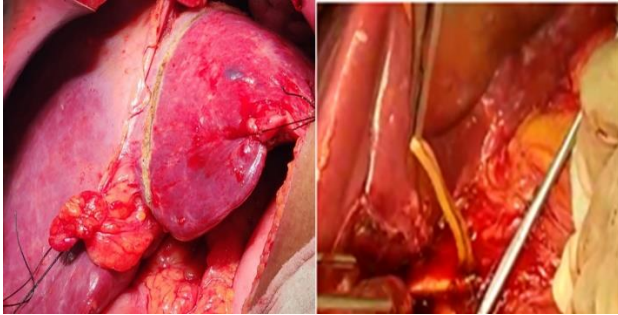


Figure 4: Intra operative picture- showing distended GB with dilated CBD with multiple dead worms and pigmented calculi. Left lateral lobe showing multiple cholangitic abscess with minimal atrophy.

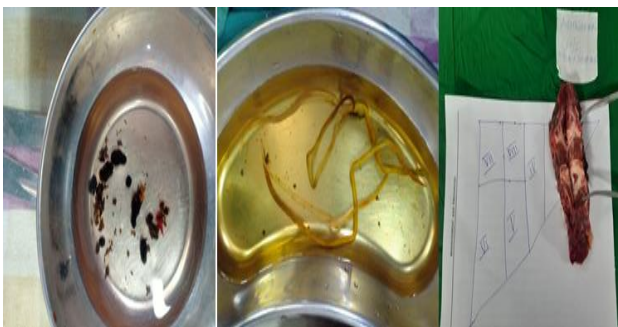

Figure 5: Postoperative specimen showing multiple pigmented calculi with dead worms and cut section of the left lateral lobe showing dilated intrahepatic biliary radicles with pigmented stones.

DISCUSSION

Nematode infection of the gastrointestinal tract is rare infections being common in endemic areas. As a whole in the world about 1.2 billion peoples are affected. India constitutes about 25% of the global case load.² In India Kashmir, Assam, Kolkata, Karnataka and Tamilnadu have the higher incidence. In Tamil Nadu it is common in the coastal regions. Nowadays due to improvement in sanitation and health education the incidence has dramatically decreased. Most of the ascariasis infections are intestinal and asymptomatic. They are more common in children and the symptoms are usually non-specific. The extra intestinal manifestations are usually rare. The adult worms usually reside in the upper jejunum. The extra intestinal manifestations are seen especially when the worm load is high with the worm entering the ampullary orifice producing biliary, pancreatic and hepatic

complications. Of the extra intestinal manifestations, the infections of the hepatobiliary and pancreas is uniquely termed as hepatobiliary and pancreatic ascariasis (HPA). In the endemic areas the incidence of HPA is 0.45%.¹ There are six different variants of HPA being described by Khuroo et al.¹ They are biliary colic, acute cholangitis, acute pancreatitis, acalculus cholecystitis, hepatic abscess and rarely hepatolithiasis. Most of the times the worms are not seen within the biliary system because of the active motility of the worm. They travel in and out of the ampullary orifice. Some of the worms when get trapped in to the biliary and pancreatic duct dies and forms the nidus for infection and calculi formation. Obstruction of the bile duct produces symptoms of biliary colic and acute cholecystitis when the worms block the cystic duct. Those which block the pancreatic duct produces pancreatitis. Those which invades the hepatic ducts induces the hepatolithiasis. The ova of the worm and the dead fragments forms the nidus for the stone formation. The ova of ascariasis have albuminated membrane that is highly cohesive which facilitates precipitation of calcium carbonate stones on the surface and the worm has high glucuronidase that deconjugates the bilirubin and forms pigment stones by precipitation with calcium.⁵ The initial management for the ascarial infection will be medical especially for mild symptoms and those with intestinal variants of infection. But those with extraintestinal the efficacy of the antihelminthics is less due to poor enterohepatic circulation and they are not effective within the biliary tract. Moreover, when the worms die of antihelminthics they get trapped within the biliary system producing complications. So for milder disease we usually wait for 1-2 weeks for the worm to return out of the biliary system with ultrasonogram screening. If the symptoms are severe then they need immediate extraction by ERCP especially with grasper and tripod forceps.⁶ If the complications are not manageable with medical and supportive they need surgical intervention especially in chronic cases where the left lobe of the liver is affected with intraductal stones and strictures and abscess. In our case she had cholangitis with left lobe cholangitic abscess with mild pancreatitis. She was given adequate hydration antihelminthic and medical management for pain. Due to the involvement of the left lobe with multiple intraductal stones and choangitic abscess with atrophy she was planned for surgical exploration. In view of continuing cholangitis she needed to be addressed up on two critical things. One the removal of the affected liver lobe which is remaining as the nidus of chronic infection. Secondly the need for an adequate biliary drainage which if not done will super add to the biliary stasis and turning on the vicious cycle of inflammation and eventually neoplasia evolution. Need for an access limb was taken into account for future endoscopic approaches. She underwent open CBD exploration with removal of all dead worms and left lateral sectionectomy with choledcho duodenostomy for future access. Our case had an uneventful post op period and she is on regular follow-up. She was advised 6 monthly antihelminthics along with all the family members and education regarding hygienic measures, usage of

pinhole latrines and personal hygienic measures are advised.

CONCLUSION

Hepatobiliary and pancreatic ascariasis is a rare entity with significant morbidity. Our case is being presented for its rarity with our patient having all complications which was managed successfully. It is to note that one of the cause of cholangitis, pancreatitis and hepatolithiasis could be an intestinal parasite and they could be easily diagnosed and treated with good recovery.

Funding: No funding sources

Conflict of interest: None declared

Ethical approval: Not required

REFERENCES

1. Khuroo MS, Rather AA, Khuroo NS, Khuroo MS. Hepatobiliary and pancreatic ascariasis. World J Gastroenterol. 2016;22(33):7507-17.
2. Salam N, Azam S. Prevalence and distribution of soil-transmitted helminth infections in India. BMC Public Health. 2017;17(1):201.
3. Khuroo MS, Rather AA, Khuroo NS, Khuroo MS. Hepatobiliary and pancreatic ascariasis. World J Gastroenterol. 2016;22(33):7507-17.
4. Pilankar KS, Amarpurkar AD, Joshi RM, Shetty TS, Khithani AS, Chemburkar VV. Hepatolithiasis with biliary ascariasis--a case report. BMC Gastroenterol. 2003;3:35.
5. Lee CF, Lee WC, Wu RC, Chen TC. Intrahepatic Duct Stones Harboring Ascariasis Ova: A Case Report. Medicine (Baltimore). 2016;95(12):e3139.
6. Leung JW, Yu AS. Hepatolithiasis and biliary parasites. Baillieres Clin Gastroenterol. 1997;11(4):681-706.
7. Khuroo MS, Khuroo NS, Khuroo MS. Biliary ascariasis in the aetiology of recurrent pyogenic cholangitis in an endemic area. Int J Hepatobil Pancreat Dis. 2015;5:22-9.
8. Phisalprapa P, Prachayakul V. Ascariasis as an unexpected cause of acute pancreatitis with cholangitis: a rare case report from urban area. JOP. 2013;14(1):88-91.

Cite this article as: Subramanian SKA, Jayaraman CAM, Thangasamy S, Sathyanesan J. Hepato biliary pancreatic ascariasis: a rare case report. Int Surg J 2023;10:1537-40.