

## Case Report

# A case report of perforated appendicitis with pyoperitoneum in a tertiary care center

Yashfeen M.\*, Manivannan R.

Department of General Surgery, Government Stanley Medical College, Chennai, Tamil Nadu, India

**Received:** 08 June 2023

**Accepted:** 06 July 2023

**\*Correspondence:**

Dr. Yashfeen M.,

E-mail: [yashfeen0308@gmail.com](mailto:yashfeen0308@gmail.com)

**Copyright:** © the author(s), publisher and licensee Medip Academy. This is an open-access article distributed under the terms of the Creative Commons Attribution Non-Commercial License, which permits unrestricted non-commercial use, distribution, and reproduction in any medium, provided the original work is properly cited.

### ABSTRACT

Acute appendicitis remains one of the most frequent reasons for emergency hospital admissions and the most common cause of an 'acute abdomen' in young adults. The risk of appendicitis is 8.6% for men and 6.7% for women throughout a lifetime, with the frequency peaking in the second decade of life. In 19% of acute appendicitis cases, there is perforation, and it has a bimodal distribution. Appendiceal gangrene and perforation appear to be caused by the appendiceal lumen being blocked. Gangrenous appendicitis and free bacterial contamination of the peritoneal cavity result from ischaemic necrosis of the appendix wall. Extreme ages, diabetes mellitus, immunosuppressive diseases, and obstruction of the appendix lumen are risk factors for appendix perforation. Advances in radiographic imaging have increased diagnostic accuracy, although the diagnosis of acute appendicitis remains primarily clinical. Ultrasound, computed tomography (CT) scans, and magnetic resonance imaging (MRI) scans are the imaging modalities presently in use. Early appendectomy continues to be the best option and the least contentious treatment for acute appendicitis. The accepted standard of care for perforated appendicitis includes both open and laparoscopic procedures. Antibiotic prophylaxis responds effectively to complicated appendicitis.

**Keywords:** Acute appendicitis, Perforated appendicitis, Gangrenous appendicitis, Peritonitis, Pyoperitoneum, Appendectomy

## INTRODUCTION

With an annual incidence rate of roughly 100 per 100,000 people, appendicitis is one of the most frequent surgical emergencies.<sup>1</sup> Complicated appendicitis is a perforated appendix that commonly has an abscess or phlegmon. A luminal obstruction leads to appendicitis. Continuous obstruction causes full-thickness ischemia, which results in perforation. A patient may present with diffuse peritonitis. Abdominal ultrasonography is a valuable diagnostic tool for acute abdominal pain. A computed tomography (CT) scan, which is highly effective and accurate, is used to diagnose perforated appendicitis with a localized abscess. To treat complicated appendicitis, the surgical approach is primarily an open appendectomy via a lower midline incision.

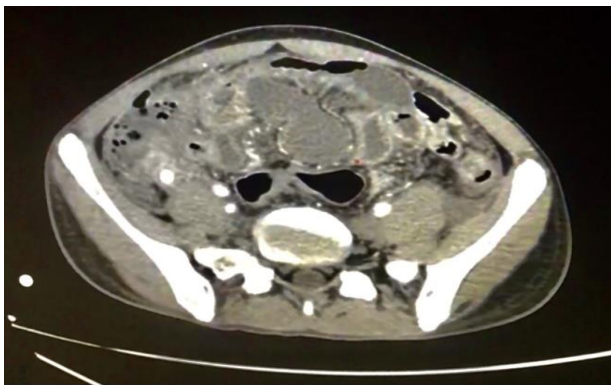
## CASE REPORT

A 20-year-old male patient presented to the emergency department with complaints of severe abdominal pain that had been present for the past seven days. He also showed up with a two-day history of non-projectile, non-bilious, and non-blood-stained vomiting and fever associated with chills and rigors. On examination, she was febrile, tachypneic, and tachycardic. Per abdomen examination, revealed diffuse abdominal tenderness over the right iliac fossa, suprapubic region, and the left iliac fossa with generalized guarding. Blood investigations revealed leukocytosis. He was adequately hydrated and given broad-spectrum antibiotics immediately.

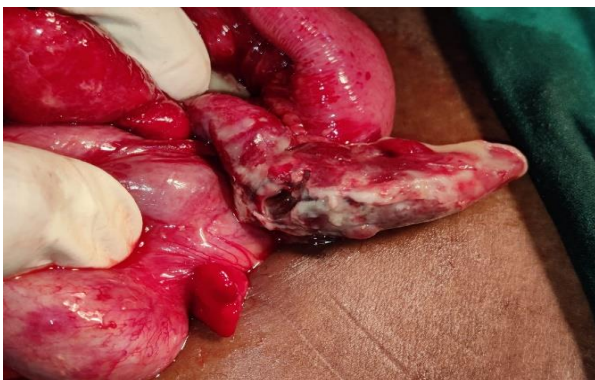Abdominal ultrasonography revealed an inflamed appendix measuring 8 mm in diameter with surrounding

fluid and an appendicolith. Since the patient had disproportionately unusual findings with abdominal ultrasonography, he then underwent contrast-enhanced computed tomography (CECT) of the abdomen and pelvis, which revealed an appendix measuring 14 mm at the base with an appendicolith (6.4×6.2 mm), a fluid-filled wall defect noted in the body of the appendix, and an adjacent collection measuring 3.7×1.6 cm noted in the right iliac fossa. Multiple loculated collections, the largest measuring 5×2.6 cm, intercommunicating with each other, are noted in the mesentery. A few subcentimetric mesenteric, pericolic, ileocolic, and para-aortic lymph nodes were noted.

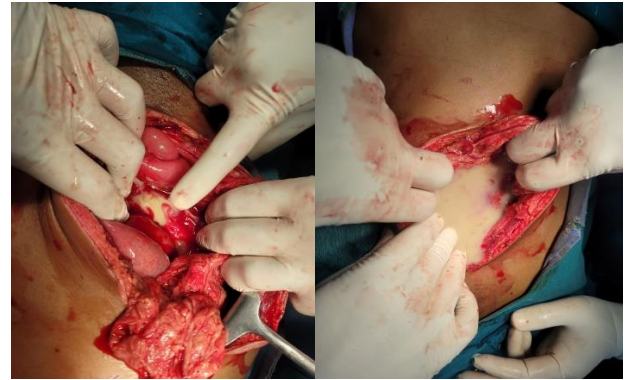
We then proceeded with an emergency laparotomy. Intraoperative findings were, the appendix appeared inflamed and gangrenous with an appendicular abscess, 300 ml of pyoperitoneum, and a 0.3×0.5 cm perforation in the body of the appendix with the healthy base. There were multiple loculated collections seen at inter-bowel and inter-mesentery levels. An appendectomy was performed, along with peritoneal lavage. Peritoneal fluid was obtained for organism culture and antimicrobial sensitivity testing.



**Figure 1: Contrast-enhanced computed tomography abdomen reveals acute appendicitis with perforation and multiple loculated collections in the mesentery intercommunicating with each other.**



**Figure 2: Intraoperative picture showing appendicular perforation.**



**Figure 3: Intraoperative picture depicting pyoperitoneum.**

## DISCUSSION

### *Etiology*

Appendicitis-related infections should be viewed as polymicrobial, and antibiotic treatment should include medications that address the presence of both aerobes and anaerobes. Common pathogens include *Enterococcus*, *Pseudomonas aeruginosa*, *Escherichia coli*, *Klebsiella pneumoniae*, and *Bacteroides fragilis*. There seems to be increased bacterial tissue invasion in patients with gangrene or perforated appendicitis.<sup>2</sup>

### *Pathogenesis*

The following are the salient features in pathogenesis: closed-loop obstruction (fecolith), swelling of lymphoid tissue on the mucosa and submucosa, secretion of intraluminal fluid, increase in luminal pressure, ischemia of the mucosa, bacterial proliferation and translocation, and necrosis and perforation.<sup>3</sup>

### *Diagnosis*

The most accurate sign of acute appendicitis is the presence of the classic visceral-somal pain sequence. Murphy's triad of symptoms for acute appendicitis includes abdominal pain, followed by vomiting, and then fever.

Palpation of the left iliac fossa induces pain in the right iliac fossa (Rovsing sign).

At McBurney's point, tenderness and rebound tenderness (the Blumberg sign) are present.

The presence of guarding and rigidity in the right iliac fossa.

All of these signs may aid in the diagnosis of acute appendicitis.

Perforation is strongly suggested by diffuse peritonitis or abdominal wall rigidity caused by involuntary spasm of the overlying abdominal wall musculature. The scoring system used most frequently to aid in diagnosis is the Alvarado score. A score of seven or higher is highly prognostic of acute appendicitis.<sup>4</sup> The presence of gangrene or perforation is suggested by a very high WBC count (20000/mm<sup>3</sup>) in severe appendicitis. The C-reactive protein level is elevated in any inflammatory condition, such as appendicitis. Abdominal ultrasonography is the preferred initial investigation. When a patient's diagnosis is uncertain, contrast-enhanced computed tomography (CECT) is of special value.

### Management

Patients with indications of sepsis and generalized peritonitis should be taken to the operating room as soon as possible, with concurrent resuscitation. For appendectomy, irrigation, and drainage of the peritoneal cavity, an emergency laparotomy or laparoscopy is required. A diagnostic laparoscopic or exploratory laparotomy through a midline incision is carried out, depending on the patient's clinical stability. CT- or US-guided drainage can frequently be carried out percutaneously or transrectally if imaging examinations reveal an abscess cavity. After drainage, the patient is carefully monitored, put on bowel rest, and given IV antibiotics and fluids.<sup>5</sup>

### CONCLUSION

Significant improvements in treating patients with appendiceal perforation and its complications have been made possible by developing a broad spectrum of antibiotics, interventional radiologic techniques, and better surgical critical care strategies.

*Funding: No funding sources*

*Conflict of interest: None declared*

*Ethical approval: Not required*

### REFERENCES

1. Liang MK, Andersson RE, Jaffe BM, Berger DH. The Appendix. Brunickard FC, Andersen DK, Billiar TR, Dunn DL, Hunter JG, editors. Schwartz's principles of surgery. Tenth edition. New York: McGraw-Hill Education. 2014;1241-62.
2. Richmond B. The Appendix. Townsend CM, editor. Sabiston textbook of surgery: the biological basis of modern surgical practice. 21st edition. St. Louis, Missouri: Elsevier. 2022;2147:1301-19.
3. The Appendix. Shenoy KR, Shenoy A (Nileshwar), editors. Manipal manual of surgery. Fourth edition. New Delhi: CBS Publishers & Distributors. 2014;824-40.
4. Mulsow J. The vermiform appendix. Williams NS, O'Connell PR, McCaskie AW, editors. Bailey & Love's short practice of surgery. 27th edition. Boca Raton, FL: CRC Press. 2017;1299-317.
5. Madenci AL, Peranteau WH, Smink DS. Appendix and Small Bowel Diverticula. Maingot R. Maingot's abdominal operations. Thirteenth edition. Zinner M, Ashley SW, Hines OJ, editors. New York: McGraw-Hill Education. 2019.

**Cite this article as:** Yashfeen M, Manivannan R. A case report of perforated appendicitis with pyoperitoneum in a tertiary care center. *Int Surg J* 2023;10:1422-4.