

Case Series

Zinner's syndrome: to observe or to operate? a triplet of cases with varying clinical presentation

Anshuman Singh, Bommireddy V. Reddy, Anupam Choudhary, Surag K. R., Arun Chawla*

Department of Urology and Renal Transplant, Kasturba Medical College, Manipal, Manipal Academy of Higher Education, Manipal, KA, India

Received: 01 June 2023

Revised: 13 June 2023

Accepted: 15 June 2023

*Correspondence:

Dr. Arun Chawla,

E-mail: urologyarun@yahoo.com

Copyright: © the author(s), publisher and licensee Medip Academy. This is an open-access article distributed under the terms of the Creative Commons Attribution Non-Commercial License, which permits unrestricted non-commercial use, distribution, and reproduction in any medium, provided the original work is properly cited.

ABSTRACT

Zinner's syndrome is a rare condition that can be challenging to diagnose and manage. Limited knowledge about its natural history and optimal treatment further complicates matters. To shed more light on this condition, we present a case series of three patients with Zinner's syndrome, highlighting their clinical presentations, diagnostic workup, and treatment options. Our first patient was a 16-year-old male with left epididymo-orchitis and left renal agenesis. The second patient was a 25-year-old male with left epididymo-orchitis, left seminal vesicle cyst, and left renal agenesis. The third patient was a 65-year-old male with left seminal vesicle cysts and aplastic ectopic renal tissue with ectopic ureteral insertion into the seminal vesicle cyst causing acute urinary retention. The two patients who presented with epididymo-orchitis were managed conservatively while the one presenting with acute urinary retention required surgical exploration and excision. It is noted that diagnosis of Zinner's syndrome requires a high index of suspicion, and radiological imaging is crucial for confirmation. Surgical intervention is often necessary to treat symptomatic compression, and fertility counselling is necessary due to the potential for impaired semen quality. Close monitoring is needed due to the risk of renal impairment in the future.

Keywords: Zinner's syndrome, Unilateral renal agenesis, Seminal vesicle cyst, Ectopic ureteric insertion, Infertility

INTRODUCTION

Zinner's syndrome is a rare congenital anomaly that affects the development of the male reproductive system. It is characterized by the presence of a seminal vesicle cyst in association with ipsilateral renal agenesis or dysplasia. The syndrome was first described in 1914 by a German physician named Hans Zinner and has since been reported in fewer than 200 cases in the medical literature.^{1,2}

The rarity of Zinner's syndrome is significant because it can be difficult to diagnose and manage, and there is limited knowledge about its natural history and optimal treatment. Patients with this syndrome may present with a range of symptoms, including lower abdominal pain,

dysuria, hematuria, epididymo-orchitis or infertility.²⁻⁶ In rare scenarios, this condition can mimic a varicocele and present as a scrotal swelling.⁷ These myriads of clinical presentations associated with Zinner's syndrome highlight the heterogeneity of this rare condition. The nonspecific symptoms of the condition can make it difficult to recognize and diagnose, particularly in patients with milder forms of the syndrome.

CASE SERIES

In this report, we present a series of three cases of Zinner's syndrome with contrasting clinical symptoms. The diagnosis of Zinner's syndrome in these cases was made following radiological imaging, as the clinical presentation alone did not provide a definitive diagnosis.

The purpose of this case series of Zinner's syndrome is to provide further insight into the clinical presentation, diagnostic workup, and treatment options for this rare syndrome. By pooling data from multiple cases, researchers can identify trends and patterns that may not be apparent in individual cases.

Case 1

A 16-year-old male presented with acute left scrotal pain and fever lasting for two days. Physical examination revealed bilateral testes in a normal position, but the left testis and epididymis were tender. A non-tender left supraprostatic mass was noted on per rectal examination, while the rest of the examination was unremarkable. Laboratory tests showed an elevated total leukocyte count of 12000/mm³. Urine routine was normal, and urine culture was sterile. Uroflowmetry recorded normal results. A scrotal Doppler ultrasound diagnosed left-sided epididymo-orchitis. An abdominal ultrasound revealed an absent left kidney.

Semen analysis demonstrated low ejaculate volume, acidic pH, and oligoasthenoteratozoospermia (Table 1). Further evaluation was carried out with MRI due to the clinical picture of left epididymo-orchitis, left renal agenesis, and left supra-prostatic enlargement. The MRI revealed an ectopic insertion of the prominent left rudimentary ureter into the ipsilateral seminal vesicle cysts, which were moderately hyperintense on T2W imaging and significantly hyperintense on T1W imaging (Figure 1 and 2). Additionally, a prominent left vas deferens was documented, likely due to an ejaculatory duct obstruction. Cystourethroscopy revealed a normal urethra and an absent left hemitrigone (Figure 3). The diagnosis of Zinner's syndrome was made based on the patient's clinical presentation of left epididymo-orchitis, left renal agenesis, and left supra-prostatic enlargement, in addition to radiological findings.

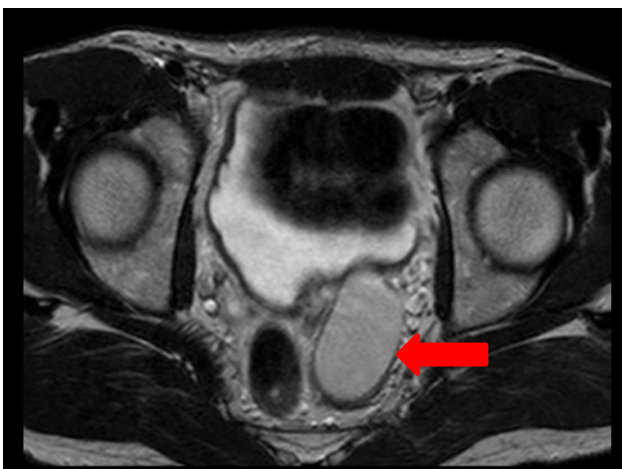


Figure 1: Axial section of MRI pelvis of the patient showing cystic dilatation of left seminal vesicle with moderate hyperintensity on T2W imaging (marked in red arrow).

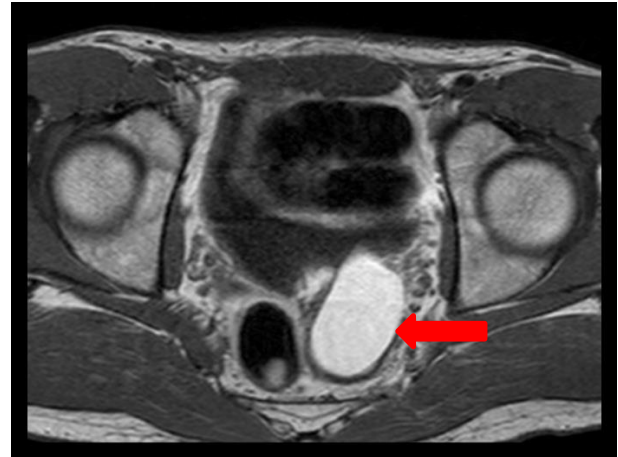

Figure 2: Axial section of MRI pelvis of the patient showing cystic dilatation of left seminal vesicle with marked hyperintensity on T1W imaging (marked in red arrow).

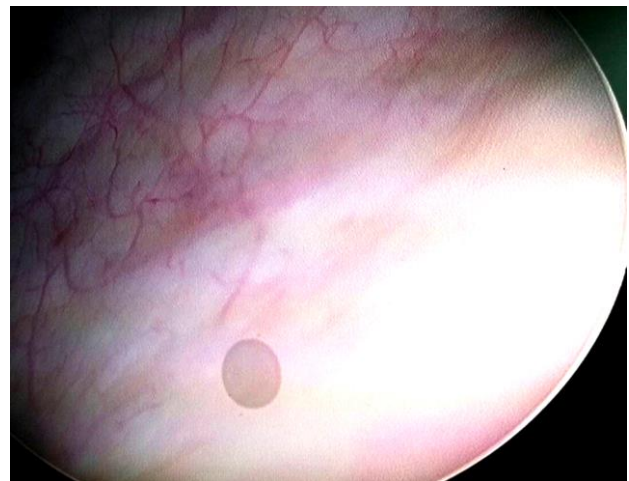

Figure 3: Cystoscopy image of the patient showing absence of left hemitrigone.

Table 1: Semen analysis of the patient showing low ejaculate volume, decreased pH and oligoasthenozoospermia.

Parameter	Patient	Normal values
Volume (ml)	1.0	≥ 1.5
pH	6.9	≥7.2
Sperm count (sperms/ml)	09	≥15 million
Total sperms (sperms/ejaculate)	09	≥39 million
Motility (%)	12	≥40
Progressive motility (%)	04	≥32
Normal forms (%)	01	≥4

He was treated with broad-spectrum antibiotics and supportive measures. The patient improved during hospitalization and was discharged with instructions for regular follow-up. The patient was counselled on the

need for surgical intervention in circumstances of recurring bothersome symptoms, as well as the potential for fertility issues in the future.

Case 2

A 25-year-old unmarried male presented with a 3-week history of dysuria and left scrotal pain. Physical examination revealed a normally placed bilateral testis with a 3×2 cm cyst in the left epididymis. A non-tender, cystic mass of 3×2 cm size was palpated on the left side above the prostate during digital rectal examination. Blood investigations were within normal limits. Urine routine and culture were sterile. Scrotal Doppler revealed left-sided epididymorchitis. Abdominal sonography revealed an absent left kidney, a normal right kidney, and a 3×2 cm cystic mass located posterolateral to the left lobe of the prostate, which was suspicious for a left seminal vesicle cyst. The post-void residual urine volume was 20 ml. Semen analysis revealed oligoastheno-teratozoospermia (Table 2). MRI of abdomen and pelvis showed a dilated left seminal vesicle cyst, an absent left kidney with an ectopic insertion of the prominent left rudimentary ureter into the cystic dilated tortuous left seminal vesicle, and a dilated left vas deferens due to ejaculatory duct obstruction (Figure 4 and 5). Cystoscopy revealed a normal urethra with a periprostatic bulge on the left side, an absent left hemitrigone, and left ureteric orifice. Conservative management was done with broad-spectrum antibiotics along with symptomatic treatment for pain, which resulted in a favourable response. The patient was discharged on the 5th day with counselling regarding the need for surgical intervention in case of recurring bothersome symptoms and potential fertility issues in the future.

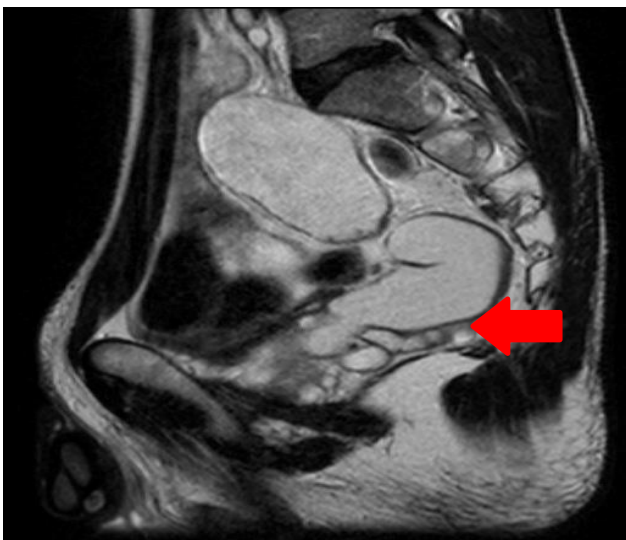


Figure 4: Sagittal section of MRI abdomen and pelvis of the patient showing cystic and tortuous dilatation of the left seminal vesicle with mild to moderate hyperintensity on T2W imaging (marked in red arrow).

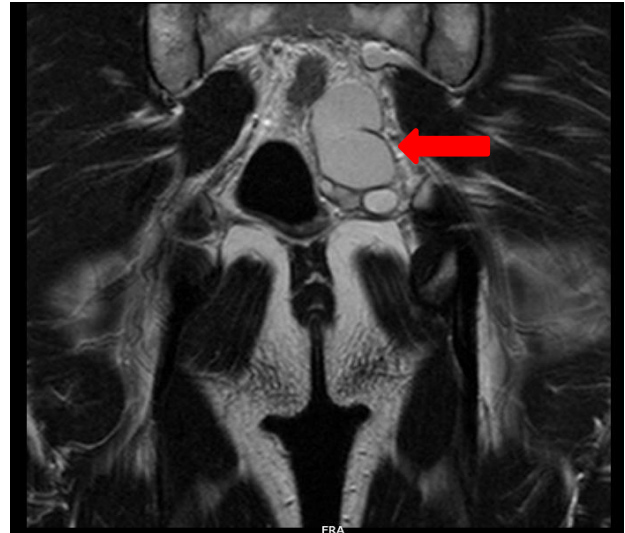


Figure 5: Coronal section of MRI abdomen and pelvis of the patient showing cystic and tortuous dilatation of the left seminal vesicle with mild to moderate hyperintensity on T2W imaging (marked in red arrow).

Table 2: Semen analysis of the patient showing normal ejaculate volume and pH with oligoastheno-teratozoospermia.

Parameters	Patient	Normal values
Volume (ml)	1.5	≥ 1.5
pH	7.4	≥7.2
Sperm count (sperms/ml)	45	≥15 million
Total sperms (sperms/ejaculate)	68	≥39 million
Motility (%)	18	≥40
Progressive motility (%)	09	≥32
Normal forms (%)	01	≥4

Case 3

A 65-year-old male, presented with right flank pain, nausea, and multiple febrile episodes. He had a history of lower urinary tract symptoms, and on examination, a large non-tender cystic mass was palpated on the left superolateral aspect of the prostate. Abdominal ultrasound and CT scan showed a large hypodense abdominopelvic cystic lesion on the left side causing mass effect over the posterior wall of the bladder, distal ureter, and prostatic urethra (Figure 6 and 7). Additionally, a linear soft tissue structure was noted in the left iliac region capping a tubular structure arising anteriorly to it, suggestive of aplastic ectopic renal tissue with ectopic ureteral insertion into the seminal vesicle cyst. Cystoscopy showed an inflamed prostatic urethra and a moderately trabeculated bladder with multiple sacculations and an absent left hemitrigone (Figure 8). Retrograde pyelography followed by ureteroscopy showed narrowing of distal ureteric calibre due to

external compression and upstream dilatation of the mid and proximal ureter. The patient underwent surgical exploration through a midline vertical abdominal incision followed by excision of seminal vesicle cyst and left ureter to alleviate symptomatic compression of bladder and bladder outlet obstruction (Figures 9-11). Follow-up assessments at one month and three months showed remarkable improvement in symptoms after the cyst excision.

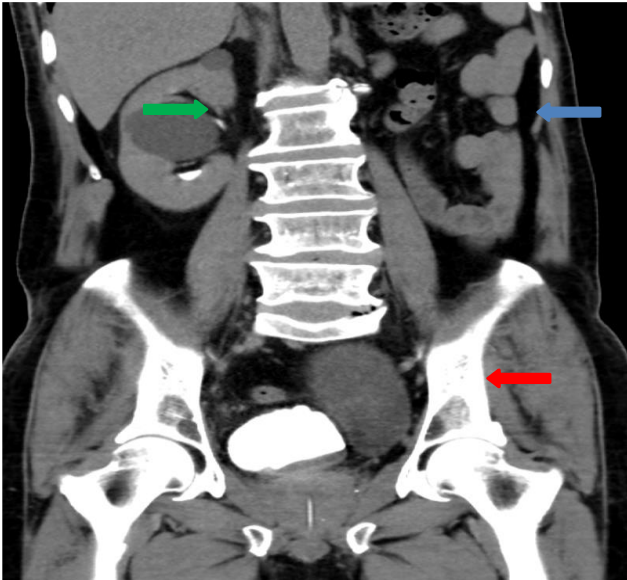

Figure 6: Coronal section of CT urogram of the patient showing cystic dilatation of the left seminal vesicle having well defined interface with the urinary bladder (marked in red arrow). Also note the absence of left kidney (marked in blue arrow) and a simple cyst in the interpolar region of right kidney (marked in green arrow).

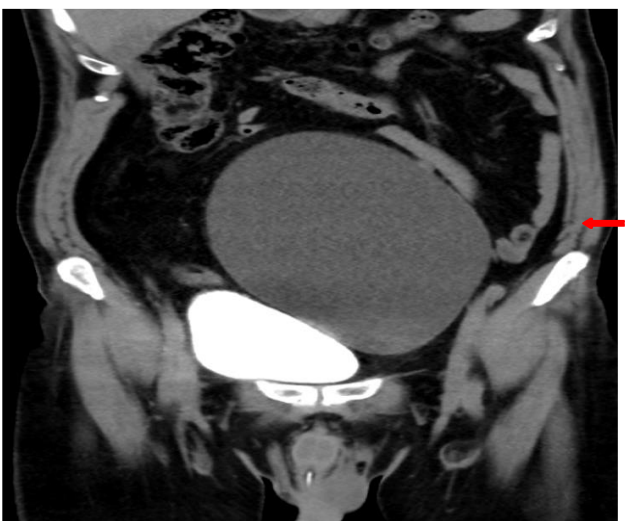

Figure 7: Coronal section of CT urogram of the patient showing cystic dilatation of the left seminal vesicle having well defined interface with the urinary bladder (marked in red arrow).

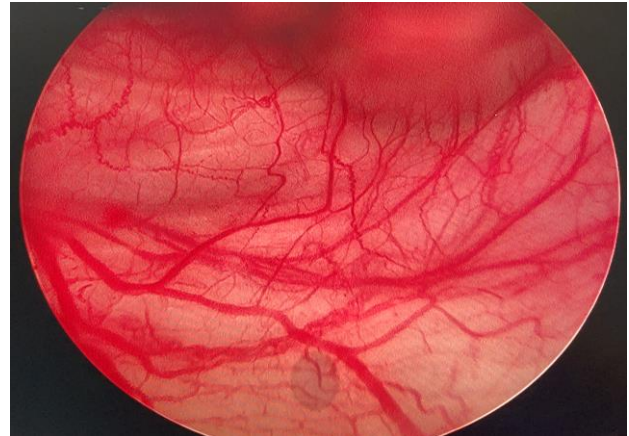


Figure 8: Cystoscopy image of the patient showing absence of left hemitrigone.

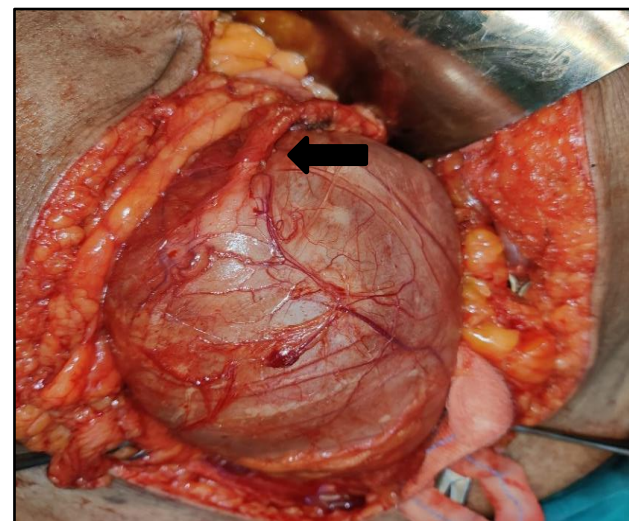


Figure 9: Intraoperative image showing ectopic insertion of left ureter (marked with arrow) into the left seminal vesicle cyst.

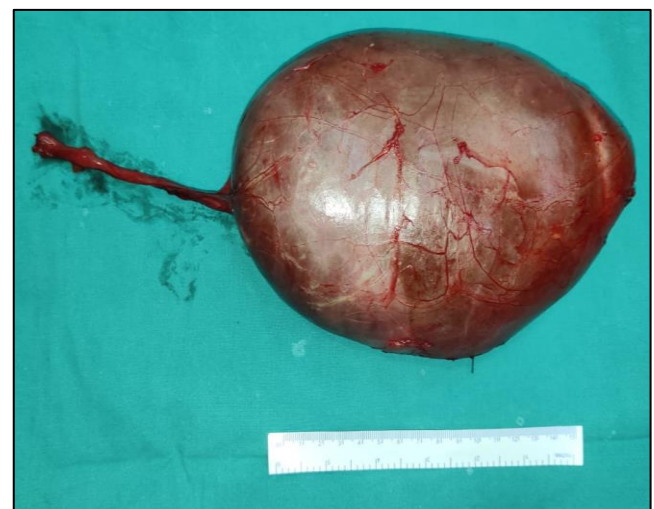

Figure 10: Excised specimen showing the seminal vesicle cyst with ectopically inserting left ureter.

DISCUSSION

Zinner's syndrome is a rare congenital anomaly that occurs due to incomplete development of the Wolffian duct during embryonic life. As a result, patients with this syndrome present with a range of urological abnormalities that can lead to a variety of clinical symptoms. While the classic triad of seminal vesicle cyst, ipsilateral renal agenesis, and ejaculatory duct obstruction is often seen, as highlighted by the first and second cases presented, patients may present with a range of symptoms, including scrotal pain, dysuria, flank pain, and fever. Therefore, the heterogeneity of presentation of Zinner's syndrome requires a high index of suspicion, especially when a patient presents with unexplained urological symptoms.

In the first case, a 16-year-old male presented with acute left scrotal pain and fever, which is a common presenting symptom of epididymo-orchitis. However, further evaluation with radiological imaging revealed the absence of the left kidney, left supra-prostatic enlargement, and ectopic insertion of the prominent left rudimentary ureter into the ipsilateral seminal vesicle cysts. The presence of these findings confirmed the diagnosis of Zinner's syndrome. In the second case, a 25-year-old male presented with dysuria and left scrotal pain. Physical examination revealed a cystic mass in the left epididymis and a non-tender, cystic mass above the prostate during digital rectal examination. Radiological imaging confirmed the absence of the left kidney, left seminal vesicle cyst, and left vas deferens due to ejaculatory duct obstruction. Again, this constellation of findings confirmed the diagnosis of Zinner's syndrome.

It is important to note that the definitive diagnosis of Zinner's syndrome requires confirmation by radiological imaging. In both cases, MRI was the imaging modality of choice, as it provides detailed information about the urogenital anatomy, which is essential for confirming the diagnosis. In the third case, CT scan was the imaging modality of choice, when the initial diagnosis is in doubt, as it provides good visualization of cystic lesions and their relationship with adjacent structures and urologists are more familiar to reading CT images than MRI. Overall, the use of imaging modalities such as MRI or CT scan is crucial for detecting the presence of seminal vesicle cysts, ureteral anomalies, and ejaculatory duct obstruction, which are the diagnostic features of Zinner's syndrome.

The treatment of Zinner's syndrome depends on the clinical presentation and severity of symptoms. Conservative management has been tried, using antibiotics, anti-inflammatory drugs and alpha blockers, and can be successful in managing acute symptoms.^{3,8} Aspiration of the seminal vesicle cyst can be a minimally invasive and effective method for managing the obstruction and improving urinary symptoms.⁵ Laparoscopic or open excision of the cyst and drainage of

the infected fluid are common surgical options.^{9,10} Surgeons experienced in laparoscopic approach claim that it provides good surgical field and vision and is feasible for definitive treatment.^{11,12} Partial or complete removal of the affected organ may also be necessary in some cases.^{9,10} The choice of surgical intervention depends on the extent of the compression and the severity of the symptoms.^{10,12} In all three cases, the patients were initially treated with broad-spectrum antibiotics and supportive measures, which resulted in a favourable response in the first two cases. However, in the third case, surgical excision of the cyst was required to alleviate symptomatic compression of bladder outlet and distal ureter.

Zinner's syndrome can have significant clinical implications, especially regarding fertility.^{2,4} The obstruction of the ejaculatory ducts can lead to impaired semen quality and fertility.^{2,4} Semen analysis in both cases demonstrated teratospermia and oligoasthenoteratozoospermia, respectively, highlighting the need for counselling on fertility issues in patients with Zinner's syndrome. In addition, the absence of one kidney in these patients may predispose them to renal impairment and requires close monitoring on follow up.

CONCLUSION

Zinner's syndrome is a rare but serious congenital anomaly that requires prompt diagnosis and management. Taking into account its rarity, it requires a high index of suspicion for diagnosis. Radiological imaging is crucial for confirmation of diagnosis, and surgical intervention is often necessary to treat symptomatic compression. Counselling on fertility issues is necessary due to the potential for impaired semen quality. Close monitoring is also needed due to the risk of renal impairment in future. Early recognition and appropriate management are essential to prevent long-term complications, including infertility and renal dysfunction.

Funding: No funding sources

Conflict of interest: None declared

Ethical approval: Not required

REFERENCES

1. Zinner: Ein Fall von intravesikaler Samenblasenzyste. Available at: https://scholar.google.com/scholar_lookup?journal=Wein+Med+Wochenschr&title=Ein+fall+von+intravesikaler+samenblasenzyste&author=A+Zinner&volume=64&publication_year=1914&pages=605-609&. Accessed on 12 May, 2023.
2. Van den Ouden D, Blom JHM, Bangma C, De Spiegeleer AHV. Diagnosis and management of seminal vesicle cysts associated with ipsilateral renal agenesis: a pooled analysis of 52 cases. *Eur Urol.* 1998;33(5):433-40.

3. Ostrowska M, Grzešk M, Kaczyński S, Skwara D, Kulik K, Kowalski F et al. Zinner Syndrome-A Rare Cause of Recurrent Epididymitis and Infertility. *Clin Pract.* 2021;11(4):942.
4. Pereira BJ, Sousa L, Azinhais P, Conceição P, Borges R, Leão R et al. Zinner's syndrome: an up-to-date review of the literature based on a clinical case. *Andrologia.* 2009;41(5):322-30.
5. Kori R, Bains L, Lal P, Gupta S. Zinner syndrome mimicking bladder outlet obstruction managed with aspiration. *Urol Ann.* 2019;11(4):449.
6. Soliman AA, Alshukami AA, AlZuber WH. Zinner's syndrome, radiological diagnosis for a rare syndrome with non-specific clinical presentation: case report. *Egypt J Radiol Nuclear Med.* 2020;51(1).
7. Pavan N, Bucci S, Mazzon G, Bertolotto M, Trombetta C, Liguori G. It's not always varicocele: A strange case of Zinner syndrome. *Can Urol Assoc J.* 2015;9(7-8):E535-8.
8. Militaru V, Mihaly ZA, Ilea C, Coman M, Stanciu M, Crisan N et al. Zinner syndrome-case report. *Med Pharm Rep.* 2021;94(1):S47-50.
9. Slaoui A, Regragui S, Lasri A, Karmouni T, El Khader K, Koutani A et al. Zinner's syndrome: Report of two cases and review of the literature. *Basic Clin Androl.* 2016;26(1):1-5.
10. Farooqui A, AlDhahir L, Mahfooz A Bin. Massive seminal vesicle cyst with ipsilateral renal agenesis – Zinner syndrome in a Saudi patient. *Urol Ann.* 2018;10(3):333.
11. Jarzemski P, Listopadzki S, Kowalski M. Zinner syndrome: a case report and literature review. *Journal of the Society of Laparoendoscopic Surgeons.* 2014;18(2):367-71.
12. Maehana T, Fukuta F, Kobayashi K, Hirobe M, Tanaka T, Masumori N. Laparoscopic Surgery for Seminal Vesicle Cysts and Ureterocele with Urination Disorder: A Case Report of Zinner Syndrome. *J Endourol Case Rep.* 2018;4(1):35.

Cite this article as: Singh A, Reddy BV, Choudhary A, Surag KR, Chawla A. Zinner's syndrome: to observe or to operate? a triplet of cases with varying clinical presentation. *Int Surg J* 2023;10:1207-12.