

Case Series

A novel clinico-surgical algorithm for management of maxillofacial gunshot wound injuries

Edlyn Rodrigues*, Saurabh Kamat, Shreyas Naik, Neha Chodankar,
Vikas Dhupar, Francis Akkara

Department of Oral and Maxillofacial, Surgery, Goa Dental College and Hospital, Bambolim, Goa, India

Received: 21 May 2023

Accepted: 19 June 2023

*Correspondence:

Dr. Edlyn Rodrigues,
E-mail: edlynr@gmail.com

Copyright: © the author(s), publisher and licensee Medip Academy. This is an open-access article distributed under the terms of the Creative Commons Attribution Non-Commercial License, which permits unrestricted non-commercial use, distribution, and reproduction in any medium, provided the original work is properly cited.

ABSTRACT

Ballistic injuries commonly called gunshot wound injuries (GSWI) can be catastrophic in the head and neck regions. The degree of destruction correlates with the range and type of the weapon and projectile speed. The intricacies of the facial anatomy makes the reconstructive phase a challenge. The dilemma lies in decision-making of immediate (single stage) or delayed (multiple stage) reconstruction of hard and soft tissues. In this article we highlight a novel clinico-surgical algorithm for managing gunshot wound injuries.

Keywords: Gunshot wound, Ballistic, Projectile, Treatment protocol, Reconstruction

INTRODUCTION

Management of gunshot wound injuries (GSWI) in the maxillofacial region can be challenging due to the intricate anatomy and high functional and cosmetic needs associated with the face. GSWI acutely affect the quality of life of patients. The etiology of these GSWI could be military, assault, accidental or suicidal attempts. The type and adjacency of the weapon, along with the speed and path of the projectile, play an important role in determining the extent of bone fragmentation and soft tissue damage.^{1,2}

Ballistic injuries can be classified low velocity <1200 feet/s, medium 1200-2000 feet/s and high velocity >2000 feet/s. The degree of tissue damage from a gunshot wound is directly proportional to the mass of the projectile and the square of its velocity.³ Low-velocity injuries are less damaging and are treated similarly to blunt facial trauma, with immediate reconstruction protocol.⁴ High velocity weapons cause fulguration and cavitation due to massive soft and hard tissue loss. These are particularly challenging and have a complication rate

of 39%.⁵ However close-range gunshot wounds have a reported infection rate of 100%.⁶

GSWI mandate thorough clinical and radiographic evaluation due to its proximity to vital structures. Over the past few years, treatment of these injuries involved initial wound debridement and soft tissue closure without replacement of lost bone.^{1,7} This led to facial deformation and loss of functional outcomes. The more severe high velocity injury with massive hard and soft tissue loss were allowed to heal by secondary intention and subsequently secondary bony reconstructive surgery was performed. However, this resulted in severe scar contracture and suboptimal cosmetic and functional outcomes as well.⁷⁻⁹ Therefore the constant dilemma of immediate versus delayed, single stage versus multi-staged procedures, primary closure or secondary closure needed to be assessed.

CASE SERIES

We studied 7 patients who had succumbed GSWI to face. Four were treated with immediate single-stage approach while the other three were subjected to multiple-stage

approach, assigned according to the complexity and nature of the wound. A clinico-surgical algorithm was followed based on severity of GSWI.

For clarity of understanding the authors have presented one such case of immediate reconstruction post GSWI which markedly improved the quality of life of the patient. A 25-year-old male reported to the casualty with accidental self-inflicted GSWI with a pistol. The bullet entrance wound was oval approximately 2 cm in diameter along the left corner of mouth region with no exit wound. The patient was fully conscious, well oriented to time, place, person and event. His vital signs were within normal limits. On inspection, there was a puncture wound 2cm below the corner of the mouth on the left side, multiple fractured segments visible on body of mandible on left sides, occlusal derangement and Coleman sign. Provisional diagnosis of left mandibular body fracture. USG neck, routine investigations and CT scan confirmed the diagnosis (Figure 1).

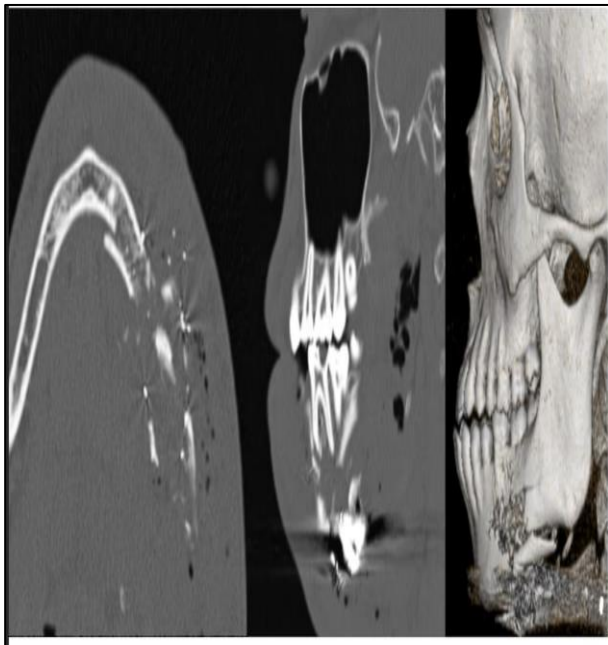


Figure 1: Computed tomography images in axial (left), sagittal (middle) and 3D reconstructive view (right) showing comminuted fracture of body of left mandible with presence of hyper dense particles suggestive of pellet within the GSWI.

The patient was hemodynamically stable and airway was secured via nasotracheal intubation. Surgical site was prepared and access was achieved via submandibular incisions. Facial artery and vein were identified and ligated. Fracture site was exposed and after careful exploration, non-jacketed bullet fragments/pellets were removed. A 4x1.6x1.5 cm corticocancellous block graft was harvested from anterior iliac crest and stabilised with reconstruction plate and wires to rebuild the deficient mandible (Figure 2). The healing was uneventful and the patient was followed up until 6 months (Figure 3).

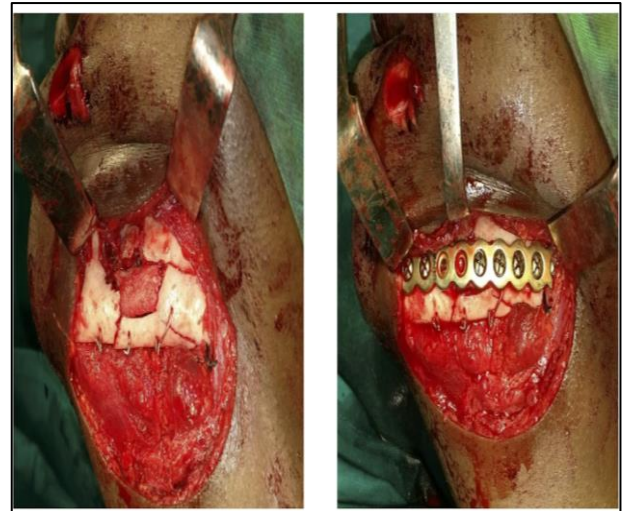


Figure 2: Comminuted fracture of mandible being stabilized by into-osseous working and iliac crest graft placed at the centre to help restore bony continuity (Left). Rigid fixation done with reconstructive plates and secured with bicortical screws (Right).



Figure 3: 3-months post operative extra oral images of the patient.

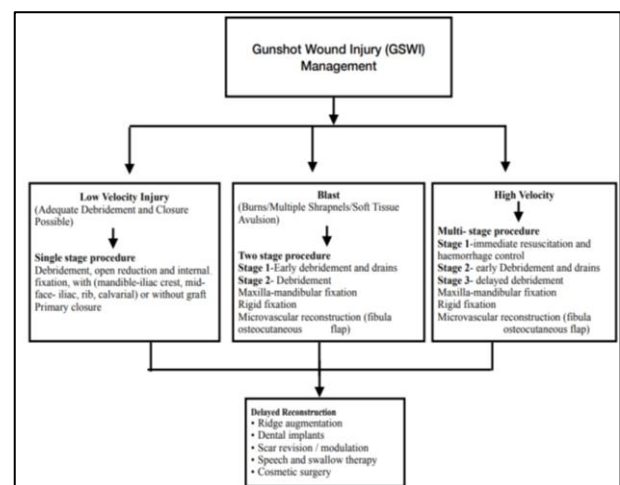


Figure 4: GSWI management algorithm.

DISCUSSION

Gunshot wounds atone for around 6% of cases in the maxillofacial region, of which 22% involve the mandible. Suicidal attempts top the list followed by assaults and accidental injuries.^{10,11} The Projectile popularly known as the bullet crushes structures along its path leading to primary cavitation. This results in tissue recoil and heat production, soft tissue collapses, shearing and compression causing secondary cavitation. Additionally, kinetic energy transfer occurs during retardation of the bullet which may cause damage outside the tract known as the tumbling effect.

Entrance wounds are usually circular or oval aspect, with slightly irregular borders, and may be accompanied by abrasion collar, lubricant ring, stippling affect due to soot deposits. The exit orifice on the other hand characterized by large sized irregular wounds, with everted borders and fat stranding.^{12,13}

These GSWI are classified as a) penetrative (a wound involving the body surface extending into the underlying tissue or into bony cavity), b) Avulsive (a wound that rips off the skin, which causes maximum soft tissue damage), c) Perforative (a wound in which an object enters the body and passes all the way through).^{2,14,15}

Airway management is the primary concern in patients with maxillofacial ballistic injuries as compromised airway can be fatal. Although there are many options to secure airway, each have specific indications, the choice ultimately depends on the patient's situation and the expertise of the trauma team. Hollier et al estimated that 21% of patients requiring tracheostomy had lower third facial injury.^{14,15} This could be due to intra-oral bleeding which prevented endotracheal intubation, distortion of oropharyngeal anatomy, and the fear of oedema compromising airway.

Three-dimensional computed tomography (3DCT), and contrast enhanced computed tomography (CECT) have facilitated projectile visualisation, fracture assessment and possible involvement of critical structures.^{6,9,12}

It has been demonstrated that early surgical debridement plays an important role in minimising tissue loss.¹⁶ Entry and exit wounds can be closed primarily following careful debridement and extensive irrigation. Owing to the excellent blood supply in the head and neck, primary closure may follow surgical debridement of non-vital tissues.¹⁷

Bone grafts can be used in defects larger than 5 mm in the midface and mandible regions. Iliac crest bone is typically used in mandibular defects. Other option for mandibular defects is the use of synthetic bone graft or microvascular free tissue transfer. Free fibular osteocutaneous flap is a standard method to reconstruct mandibular defects larger than 6 cm. The appropriate

options for midface defects are iliac crest, cranium, and rib.

Literature suggest that retrieval of metal debris is important because lead is soluble in the system and may cause systemic toxicity which has been reported as early as 48 hours post injury.¹⁸ However, some authors also pointed out that if the bullet/fragments are lodged deep within the soft tissue with no functional deficit or major aesthetic defect, it could be left in situ.

Antibiotics play a major role in preventing infections after primary closure of GSWI. Adequate wound debridement, fixation, hermetic wound closure, adequate drainage, nutrition and fluid resuscitation is mandatory. The haemodynamics should be addressed as the oxygen-carrying capacity influences the wound healing and infection control.^{16,18} Infection rates between delayed and immediate post-gunshot wound reconstruction were reportedly similar.¹⁸ The delayed group demonstrated an increased incidence of wound contracture, which resulted in significantly more structural and functional deformity.

Immediate reconstruction prevents the cascade of soft tissue infection which may delay healing, bone graft infection and soft-tissue contracture. It not only allows soft tissue healing but also restores original contour, stretch, and pliability. Moreover, fewer and less complex revisionary procedures are necessary for patients who undergo immediate definitive reconstruction.¹⁹ Hence our surgical algorithm serves as a tool in decision-making for immediate (single stage) or delayed (multiple stage) management of GSWI based on the nature and complexity of the injury. The authors believe this algorithm would help young surgeons to understand the management of GSWI and predictably treat their cohort of patients (Figure 4).

CONCLUSION

GSWI pose a serious challenge for the reconstructive surgeons due to significant deficiency of soft tissue and bone. Given the complexity and diversity of injury associated with facial gunshot wounds, a systematic algorithm is essential to help manage the different stages of healing and to ensure that the best outcome is achieved.

Funding: No funding sources

Conflict of interest: None declared

Ethical approval: Not required

REFERENCES

1. Thorne CH. Gunshot wounds to the face. *Current concepts.* Clin Plast Surg. 1992;19:233e244.
2. Clark N, Birely B, Manson PN. High energy ballistic and avulsive facial injuries:classification, patterns, and an algorithm for primary reconstruction. *Plast Reconstr Surg.* 1996;98:583e601.

3. DeMuth Jr WE. The mechanism of shotgun wounds. *J Trauma.* 1971;11:219e229.
4. Vayvada H, Menderes A, Yilmaz M. Management of close-range, high energy shotgun and rifle wounds to the face. *J Craniofac Surg.* 2005;16: 794e804.
5. Kihitir T, Ivatury RR, Simon RJ. Early management of civilian gunshot wounds to the face. *J Trauma.* 1993;35:569e575.
6. Suominen E, Tukiainen E. Close range shotgun and rifle injuries to the face. *Clin Plast Surg.* 2001;28:323e337.
7. Gruss JS, Antonyshyn O, Phillips JH. Early definitive bone and soft-tissue reconstruction of major gunshot wounds of the face. *Plast Reconstr Surg.* 1991;87:436e450.
8. Olding M, Winski FV, Aulisi E. Emergency free flap reconstruction of a facial gunshot wound. *Ann Plast Surg.* 1993;31:82e86.
9. Vitkus K, Vitkus M. Microsurgical reconstruction of shotgun-blast wounds to the face. *J Reconstr Microsurg.* 1990;6:279e286.
10. Maki MH. Management outline of oral and maxillofacial missile injuries in Iraq. *J Craniofac Surg.* 2009;20(3):873-877.
11. Bidra AS, Veeranki AN. Surgical and prosthodontic reconstruction of a gunshot injury of the mandible using dental implants and an acrylic resin fixed prosthesis: A clinical report. *J Prosthet Dent.* 2010;104(3):142-8.
12. Guevara C. Maxillofacial gunshot injuries: a comparison of civilian and military data. *J Oral Maxillofac Surg.* 2017;74(4):795.e1-7.
13. Yoganandan Narayan and Frank A Pintar. "Biomechanics of penetrating trauma". *Critical Reviews TM in Biomedical Engineering.* 1997;25(6):485-501.
14. Lindsey D. The idolatry of velocity, or lies, damn lies, and ballistics. *J Trauma.* 1980;20:1068e1069.
15. Hollier L, Grantcharova EP, Kattash M. Facial gunshot wounds: a 4-year experience. *J Oral Maxillofac Surg.* 2001;59:277e282.
16. Mohan R, Iyer R, Thaller S. Airway management in patients with facial trauma. *J Craniofac Surg.* 2009;20:21e23.
17. Baig MA. Current trends in the management of maxillofacial trauma. *Ann R Australas Coll Dent Surg.* 2002;16:123e127.
18. Motamedi MH. Primary treatment of penetrating injuries to the face. *J Oral Maxillofac Surg.* 2007;65:1215e1218.
19. Peled M, Leiser Y, Emodi O, Krausz A. Treatment protocol for high velocity/high energy gunshot injuries to the face. *Craniofac Trauma Reconstr.* 2012;5(1):31-40.

Cite this article as: Rodrigues E, Kamat S, Naik S, Chodankar N, Dhupar V, Akkara F. A novel clinico-surgical algorithm for management of maxillofacial gunshot wound injuries. *Int Surg J* 2023;10:1216-9.