

Case Report

Acute appendicitis complicated by ovarian vein thrombosis

Deep P. Talreja¹, Rani B. Talreja², Ahmed M. Elsayed¹, Simran Parkash¹,
Ismail M. Al-Qanubi¹, Ayman A. Albatanony^{1*}

¹Department of General Surgery, ²Department of Obstetrics and Gynaecology, Ibra Hospital, North Sharqiya, Oman

Received: 22 April 2023

Accepted: 17 May 2023

*Correspondence:

Dr. Ayman A. Albatanony,
E-mail: aymanalbatanony@gmail.com,

Copyright: © the author(s), publisher and licensee Medip Academy. This is an open-access article distributed under the terms of the Creative Commons Attribution Non-Commercial License, which permits unrestricted non-commercial use, distribution, and reproduction in any medium, provided the original work is properly cited.

ABSTRACT

Ovarian vein thrombosis (OVT) is a rare cause of acute abdominal pain and is mainly related to pregnancy and affects approximately 1 in every 2,000 deliveries and abortions. However, this diagnosis should be considered not only in postpartum patients but also in women with pelvic inflammatory disease (PID), malignancy, women who have recent abdominal surgery and who have a known hypercoagulable state. Anticoagulation and antibiotics are the mainstays of treatment for OVT. Complications of OVT include sepsis, the extension of the thrombus to the inferior vena cava and renal veins, and pulmonary embolism. The incidence of pulmonary embolism is reported to be 13.2% and represents the main cause of mortality due to OVT. We report a case of 40-years old female patient presenting with OVT, which was accompanied by acute appendicitis. In this woman, OVT was not related to pregnancy. The patient underwent an appendectomy, which proved positive on histopathology result. Patient symptoms improved after appendectomy with antibiotics and anticoagulation therapy. A month later, a follow-up computed tomography (CT) scan of the abdomen revealed a complete resolution of OVT. OVT, though a rare presentation, should be included in the differential diagnosis for women presenting with acute abdomen. Proper diagnosis and timely management can prevent catastrophic complications. Our case thus highlights the importance of considering the rare diagnosis of OVT with acute appendicitis.

Keywords: Ovarian vein, Thrombosis, Acute appendicitis, Gonadal vessels thrombosis, Appendectomy

INTRODUCTION

The right ovarian vein joins the inferior vena cava (IVC) below the right renal vein, and the left ovarian vein drains into the left renal vein.¹⁻³ The best area to observe the ovarian veins is at the level of the inferior mesenteric artery origin, where both veins are surrounded by retroperitoneal fat.⁴⁻⁶ Most ovarian vein thromboses occur on the right side (70–90% of cases) and bilateral ovarian vein thrombosis (OVT) occur in 11–14%.^{7,8} The differential diagnosis of OVT includes (among others) acute appendicitis, pelvic inflammatory disease, tubo-ovarian abscess, and ovarian torsion.^{9,10} Thrombophilic evaluation is essential in all cases of OVT, especially cases with non-pregnancy-related OVT.^{1,4,7} Contrast enhanced computed tomography (CT) scan is currently considered the diagnostic imaging modality of choice.^{11,12} This is

because the sensitivity of a CT scan is reported to be 95%, while the sensitivity of Doppler ultrasonography is only approximately 50%.¹³ The treatment is generally conservative (IV heparin and antibiotics), but surgery may be indicated in rare clinical situations to treat underlying disorders.^{14,15}

CASE REPORT

A 47-year-old female gravida 9, para 8 (all were normal deliveries) presented to the emergency room with a two days' history of right lower colicky abdominal pain and right flank pain associated with low grade fever (37.7 C), vomiting once, dysuria and relative constipation. She is a known case of non-toxic multi-nodular goiter, internal piles, and left lower limb varicose veins.

She has no medical co-morbidities, hematological disorders nor history of surgeries. Her menstrual history was insignificant except a positive injectable contraceptive history for 2 years. She had a history of spontaneous abortion in 6 weeks of pregnancy 2 years ago. On examination, she had a tender right lower quadrant abdomen, more at the right iliac fossa with rebound tenderness. Skin varicosities were noticed in the posterior aseptic region of the left thigh, extending to the back of the knee. Her chest and pelvic examinations were unremarkable.

Blood studies showed haemoglobin (Hb) 13.9 g%, raised white blood cell (WBC) of 13.29, with raised neutrophils of 11.48. Her C-reactive protein (CRP) was 1.95, lactate 2, amylase 75, a slightly raised thyroid stimulating hormone (TSH), free T4 16.1, CA-12, and a co-coagulation profile that were within normal limits. Details are given in Table 1.

Abdomen and pelvis ultrasound reported normal with non-visualization of the appendix. On the clinical suspicion of acute appendicitis, a contrast CT of the abdomen was arranged. Diagnosis of acute appendicitis with right ovarian vein thrombosis was established on contrast CT abdomen. CT revealed an appendix with a distended, 10 mm-thick enhanced mucosal wall, endoluminal dense fecolith, and regional fat stranding, features suggesting acute appendicitis (Figure 1). The right ovarian vein is mildly dilated, with no obvious contrast opacification in a portion diagnosed as venous thrombosis without extent to IVC (Figure 2). Grey-scale and colored Doppler US shows a hyperechoic thrombus filling and distending the upper part of the right ovarian vein with a partly colored flow.

Further laboratory investigations were performed to evaluate the underlying cause of the thrombosis, including factor V Leiden mutation, ANA, lupus anticoagulant, anticardiolipin antibody, beta-2 microglobulin, and JAK2 mutation, which were all negative (Table 1). Other thrombophilia tests, such as anti-thrombin III, the methylene-tetra-hydro-folate reductase (MTHFR) gene, and protein C, were not performed.

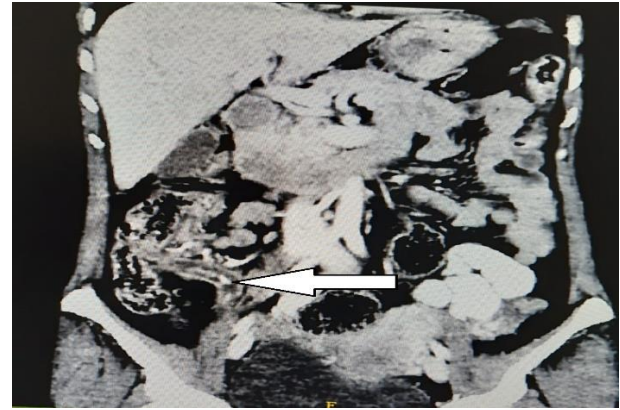


Figure 1: CT abdomen showing inflamed appendix with faecolith inside.

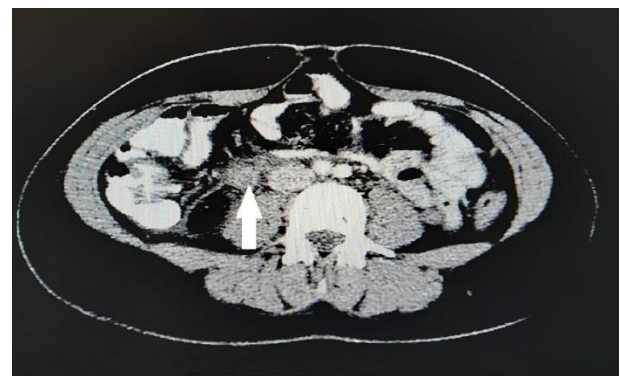

Figure 2: CT Angiography showing a thrombus in the right ovarian vein.

The patient underwent an appendectomy for acute appendicitis. Six hours after surgery, anticoagulation therapy was started, initially with subcutaneous LMW-heparin 2000 IU subcutaneously once a day for 10 days bridged to Warfarin for one month with standard monitoring of APTT and INR in between the range of 2-3. Patient was managed by a multidisciplinary team approach involving general surgeons, gynecologists, and hematologists. On the 2nd month of follow-up, CT abdomen revealed complete resolution of OVT.

Table 1: Investigation.

| Investigations | Results | Normal reference |
|--|---------------------------|------------------|
| Factor V Leiden mutation | Negative | - |
| ANA CTD screening | Negative | - |
| Lupus anticoagulant (seconds) | 30 | 30-45.3 |
| Anti-cardiolipin IgG IgM Ab (MPL) | 3.10GPL/2.30 MPL | Negative |
| B-HCG (mIU/ml) | 0.3 | 0.0-5.0 |
| AFP (IU/ml) | 3 | 0-6 |
| JAK2 mutation | Absence of V617F missense | - |
| Beta 2 microglobulin (mg/dl) | 1.10 | 0.97-2.64 |
| Thyroid stimulating hormone (m (iU)/ml) | 5.12 | 0.27-4.2 |
| Free T4 (pmol/l) | 16.08 | 9.8-23.8 |
| C-reactive protein (mg/l) | 1.95 | 0-5 |
| Prothrombin time (seconds) | 11.90 | 9.70-12.9 |

Continued.

| Investigations | Results | Normal reference |
|--|----------------------------|-----------------------------|
| Activated partial thromboplastin time (seconds) | 27.70 | 22.3-31.5 |
| International normalization ratio (INR) time (seconds) | 1.26 | 0.82-1.05 |
| Fibrinogen (g/l) | 4.81 | 1.5-4.2 |
| Thrombin time (seconds) | 14.00 | 14-21 |
| Haemoglobin (g/dl) | 13.90 | 11-14.5 |
| Platelet count | 274.00×10 ³ /U1 | 150-450×10 ³ /U1 |

DISCUSSION

OVT is a rare condition that presents with abdominal pain and can mimic an acute abdomen. Patients usually present with abdominal pain, which simulates acute appendicitis (when on the right side) or renal colic.¹⁶ An OVT diagnosis may be overlooked, especially in patients outside the peri-partum period. OVT must be differentiated from acute appendicitis, pelvic inflammatory disease, tubo-ovarian abscess, ovarian torsion and others.^{17,18} Most of the patients present with fever. Other common presentations include tachycardia, nausea, and vomiting. Imaging perspective: contrast-enhanced CT is the modality of choice.^{19,20}

In our case, the CT revealed distended right ovarian vein with acute appendicitis, proven on histopathology. Complications of OVT include sepsis and extension of the thrombus to the IVC and renal veins. The most common source of mortality is pulmonary embolism, with an incidence reported as high as 13% and a 4% risk of mortality.^{21,22}

Teaching points OVT should be included in the differential diagnosis of right lower quadrant pain. It may be overlooked in patients outside the peri-partum period. Imaging has an important role in the diagnosis, management, and follow-up of patients with OVT.^{22,23}

The most favorable treatment of choice is a combination of anticoagulation and antibiotics.¹⁸ However, a recent study supports the use of anticoagulation alone. Antibiotic choices are like those used in septic pelvic thrombophlebitis and consist of intravenous agents like imipenem and cilastatin, ampicillin and sulbactam, clindamycin, and gentamicin. The duration of antibiotic treatment is 48–72 hours. Anticoagulation is recommended for at least 7–10 days.²¹⁻²³

In our case, the patient has acute appendicitis complicated by ovarian vein thrombosis, or acute appendicitis accompanied by ovarian vein thrombosis is unclear. The literature review shows that complicated appendicitis can be associated with mesenteric thrombosis, however to our knowledge, very less data supports that acute appendicitis was complicated by ovarian vein thrombosis. After appendectomy with postoperatively short-term treatment by anticoagulation LMWH and antibiotics, there was a complete resolution of ovarian vein thrombosis as confirmed on follow up CT abdomen. In follow up period patient was improved and symptoms free.

CONCLUSION

Ovarian vein thrombosis should be taken into account in cases of lower abdominal pain and fever in each female in the childbearing period, not only in postpartum females. A prompt diagnosis of OVT is required to prevent serious complications. Intravenous contrast computed tomography is the investigation of choice for diagnosis.

ACKNOWLEDGMENTS

Authors would like to thank the patients and her family for consenting to the publication of this article.

Funding: No funding sources

Conflict of interest: None declared

Ethical approval: Not required

REFERENCES

1. Tan JW, Howe HS, Chng HH. Ovarian vein thrombosis in Behçet disease. *J Clin Rheumatol*. 2012;18:89-91.
2. Riva N, Calleja-Agius J. Ovarian vein thrombosis: a narrative review. *Hämostaseologie*. 2021;41:257-66.
3. Covut F, Kewan T, Perez O, Thapa B, Babar A, Alomari M, et al. Direct oral anticoagulants versus warfarin and enoxaparin in ovarian vein thrombosis. *Am J Ther*. 2021;28:3.
4. Abbattista M, Capecchi M, Martinelli I. Treatment of unusual thrombotic manifestations. *Blood*. 2020;30:326-34.
5. Riva N, Calleja-Agius J. Ovarian vein thrombosis: a narrative review. *Hamostaseologie*. 2021;41(4):257-66.
6. Valerio L, Riva N. Head, neck, and abdominopelvic septic thrombophlebitis: current evidence and challenges in diagnosis and treatment. *Hamostaseologie*. 2020;40:301-10.
7. Alalqam MM, al Abbas R, Abualsaud AS, AlQattan AS, Almabyouq F. The challenges of diagnosing idiopathic ovarian vein thrombosis: Case report. *Int J Surg Case Rep*. 2019;60:63-5.
8. Rivaroxaban and apixaban for initial treatment of acute venous thromboembolism of atypical location. Janczak DT, Mimier MK, McBane RD, Kamath PS, Simmons BS, Bott-Kitslaar DM, et al. *Mayo Clin Proc*. 2018;93:40-7.
9. Bannow BT, Skeith L. Diagnosis and management of postpartum ovarian vein thrombosis. *Hematology Am Soc Hematol Educ Program*. 2017;2017:168-71.

10. Lenz CJ, Wysokinski WE, Henkin S, Cohoon KP, Casanegra A, Simmons BS, et al. Ovarian Vein Thrombosis: Incidence of Recurrent Venous Thromboembolism and Survival. *Obstet Gynecol.* 2017;130(5):1127-35.
11. Bannow BTS, Skeith L. Diagnosis and management of postpartum ovarian vein thrombosis. *Hematology Am Soc Hematol Educ Program.* 2017;2017:168-71.
12. Lenz CJ, Wysokinski WE, Henkin S, Cohoon KP, Casanegra A, Simmons BS, et al. Ovarian Vein Thrombosis: Incidence of Recurrent Venous Thromboembolism and Survival. *Obstet Gynecol.* 2017;130(5):1127-35.
13. Rottenstreich A, Da'as N, Kleinstern G, Spectre G, Amsalem H, Kalish Y. Pregnancy and non-pregnancy related ovarian vein thrombosis: Clinical course and outcome. *Thromb Res.* 2016;146:84-8.
14. Dougan C, Phillips R, Harley I, Benson G, Anbazhagan A. Postpartum ovarian vein thrombosis. *Obstet Gynaecol.* 2016;18:291-9.
15. Rottenstreich A, Da'as N, Kleinstern G, Spectre G, Amsalem H, Kalish Y. Pregnancy and non-pregnancy related ovarian vein thrombosis: clinical course and outcome. *Thromb Res.* 2016;146:84-8.
16. Doherty K, New M. Idiopathic ovarian vein thrombosis in a non-peripartum patient. *Obstet Gynecol.* 2015;125:1468-70.
17. Labropoulos N, Malgor RD, Comito M, Gasparis AP, Pappas PJ, Tassiopoulos AK. The natural history and treatment outcomes of symptomatic ovarian vein thrombosis. *J Vasc Surg Venous Lymphat Disord.* 2015;3(1):42-7.
18. Labropoulos N, Malgor RD, Comito M, Gasparis AP, Pappas PJ, Tassiopoulos AK. The natural history and treatment outcomes of symptomatic ovarian vein thrombosis. *J Vasc Surg Venous Lymphat Disord.* 2015;3(1):42-7.
19. Cassinelli G, Naggi A. Old and new applications of nonanticoagulant heparin. *Int J Cardiol.* 2016;212:S14-21.
20. Labropoulos N, Malgor RD, Comito M, Gasparis AP, Pappas PJ, Tassiopoulos AK. The natural history and treatment outcomes of symptomatic ovarian vein thrombosis. *J Vasc Surg Venous Lymphatic Disord.* 2015;3(1):42-7.
21. Jenayah AA, Saoudi S, Boudaya F, Bouriel I, Sfar E, Chelli D. Ovarian vein thrombosis. *Pan Afr Med J.* 2015;21:251.
22. Harris K, Mehta S, Iskhakov E, Chalhoub M, Maniatis T, Forte F, Alkaied H. Ovarian vein thrombosis in the nonpregnant woman: an overlooked diagnosis. *Ther Adv Hematol.* 2012;3(5):325-8.
23. Bannow BTS, Skeith L. Diagnosis and management of postpartum ovarian vein thrombosis. *Hematology.* 2017;168-71.

Cite this article as: Talreja DP, Talreja RB, Elsayed AM, Parkash S, Al-Qanubi IM, Albatanony AA. Acute appendicitis complicated by ovarian vein thrombosis. *Int Surg J* 2023;10:1078-81.