

## Original Research Article

# Outcome of conjunctival flap surgery in case of non-healing corneal ulcer in a multi-specialty eye hospital of Northern Bangladesh

M. Kamruzzaman Khaja<sup>1\*</sup>, Khairul Islam<sup>2</sup>, M. Mahmud U. Islam<sup>1</sup>,  
Sonia A. Tumpa<sup>3</sup>, M. Sajidul Huq<sup>4</sup>

<sup>1</sup>Department of Cornea and Anterior Segment, Deep Eye Care Foundation, Rangpur, Bangladesh

<sup>2</sup>Department of Cataract and General Ophthalmology, Deep Eye Care Foundation, Rangpur, Bangladesh

<sup>3</sup>Department of Glaucoma, Deep Eye Care Foundation, Rangpur, Bangladesh

<sup>4</sup>Department of Training and Research, Deep Eye Care Foundation, Rangpur, Bangladesh

**Received:** 09 April 2023

**Revised:** 06 May 2023

**Accepted:** 12 October 2023

### \*Correspondence:

Dr. M. Kamruzzaman Khaja,

E-mail: [drkamruzzamanj@gmail.com](mailto:drkamruzzamanj@gmail.com)

**Copyright:** © the author(s), publisher and licensee Medip Academy. This is an open-access article distributed under the terms of the Creative Commons Attribution Non-Commercial License, which permits unrestricted non-commercial use, distribution, and reproduction in any medium, provided the original work is properly cited.

## ABSTRACT

**Background:** This retrospective study evaluates the outcomes of conjunctival flap surgery for non-healing corneal ulcers at a tertiary eye hospital that were resistant to medical treatment.

**Methods:** The study included 47 eyes of 47 patients with deep corneal ulcers who underwent conjunctival flap surgery in a multi-specialty eye hospital between April 2020 and January 2022. The follow-up period was 12 months. Primary outcome measures included the restoration of ocular surface integrity, while secondary outcomes assessed improvements in visual acuity and postoperative complications.

**Results:** Among the 47 patients, 30 (63.82%) were male, and 17 (36.17%) were female, with a mean age of 52.13±14.91 years. The mean ulcer diameter was 4.52±2.02 mm, and the mean ulcer depth was 65±22.20% of the corneal thickness. An anatomic cure was achieved in 34 (72.34%) of the 47 eyes. Three eyes that failed to respond to conjunctival flap surgery required evisceration. Postoperative visual acuity improved in 15 eyes with peripheral ulcers. Common postoperative complications included flap retraction, flap necrosis, granuloma formation, and perforation.

**Conclusions:** Conjunctival flap surgery is an effective treatment for non-healing corneal ulcers, providing ocular surface integrity and supporting corneal healing. It can potentially eliminate the need for emergency penetrating keratoplasty or prepare the eye for future optical keratoplasty.

**Keywords:** Non-healing corneal ulcer, Conjunctival flap, Gunderson flap

## INTRODUCTION

Corneal diseases represent a significant global challenge, silently afflicting many with blindness. These conditions arise from a complex interplay of inflammatory and infectious diseases, leading to corneal scarring and functional blindness. The prevalence of these conditions varies not only between countries but also among different populations, and they are often underreported. Particularly alarming is the estimation that 1.5 to 2 million cases of corneal blindness are newly diagnosed each year, mainly

attributed to ocular trauma and infectious keratitis, particularly in developing countries.<sup>1</sup> Despite the availability of antimicrobial treatments targeting the microorganisms responsible for infectious keratitis, clinical outcomes are frequently suboptimal. Corneal ulcerations, and more critically, corneal perforations, pose a pressing concern, demanding immediate intervention to prevent severe ocular complications, such as evisceration or enucleation.<sup>2</sup> While a range of medical treatments exists, it's important to note that in severe cases, the only viable solution is surgical intervention. The immediate

objectives of this surgical approach are twofold: firstly, to effectively seal the ulcerated or perforated area, and secondly, to offer crucial tectonic support. These objectives are paramount as they serve to prevent the development of severe ocular complications that could ultimately necessitate evisceration or enucleation.<sup>3</sup> Conjunctival flap surgery emerges as a straightforward, effective, and cost-efficient approach to addressing corneal ocular surface diseases that do not respond to conventional medical treatment.<sup>4</sup> This surgical procedure aims to establish a stable ocular surface and mitigate local inflammation. While the utilization of conjunctival flap surgery has diminished in developed nations following advancements in therapeutic penetrating keratoplasty, amniotic membrane transplants, and epithelial transplant techniques, it continues to offer value, particularly in specific cases or when donor tissue, surgical instruments, or surgical expertise for alternative methods are unavailable.<sup>5-7</sup> Conjunctival flap surgery also introduces a range of secondary benefits, including pain alleviation, reduced reliance on topical medications, aesthetic improvements, and even an alternative to invasive surgeries.<sup>8,9</sup>

In certain scenarios, it may serve as a temporary measure in preparation for future corneal transplantation.<sup>10</sup> This retrospective study seeks to assess the efficacy of conjunctival flap surgery in treating non-healing corneal ulcers that have proven resistant to conventional medical treatments.

## **METHODS**

### ***Study design and patients***

This retrospective study was conducted at the Deep Eye Care Foundation, an eye hospital in Bangladesh. The study included 47 patients who had undergone conjunctival flap surgery for non-healing corneal ulcers between April 2020 and January 2022. Medical records were meticulously reviewed, and relevant data were extracted from patient case records. Information collected encompassed demographic details such as age, gender, living environment, duration of symptom onset, causes of ulceration, uncorrected visual acuity (UCVA), best-corrected visual acuity (BCVA), intraocular pressure (IOP), and predisposing factors, including previous or ongoing topical or systemic treatments, systemic disorders, contact lens wear, and ocular trauma. The obtained data were entered into Microsoft excel sheet and analysed using the statistical package for the social sciences (SPSS) version 25.

### ***Inclusion criteria***

Patients who underwent conjunctival flap surgery for non-healing corneal ulcers, and patients with deep non-healing corneal ulcers, including those with over 50% loss of stroma, descemetocoele, or corneal perforation were included.

### ***Exclusion criteria***

Patients who did not undergo conjunctival flap surgery, and cases with incomplete data, including age, gender, and clinical parameters were excluded.

### ***Preoperative evaluation***

All patients underwent a comprehensive ophthalmic assessment. Recorded symptoms included pain, redness, photophobia, tearing, and discharge. The evaluation focused on visual acuity testing (UCVA and BCVA) and involved a detailed slit-lamp examination of the conjunctiva, cornea, anterior chamber, iris, pupil, and lens. Additionally, the presence of neovascularization, synechiae, hypopyon, ulcer size, ulcer site, ulcer staining, and corneal infiltrates was meticulously noted.

### ***Surgical technique***

Conjunctival flap surgeries were performed by the same surgeon. The procedures were carried out in a sterile surgical theater with patients in a supine position under an operating microscope. A peribulbar anesthesia was administered to the affected eye, followed by the application of povidone iodine with a cotton ball to sterilize the eye. After draping the eye, an eye speculum was inserted. The corneal epithelium and necrotic tissue within 1 mm of the ulcer margin were meticulously removed using a surgical blade. Subsequently, a tongue-shaped incision was made in the conjunctiva from the underlying Tenon's capsule, originating from the temporal side. The resulting conjunctival flap (Figure 1) was mobilized to cover the corneal ulcer and was securely fastened to the conjunctival flap created at 6 O'clock using interrupted 6-0 Vicryl sutures.

Following the surgical procedure, topical antibiotics were applied, and the eye was dressed. Suture removal was performed after two weeks.

### ***Postoperative evaluation***

The follow-up period extended to 12-months post-surgery. Postoperative evaluations included visual acuity testing (UCVA and BCVA), IOP measurements, slit-lamp examinations of the cornea (with attention to ulceration, edema, and neovascularization), and assessments of the anterior chamber (noting inflammation, synechiae, and hypopyon). The use of fluorescein staining was employed to detect corneal epithelial defects, and anterior segment optical coherence tomography (AS-OCT) was conducted to evaluate the corneal tissue adjacent to the conjunctival flap (Figure 2).

### ***Ethical approval***

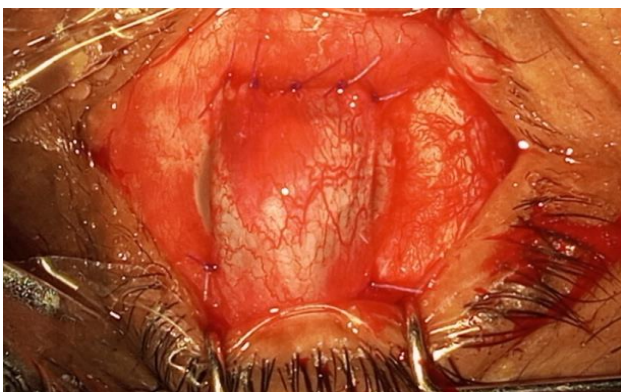
The study received ethical approval from the institutional review board of Deep Eye Care Foundation, Bangladesh.

**RESULTS**

A total of 47 eyes from 47 patients were included in the study, with 30 patients (63.82%) being male and 17 patients (36.17%) female. The majority of the patients fell within the age group of 41 to 60 years, with a mean age of 52.13±14.91 years (Table 1). The causes of corneal ulcers were categorized as infectious in 31 cases (65.96%), non-infectious in 12 cases (25.53%), and unknown in 4 cases (8.51%) (Table 1). Among the infectious ulcers, there were 9 cases of bacterial, 2 cases of viral, and 20 cases of fungal keratitis. Noninfectious ulcers included 4 cases of bullous keratopathy, 3 cases of neurotrophic keratitis, 4 cases post-pterygium surgery, and 1 case due to a foreign body. In 4 eyes, the etiology of the corneal ulcer remained unknown, with 2 of them presenting with a central perforation. The mean diameter of the ulcers was 4.52±2.02 mm, and the mean depth of the ulcers was 65±22.20% of the corneal thickness. An anatomic cure was achieved in 34 out of the 47 eyes (72.34%).

**Table 1: Baseline characteristics of the respondents.**

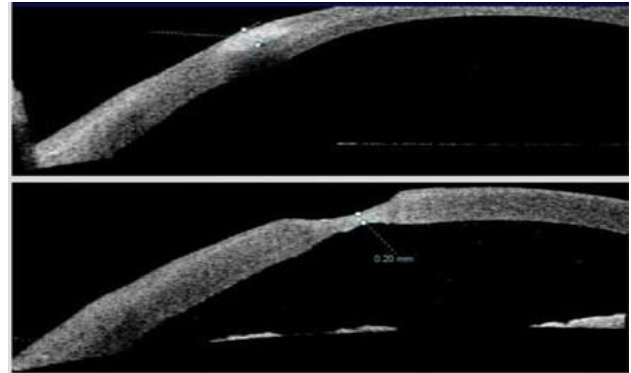
Characteristics	Frequency (n)	Percent (%)
<b>Sex</b>		
Female	17	36.17
Male	30	63.82
<b>Age group (years)</b>		
<18	2	4.3
18-40	6	12.8
41-60	27	57.4
>60	12	25.5
<b>Aetiology of corneal ulcer</b>		
Infectious	31	65.96
Non-infectious	12	25.53
Unknown	4	8.51
Total	47	100.0



**Figure 1: Conjunctival flap surgery.**

However, conjunctival flap surgery was unsuccessful in 3 eyes, which ultimately required evisceration. One of these cases involved a central corneal ulcer due to viral keratitis, where flap perforation led to a secondary corneal perforation, necessitating additional surgery such as a

patch graft using available tissue. The other cases also required evisceration. Among the 47 patients, 7 developed necrosis of the flap, while 4 experienced flap retraction. In these cases, re-stitching of the conjunctival flap was performed, resulting in the resolution of issues related to the operated eye. Postoperatively, visual acuity improved in 15 eyes following the release of a hood in cases of peripheral ulcers (Table 2). The postoperative best-corrected visual acuity (BCVA) showed improvement in 15 out of 47 cases (31.92%) in cases of peripheral ulcers, decreased in 22 cases (46.80%) due to flap-related issues, and remained unchanged in 10 cases (21.28%) (Table 2).



**Figure 2: AS-OCT evaluation of a corneal ulcer: pre and post-operative.**

**Table 2: Patient outcomes.**

Characteristics	Frequency (n)	Percent (%)
<b>Post-operative visual acuity (BCVA)</b>		
Improved	15	31.91
Decreased	22	46.81
Remain unchanged	10	21.28
<b>Post-operative complication</b>		
Flap necrosis	7	14.89
Flap displacement	4	8.51
Anterior (corneal) staphyloma	1	2.13
Perforation	1	2.13
No complication	34	72.34

**DISCUSSION**

Conjunctival flap surgery has demonstrated its effectiveness in the treatment of corneal ulcers over time. This therapeutic approach leverages several mechanisms to promote healing. Firstly, the flap acts as a barrier, preventing tears, proteolytic enzymes, and proinflammatory mediators from further exacerbating stromal ulceration.<sup>10</sup> Additionally, the rich vascular and lymphatic supply provided by the flap offers essential nutrients, including cellular components and growth factors. These factors enhance resistance to infection and contain anti-collagenolytic substances that inhibit stromal lysis.<sup>11,12</sup>

In our study, we employed a selective, partial, pedicle conjunctival surgery technique, where the flap was mobilized exclusively over the ulcerated cornea. This approach diverged from the total conjunctival flap technique introduced by Gundersen, which covers the entire cornea. The advantage of our method lies in its ability to offer a viable alternative to Gundersen's flap while mitigating some of its associated complications.

An anatomic cure was achieved in 34 out of 47 eyes (72.34%) in our study, with only 3 eyes ultimately requiring evisceration due to complications. Of the initial 7 corneal perforations included in the study, 5 were able to recover and regain anatomical integrity.

It's noteworthy that most patients in our study required conjunctival flap surgery not primarily for visual acuity improvement but to prevent or treat corneal perforations and preserve the integrity of the ocular globe. Despite this focus, postoperative visual acuity (BCVA) showed improvement in 15 out of 47 cases (31.91%). In 22 cases (46.81%), there was a decrease in visual acuity, while in 10 cases (21.28%), it remained unchanged. It is important to emphasize that in such cases, the decreased or unchanged postoperative visual acuity does not necessarily signify the failure of conjunctival flap surgery.

Out of the 47 patients, 28 underwent only one surgical intervention, while 19 required additional surgeries, including removal of the conjunctival flap, repeat flap surgery, cataract surgery, penetrating keratoplasty, and evisceration. The need for subsequent surgeries should not be interpreted as a failure of the initial conjunctival flap surgery but rather underscores the severity and complexity of the underlying disease.<sup>13</sup>

However, it is important to acknowledge the limitations of this study, which include the relatively small number of cases and the diverse range of etiologies for corneal ulcers. Consequently, drawing definitive conclusions regarding the efficacy of pedicle conjunctival flap surgery in specific etiologies is challenging. Future studies with larger case series are warranted to further investigate this subject.

## CONCLUSION

Conjunctival flap surgery has proven to be a successful intervention for treating refractory deep corneal ulcers. It not only restores the integrity of the ocular surface but also provides essential metabolic and mechanical support for corneal healing. Moreover, it offers a critical alternative to emergency penetrating keratoplasty, which is especially valuable in regions with limited access to corneal tissue.

*Funding: No funding sources*

*Conflict of interest: None declared*

*Ethical approval: The study was approved by the Institutional Ethics Committee*

## REFERENCES

1. Raj A, Bahadur H, Dhasmana R. Outcome of therapeutic penetrating keratoplasty in advanced infectious keratitis. *J Curr Ophthalmol.* 2018;30(4):315-20.
2. Austin A, Lietman T, Rose-Nussbaumer J. Update on the Management of Infectious Keratitis. *Ophthalmology.* 2017;124(11):1678-89.
3. Bhatt P, Lim L, Ramaesh K. Therapeutic deep lamellar keratoplasty for corneal perforations. *Eye.* 2007;21:1168-73.
4. Gundersen T, Pearlson HR. Conjunctival flaps for corneal disease: their usefulness and complications. *Trans Am Ophthalmol Soc.* 1969;67:78-95.
5. Lim LS, How AC, Ang LP, Tan DT. Gundersen flaps in the management of ocular surface disease in an Asian population. *Cornea.* 2009-08;28(7):747-51.
6. Zemba M, Stamate AC, Tataru CP, Branisteanu DC, Balta F. Conjunctival flap surgery in the management of ocular surface disease (Review). *Exp Ther Med.* 2020;20(4):3412-6.
7. Stamate AC, Tătaru CP, Zemba M. Emergency penetrating keratoplasty in corneal perforations. *Rom J Ophthalmol.* 2018;62(4):253-9.
8. Sandinha T, Zaher SS, Roberts F, Devlin HC, Dhillon B, Ramaesh K. Superior forniceal conjunctival advancement pedicles (SFCAP) in the management of acute and impending corneal perforations. *Eye (Lond).* 2006;20(1):84-9.
9. Jhanji V, Young AL, Mehta JS, Sharma N, Agarwal T, Vajpayee RB. Management of corneal perforation. *Surv Ophthalmol.* 2011;56(6):522-38.
10. Stamate AC, Tătaru CP, Zemba M. Update on surgical management of corneal ulceration and perforation. *Rom J Ophthalmol.* 2019;63(2):166-73.
11. Sharma A, Mohan K, Sharma R, Nirankari VS. Repositioning of pedicle conjunctival flap performed for refractory corneal ulcer. *Middle East Afr J Ophthalmol.* 2014; 21(1):89- 91.
12. Abdulhalim BE, Wagih MM, Gad AA, Boghdadi G, Nagy RR. Amniotic membrane graft to conjunctival flap in treatment of non-viral resistant infectious keratitis: a randomised clinical study. *Br J Ophthalmol.* 2015;99(1):59-63.
13. Zhou Q, Long X, Zhu X. Improved conjunctival transplantation for corneal ulcer. *Zhong Nan Da Xue Xue Bao Yi Xue Ban.* 2010;35(8):814-8.

**Cite this article as:** Khaja MK, Islam K, M. Islam MU, Tumpa SA, Huq MS. Outcome of conjunctival flap surgery in case of non-healing corneal ulcer in a multi-specialty eye hospital of Northern Bangladesh. *Int Surg J* 2023;10:1737-40.