

Original Research Article

Thrombolytic therapy as first line treatment in prosthetic mitral valve thrombosis

Sushrut Potwar, Ankur Kothari, Abhishek Potnis*, Malavika Paranjape

Department of Cardiovascular and Thoracic Surgery, Seth GS Medical College and King Edward Memorial Hospital, Mumbai, Maharashtra, India

Received: 31 March 2023

Revised: 03 May 2023

Accepted: 04 May 2023

***Correspondence:**

Dr. Abhishek Potnis,

E-mail: abhishekpotnis35586@gmail.com

Copyright: © the author(s), publisher and licensee Medip Academy. This is an open-access article distributed under the terms of the Creative Commons Attribution Non-Commercial License, which permits unrestricted non-commercial use, distribution, and reproduction in any medium, provided the original work is properly cited.

ABSTRACT

Background: A very common post-operative mechanical complication of a prosthetic valve is thrombosis leading to valve being stuck. This leads to rapid development of heart failure and can result in sudden death of the patient in an aggravated manner. The study aims to put forth the importance of immediate thrombolysis in such patients which can provide bridging between the event and immediate surgery.

Methods: A total of 50 patients were retrospectively studied after presentation with prosthetic valve thrombosis and the thrombolytic agent used in all the cases was injectable streptokinase or urokinase. Post streptokinase patients were given heparin infusion and oral anticoagulants. The therapy was considered failure if transvalvular gradients decreased less than 50% or in case of persistent valve motion abnormality.

Results: 94% patients had complete normalisation of valve function and decrease in transvalvular gradients to less than 50% within the first 24 hours. 4% patients required surgery and 2% patients could not survive the treatment.

Conclusions: Immediate thrombolysis on presentation has shown significant improvement in survival without the risk of subjecting patients to redo surgeries which are associated with multiple complications in the perioperative period.

Keywords: Prosthetic valve thrombosis, Transthoracic echocardiography, Transoesophageal echocardiography, Streptokinase, Urokinase

INTRODUCTION

The incidence of prosthetic valve thrombosis (PVT) during warfarin (coumadin) therapy is dependent on type of valves used, location of replacement and compliance to anticoagulation and averages 0.2% and 1.8%/patient-year, respectively.¹ PVT has a high incidence of 13% in the first year and 20% for tricuspid prostheses.^{2,3} Patients may be asymptomatic or may present with acute dyspnoea, embolic events, congestive cardiac failure or cardiogenic shock.⁴ The most common cause of PVT is inadequate anticoagulant therapy.⁵ Recent studies have shown that thromboembolism is more in the mitral prosthetic valve position (mechanical or biological) than with one in the aortic position.^{1,6} Bileaflet valves have a lower incidence

than the unileaflet, ball and cage or tilting disc mechanical prosthesis⁷. The objective of the present study was to observe the benefits of thrombolysis and identify suitable profile of patients benefiting most from the therapy.

METHODS

The study was retrospective in nature. A total of 50 patients were admitted at KEM Hospital, Mumbai for thrombosis of mechanical mitral valves between September 2016 to September 2022. Clinical presentation at time of diagnosis, fluoroscopy and transthoracic echocardiography (TTE) were mainstay in diagnosis. These patients were retrospectively analysed after institutional ethical approval as no prospective

intervention was planned. The statistical software used was SAS version 6.09 on the Unix platform. Considering observational nature of the study, no other computational software was required.

Inclusion criteria

Patients with thrombosis of mechanical mitral valves diagnosed with echocardiography and Doppler flow presenting with functional class 3 or 4 symptoms were considered for thrombolytic therapy in absence of any major contraindications.

Mitral mean diastolic transvalvular gradient >8 mmHg and inability to document movement of leaflets by TTE were considered indicative of thrombotic valve.

Exclusion criteria

Patients with active internal bleeding, history of haemorrhagic stroke, intracranial neoplasm, blood pressure > 200/120 mmHg and diabetic haemorrhagic retinopathy were considered absolute contraindications to thrombolytic therapy. Patients not willing to participate in the study were excluded.

Streptokinase (SK) was used as the thrombolytic agent. In patients with allergy or history of exposure to SK were given urokinase. SK was administered in a dose of 2,50,000 units bolus over 30 minutes, followed by infusion of 1,00,000 units/ hour over 48-72 hours depending on clinical and TTE data. Post SK infusion, unfractionated Heparin was started at a dose of 5000 IU every 6 hourly along with oral anticoagulants till target INR of 2.5-3 was achieved.

TTE was performed at onset of thrombolytic therapy and repeated every 4-6 hourly till evidence of movement of both leaflets or fall in transvalvular gradient >50%. Fluoroscopy was done post 24 hours after SK to confirm adequate leaflet movement.

Termination

Thrombolytic therapy was considered a failure when transvalvular gradient fell <50%, persistent leaflet movement abnormality or complication resulting in death of patient irrespective of valve function normalcy.

RESULTS

A total of 50 patients with a mean age of 34±14 years were included in the study, of which 22 were males (44%) and 28 were females (56%). Majority of the patients presented with signs and symptoms of heart failure. Of the 50 patients presenting with complaints of dyspnoea 27 (54%) were in NYHA 2, 19 (38%) were NYHA 3 and 4 (8%) patients were NYHA 4.

Mechanical valves were implanted in 47 patients (94%) and biological valves in 3 (6%) patients. Bileaflet valves were implanted in 43 (86%) and monoleaflet valves in 7 (14%) patients. Patient characteristics are given in Table 1.

Table 1: Patient characteristics.

Parameters	Frequency (%)
Age (mean±SD) years	34±14
Sex	
Male	22 (44)
Female	28 (56)
Duration of symptoms (weeks)	
<1	43 (86)
>1	7 (14)
NYHA	
2	27 (54)
3	19 (38)
4	4 (8)
Valve	
Biological	43 (86)
Mechanical	7 (14)

The average peak transvalvular gradient decreased from 30.5±8.9 before thrombolysis to 14.1±3.9 post thrombolysis and the mean transvalvular gradient fell from 18.9±7.1 to 8.5±3.1 as indicated in Table 2. Mechanical valves show more reduction in valvular gradients as compared to bioprosthetic valves as indicated by a steeper slope in Figure 1.

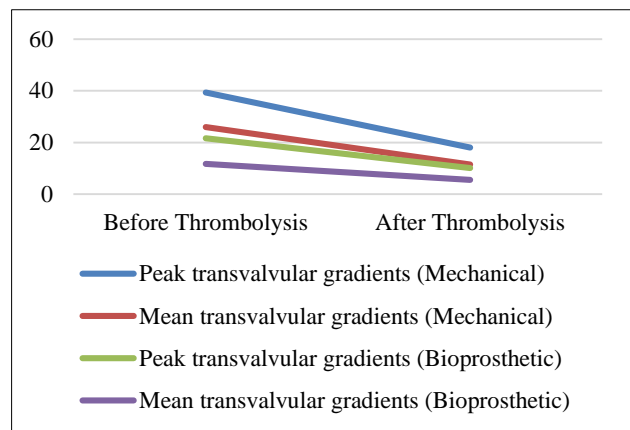


Figure 1: Reduction in peak and mean transvalvular gradients.

47 (94%) patients in the study group did not require any surgical intervention post thrombolysis and were free from major complications. 2 (4%) patients did not respond to thrombolysis and needed surgery for relief of symptoms. 1 (2%) patient developed major intracranial bleed during the treatment and died. 1 patient developed peripheral emboli (2%), 1 (2%) patient developed a transient neurological deficit and 2 (4%) patients had evidence of small subcutaneous hematomas as shown in Table 3.

Table 2: Difference in transvalvular pressure gradient before and after thrombolysis.

Variables	Before thrombolysis	After thrombolysis
Average peak transvalvular gradient	30.5±8.9	14.1±3.9
Average mean transvalvular gradient	18.9±7.1	8.5±3

Table 3: Result of thrombolysis.

Parameters	Result (%)
Success of treatment	47 (94)
Surgery	2 (4)
Complications	4 (8)
Death	1 (2)

DISCUSSION

The traditional treatment for the management of PVT has been thrombectomy or valve replacement, however, high surgical mortality continues to remain a major limitation despite recent technological advancements and myocardial protection strategies.⁸ Patil et al and Gupta et al showed that mitral valve prosthesis was most commonly involved in the patients (71.5%) compared to aortic valve prosthesis (19.6%).^{9,10}

Diagnosis is often confirmed by fluoroscopy or echocardiography. Although TTE is used for calculation of gradient and response to thrombolytic therapy, definitive diagnosis is greatly aided by TEE, particularly three-dimensional echocardiography.¹¹ Calculation of thrombus area by TEE is a predictor of embolic complications and this has now been incorporated in guidelines.¹² Multidetector computed tomography is emerging as a diagnostic modality for differentiating between pannus and thrombus.^{13,14} PVT should always be given first consideration when patients present with acute symptoms, new murmur, signs of heart failure, diminished valve sounds, and thromboembolic events.¹⁵ Factors favouring surgery include the availability of surgical know-how, calculation of surgical risk, recurrent thrombus, NYHA class IV heart failure, possible pannus, and coronary artery disease requiring adequate surgery. While factors that favour thrombolysis include lack of available surgical expertise, high surgical risk, first-time thrombosis, NYHA class ≤III heart failure, no coronary artery disease, and no pannus formation.^{16,17} Intravenous heparin is recommended in each case with thrombolytic therapy if valve thrombus persists.¹⁶

Limitations

The study lacks a comparative analysis of thrombolysis and surgery. It may also be beneficial to have a follow up

of the study participants with respect to late procedural complications, long term survival, recurrence of thrombosis and conversion to surgery. However, the authors plan to progress the study to overcome these limitations.

CONCLUSION

Prosthetic valve thrombosis is one of the most common complication following a valve replacement surgery. The patients presenting in a catastrophic manner may not be able to tolerate the complications associated with a redo surgery and hence trial of thrombolysis proves to be of utmost importance. Not only does thrombolysis prove to be better in economic aspects, but also may act as a bridging therapy towards redo surgery for valve thrombosis. Patients presenting with acute thrombosis in a mechanical bileaflet valve show better results with thrombolysis as described in our study. During thrombolysis proper vigilance is warranted as patients may develop complications like intracranial bleed, transient neurodeficit, subcutaneous hematoma.

Recommendations

TEE is a must in suspected prosthetic valve thrombosis to judge thrombus size and valve motion. Fibrinolytic therapy can be considered in a thrombosed left-sided prosthetic heart valve, which is of recent onset (<14 days) with class 1-2 symptoms, and a small thrombus (<0.8 cm²) on TEE. It is also acceptable for right sided valves. For all these a period of IV heparin is also recommended. Emergency surgery is recommended for a thrombosed left-sided prosthetic heart valve with class III–IV symptoms. Surgery is also recommended with a large thrombus (>0.8 cm²) (18). PHVT may be suspected if the Doppler-derived gradients are twice as high as empirically found in normal prostheses. For mitral prostheses, a mean gradient >6 mmHg and an effective area <1.3 cm² is suggestive of PHVT and >8 mmHg is indicative of PHVT.¹⁸ Castilho et al conducted a meta-analysis which included all studies comparing thrombolysis and surgery found that mortality was significantly lower in thrombolysis arm than surgery arm (6.6% versus 18.1%).¹⁹ Retrospective international registry including 107 patients with prosthetic heart valve thrombosis found an association between thrombus area >0.8 cm² and thrombolytic therapy failure or adverse events.¹² The European Society of Cardiology guidelines also emphasize surgery for critically ill patients and restrict thrombolysis to patients with high surgical risk and/or right-sided valve thrombosis.²⁰ In the most recent European and American guidelines, surgery is recommended for patients in NYHA functional classes III and IV unless surgery is high risk (class IIA).^{21,22} Thrombolysis is given a IIA indication in patients with right sided valve thrombosis and a class IIB indication in patients with a left-sided but small thrombus.

SK and UK have been the most used fibrinolytic agents.²³ Patients with known allergy to SK or those who have been

exposed previously to SK should be given UK. The recommended dosage of SK is a 250,000-U bolus given in 30 min, followed by an infusion of 100,000 U/h. UK is given as in pulmonary embolism: 4,400 U/kg per hour.²⁴

ACKNOWLEDGEMENTS

Authors would like to thank all the patients who willingly participated in the study and the concerned hospital for support in implementing a multidisciplinary approach.

Funding: No funding sources

Conflict of interest: None declared

Ethical approval: The study was approved by the Institutional Ethics Committee

REFERENCES

- Cannegieter SC, Rosendaal FR. Thromboembolic and bleeding complications in patients with mechanical heart valve prostheses. *Circulation*. 1994;89:635-41.
- Thorburn CW, Morgan JJ, Shanahan MX, Chang VP. Long-term results of tricuspid valve replacement and the problem of the prosthetic valve thrombosis. *Am J Cardiol*. 1983;51:1128-3.
- Roudaut R, Labbe T, Lorient-Roudaut MF, Gosse P, Baudet E, Fontan F, et al. Mechanical cardiac valve thrombosis. Is fibrinolysis justified? *Circulation*. 1992;86(5):II8-15.
- Nagy A, Denes M, Lengyel M. Predictors of the outcome of thrombolytic therapy in prosthetic mitral valve thrombosis: a study of 62 events. *J Heart Valve Dis*. 2009;18:268-75.
- Duran NE, Biteker M, Ozkan M. Treatment alternatives in mechanical valve thrombosis. *Turk Kardiyol Dern Ars*. 2008;36(6):420-5.
- Grunke-meier GL, Li HH, Naftel DC, Starr A, Rahimtoola SH. Long-term performance of heart valve prostheses. *Curr Probl Cardiol*. 2000;25(2):78-7.
- Vongpatanasin W, Hillis LD, Lange RA. Prosthetic heart valves. *N Engl J Med*. 1996;335:407-16.
- Kontos Jr GJ, Schaff HV, Orszulak TA, Puga FJ, Pluth JR, Danielson GK. Thrombotic obstruction of disc valves: clinical recognition and surgical management. *Ann Thorac Surg*. 1989;48(1):60-5.
- Patil SN, Ramalingam R, Rudrappa MMB, Manjunath CN. Study of prosthetic heart valve thrombosis and outcomes after thrombolysis. *Int J Res Med Sci*. 2019;7:1074-8.
- Gupta D, Kothari SS, Bahl VK, Goswami KC, Talwar KK, Manchanda SC, et al. Thrombolytic therapy for prosthetic valve thrombosis: short-and long-term results. *Am Heart J*. 2000;140:906-16.
- Zoghbi WA, Chambers JB, Dumesnil JG, Foster E, Gottdiener JS, Grayburn PA, et al. Recommendations for evaluation of prosthetic valves with echocardiography and Doppler ultrasound. *J Am Soc Echocardiogr*. 2009;22:975-1014.
- Tong AT, Roudaut R, Ozkan M, Sagie A, Shahid MS, Pontes Júnior SC, et al. Transesophageal echocardiography improves risk assessment of thrombolysis of prosthetic valve thrombosis: Results of the international PRO-TEE registry. *J Am Coll Cardiol*. 2004;43:77-84.
- Ueda T, Teshima H, Fukunaga S, Aoyagi S, Tanaka H. Evaluation of prosthetic valve obstruction on electrocardiographically gated multidetector row computed tomography – Identification of subprosthetic pannus in the aortic position. *Circ J*. 2013;77:418-23.
- Tanis W, Habets J, van den Brink RB, Symersky P, Budde RP, Chamuleau SA. Differentiation of thrombus from pannus as the cause of acquired mechanical prosthetic heart valve obstruction by non-invasive imaging: A review of the literature. *Eur Heart J Cardiovasc Imaging*. 2014;15:119-29.
- Kapos I, Fuchs T, Tanner FC. Case report of successful low-dose, ultra-slow infusion thrombolysis of prosthetic mitral valve thrombosis in a high-risk patient after redo-mitral valve replacement. *Eur Heart J Case Rep*. 2020;4(3):1-5.
- Dangas GD, Weitz JI, Giustino G, Makkar R, Mehran R. Prosthetic heart valve thrombosis. *J Am Coll Cardiol*. 2016;68(24):2670-89.
- Otto CM, Nishimura RA, Bonow RO, Carabello BA, Erwin JP 3rd, Gentile F, et al. 2020 ACC/AHA Guideline for the Management of Patients With Valvular Heart Disease: Executive Summary: A Report of the American College of Cardiology/American Heart Association Joint Committee on Clinical Practice Guidelines. *Circulation*. 2021;143(5):e35-71.
- Krishnan S. Prosthetic heart valve thrombosis: Diagnosis and newer thrombolytic regimens. *J Pract Cardiovasc Sci*. 2016;2:7-12.
- Castilho FM, De Sousa MR, Mendonca AL, Ribeiro AL, Cáceres-Lóriga FM. Thrombolytic therapy or surgery for valve prosthesis thrombosis: Systematic review and meta-analysis. *Thromb Haemost*. 2014;12:1218-28.
- Caceres-Loriga FM, Perez-Lopez H, Morlans-Hernandez K, Facundo-Sanchez H, Santos-Gracia J, Valiente-Mustelie J, et al. Thrombolysis as first choice therapy in prosthetic heart valve thrombosis. A study of 68 patients. *J Thromb Thrombolysis*. 2006;21(2):185-90.
- Vahanian A, Alfieri O, Andreotti F, Antunes MJ, Baron-Esquivias G, Baumgartner H, et al. Guidelines on the management of valvular heart disease (version 2012). *Eur Heart J*. 2012;33(19):2451-96.
- Nishimura RA, Otto CM, Bonow RO, Carabello BA, Erwin JP, Guyton RA, et al. 2014 AHA/ ACC guideline for the management of patients with valvular heart disease: a report of the American College of Cardiology/American Heart Association Task Force on Practice Guidelines. *J Am Coll Cardiol*. 2014;63(22):e57-85.

23. Birdi I, Angelini GD, Bryan AJ. Thrombolytic therapy for left-sided prosthetic heart valve thrombosis. *J Heart Valve Dis.* 1995;4:154-9.
24. Asante Korang A, Sreeram N, McKay R, Arnold R. Thrombolysis with tissue type plasminogen activator following cardiac surgery in children. *Int J Cardiol.* 1992;35:317-2.

Cite this article as: Potwar S, Kothari A, Potnis A, Paranjape M. Thrombolytic therapy as first line treatment in prosthetic mitral valve thrombosis. *Int Surg J* 2023;10:1019-23.