

Original Research Article

Endoscopic retrograde cholangiopancreatography in Benghazi our experience with 443 cases

Mohamed Nagi Ilbarasi*, Salem I. Abdulla Elfargani, Mohamed Ali Alhasi, Saleh Hassan Mohamed, Houda Mohamed Nagi

Department of Medicine, Benghazi University, Benghazi, Libya

Received: 02 August 2016

Revised: 03 August 2016

Accepted: 10 September 2016

***Correspondence:**

Dr. Mohamed Nagi Ilbarasi,

E-mail: mohmad5552000@yahoo.com

Copyright: © the author(s), publisher and licensee Medip Academy. This is an open-access article distributed under the terms of the Creative Commons Attribution Non-Commercial License, which permits unrestricted non-commercial use, distribution, and reproduction in any medium, provided the original work is properly cited.

ABSTRACT

Background: Endoscopic retrograde cholangiopancreatography ERCP is a procedure that combines upper gastrointestinal endoscopy and X-rays. It first came into use about 30 years ago and has been applied to the diagnosis and management of a variety of hepatobiliary and pancreatic disorders. These disorders are common in Benghazi and the procedure is frequently performed in this region. It started in Benghazi in early 1980s and became more sophisticated in 2011. The objective of this study was to assess the safety and efficacy of ERCP in Benghazi and to evaluate its morbidity and mortality in compare to that present in the literature.

Methods: A retrospective study of the medical records of 443 patients underwent ERCP in the two main hospitals in Benghazi (Benghazi medical center and Alhawari general hospital).

Results: The total numbers of cases were 443 patients and the procedures were done 512 times (it is repeated in some cases), the morbidity and mortality rates were compared with other studies.

Conclusions: Currently, our experience with ERCP in Benghazi is within acceptable range and the morbidity and mortality rates are almost with the average present in the literature.

Keywords: ERCP, Post-ERCP complications

INTRODUCTION

Endoscopic retrograde cholangiopancreatography ERCP is a procedure that combines upper gastrointestinal endoscopy and X-ray images. Since its introduction in 1968. It became a commonly performed endoscopic procedure.¹ The diagnostic and therapeutic utility of ERCP has been well demonstrated for a variety of disorders, including the management of choledocholithiasis, the diagnosis and management of biliary and pancreatic disease and the postoperative management of biliary perioperative complications.²⁻⁴ Worthwhile these disorders are common in Benghazi.

The evolution of the role of ERCP has occurred simultaneously with that of other diagnostic and therapeutic modalities, most notably magnetic resonance imaging, MRCP and laparoscopic surgery. It was available in Benghazi in 1980s as a diagnostic procedure which is not last for long time. It restarted in 2011 in Jamhouria Hospital then moved to Benghazi medical center and finally started in Alhawari general hospital in December 2012.

The objective of this study was to assess the safety and efficacy of ERCP in Benghazi and to compare it with the standard in the literature.

METHODS

Retrospective study of the medical records of 443 patients underwent ERCP in the two main hospitals in Benghazi, Benghazi medical center (high volume endoscopist) and Alhawari general hospital (low volume endoscopist) (Figure 1) over a 3 years period (2011-2013). Data on ERCP morbidity and mortality were studied and analyzed in compare to that present in the literature.

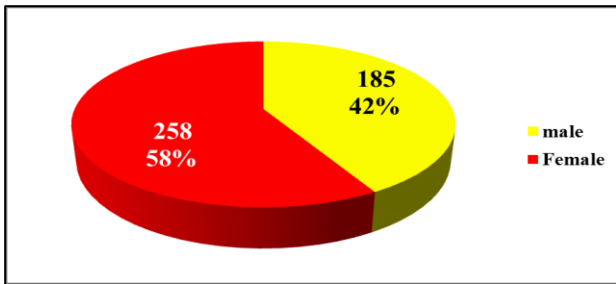


Figure 1: Total number of patients 443.

RESULTS

The total number of cases were 443 patients and total number of procedures were 530 (in some patients the procedures were repeated more than one time) there were 258 females and 185 males (Figure 1). The indications for ERCP were stone in CBD, obstructive jaundice, Stent removal and others (Figure 2).

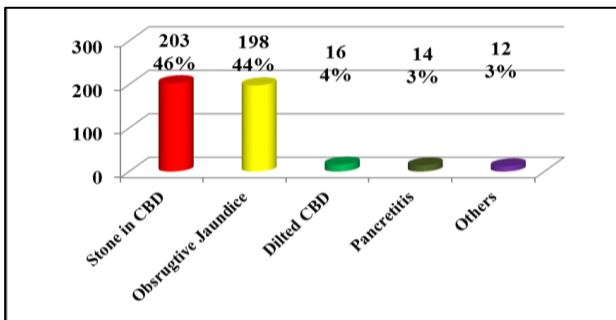


Figure 2: Indications of ERCP.

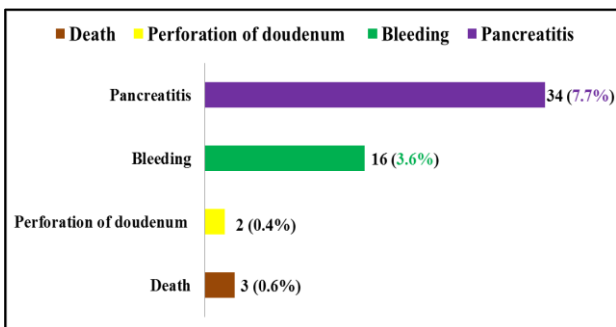


Figure 3: Post-ERCP morbidity (52 case 11.7%) and mortality (3 cases 0.6%).

Most patients received sedation during the procedure, majority Midazolam and pethidine. Three patients received GA. Morbidities in 52 cases (11.7%) and mortalities 3 cases (0.6%) (Figure 3).

DISCUSSION

ERCP is one of the most technically demanding and high risk procedures performed by gastrointestinal endoscopists.^{5,6} It requires significant focused training and experience to maximize success and to minimize poor outcomes.^{7,8} Since it is availability in Benghazi in 1980s it was performed for many cases, and it was a good step in the health serves in this region. It is a new modality for the management of hepatobiliary and pancreatic diseases which are a common disease in our country, therefore in our study, choledocholithiasis were the most common indication for ERCP. The procedure becomes more benefit for patients after the availability of laparoscopic surgery in 1998 in Benghazi. Although ERCP is a valuable therapeutic modality in choledocholithiasis, it is still an invasive technique with relatively high rate of serious complications as mentioned in our study as well as in the literature. Because of this relatively significant rates of morbidity and mortality, the risk of the procedure should be explain to the patient and weight the risk and the benefit of the procedure in each individual patient. One of the most common and significant complication is pancreatitis which is known as post-ERCP pancreatitis PEP. In our study it was one of the most common complication in our patients (7,7 %) (34 case) and most of the cases the PEP were mild to moderate according to Ranson's criteria. The incidence of PEP in a meta-analysis of 21 prospective studies was approximately 3.5% - 18% but ranges widely (1.6%-15.7%) depending on patient selection.^{9,10} It is with a higher incidence in those undergoing complex endotherapy. Worthwhile it is not known if a relationship exists between the severity of PEP and the technical complexity of the procedure.¹¹ In our study this complication become more common in the last years and this is strongly related to the drastic change of the use of ERCP as a therapeutic procedure rather than a diagnostic one. Meanwhile the development of less invasiveness diagnostic imaging technology by the use of MRCP and advanced ultrasound machines like endoscopic ultrasonography clearly visualizes the entire extra hepatic biliary tree and avoids the need for ERCP as a diagnostic method in many patients with hepatobiliary and pancreatic pathology.⁴ Many studies agreed that MRCP are the procedure of choice for the diagnosis of hepatobiliary and pancreatic disorders.¹²⁻¹⁵ Recently the use of rectal indomethacin or oral antacid to prevent PEP were mentioned in the literature and this is should be considered in our future procedures.^{1,6,16,17} Upper gastrointestinal bleeding were the second most common complication 3.6% (16 cases), however hemorrhage is basically a complication related to sphincterotomy rather than diagnostic ERCP. The severities of bleeding in most of the cases were mild to moderate and in two cases there

were massive bleeding. One case controlled with conservative treatment and the other case developed irreversible shock and patient passed away despite of aggressive treatment and it was included in the mortality rate of our study. These patients were under antiplatelet treatment. Worthwhile ERCP with sphincterotomy is considered a higher risk procedure for bleeding, and antithrombotic therapy should be adjusted very carefully according to published in the literatures to avoid massive bleeding.¹⁸ The other serious complication which is found in our study is duodenal perforation. As mentioned in many study the perforation rates with ERCP range from 0.1% to 0.6%, in our study it was 0.4 % (2 cases).^{15,19-22} One of our patients who sustained duodenal perforation developed septicemia and passed away despite of extensive medical and surgical treatment. This complication considered as fetal complication because it is difficult to recognition and late diagnosis. Since death may occur from any of the complications described previously, the mortality rate must be considered in the light of the underlying indication for ERCP and patient comorbidity. The presence of cardiopulmonary problems may arises the mortality rate.²³ This group of patients considered high risk patients and this risk is added to the risk of the procedure itself . The last patients were passed away because he was a cardiac case, developed cardiac arrest during the procedure and expired immediately. In our study the mortality rates were 0.6% (3 cases) and this is with average present in the literature (figure 4). The overall mortality rate after diagnostic ERCP is approximately 0.2%.²⁰ Death rates after therapeutic ERCP are twice as high 0.4% - 0.5% in 2 large prospective studies.^{19,20} In conclusion ERCP is a procedure with considerable risk of morbidity and mortality which are related to patient age and comorbidity, as well as the type of intervention and more importantly the endoscopists experience.

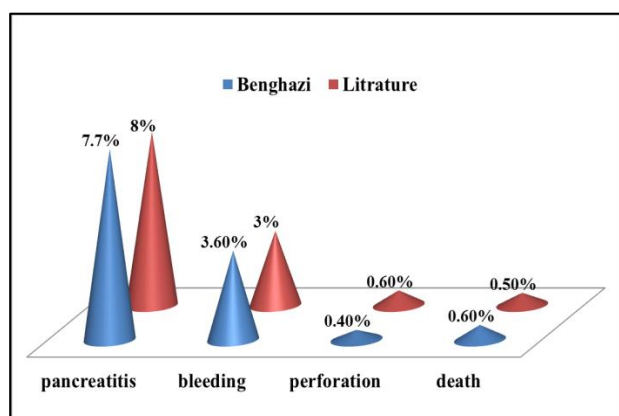


Figure 4: Comparison of morbidity and mortality rates in Benghazi and literature.

CONCLUSION

ERCP with endoscopic sphincterotomy is a valuable therapeutic modality in choledocholithiasis and other

hepatobiliary disorders despite of it is invasiveness which is related to therapeutic part of the procedure. With newer diagnostic imaging technologies, ERCP is evolving into a predominantly therapeutic procedure. Endoscopists performing ERCP should have appropriate training and expertise before performing advanced procedures. Cholecystolithiasis and choledocholithiasis as well as other hepatobiliary and pancreatic diseases are common disorders in Benghazi. ERCP is a frequent and very helpful procedure in this area. It is considered an important tool in the management of patients with these disorders. In our study, ERCP had acceptable results and the mortality and morbidity rates were in the average that present in the literature.

Funding: No funding sources

Conflict of interest: None declared

Ethical approval: The study was approved by the institutional ethics committee

REFERENCES

1. Elmunzer BJ, Scheiman JM, Lehman GA, Chak A, Mosier P, Higgins PDR, et al. A randomized trial of rectal indomethacin to prevent post-ERCP pancreatitis . *N Engl J Med.* 2012;366:1414-22.
2. Hamilton I, Bradley P, Lintott DJ, McMahon MJ, Axon ATR. Endoscopic retrograde cholangiopancreatography in the investigation and management of patients after acute pancreatitis. *BJGE.* 2005;504-6.
3. Mortensen J, Kruse A. Endoscopic management of postoperative bile leaks. *BJGE.* 2005;1339-41.
4. Norton SA, Alderson D. Prospective comparison of endoscopic ultrasonography and endoscopic retrograde cholangiopancreatography in the detection of bile duct stones. *BJGE.* 2005;1366-9.
5. Adler DG, Lieb JG, Cohen J. Quality indicators for ERCP. *American J Gastroenterol.* 2015;110:91-101.
6. Colton JB, Curran CC. Quality indicators, including complications, of ERCP in a community setting: a prospective study. *Gastrointest Endosc.* 2009;70:457-67.
7. Cotton PB. Affiliation: digestive disease center, medical University of South Carolina, Charleston, 29425, USA. Evaluating ERCP is important but difficult. *Gut.* 2002;51(2):287-9.
8. Testoni PA, Mariani A, Giussani A. Risk factors for post-ERCP pancreatitis in high- and low-volume centers and among expert and non-expert operators: a prospective multicenter study. *American J Gastroenterol.* 2010;105:1753-61.
9. Cotton PB, Garrow DA, Gallagher J, Romagnuolo J. Risk factors for complications after ERCP: a multivariate analysis of 11,497 procedures over 12 years. *Gastrointest Endosc.* 2009;70:80-8.
10. Barthet M, Lesavre N, Desjeux A. Complications of endoscopic sphincterotomy: results from a single tertiary referral center. *Endoscopy.* 2002;34:991-7.

11. Trevino J, Wilcox CM, Phadnis M. Relationship between severity of pancreatitis and complexity of ERCP. *American J Gastroenterol.* 2010;105:1753-61.
12. Glomsaker T, Hoff G, Kvaløy JT. Patterns and predictive factors of complications after endoscopic retrograde cholangiopancreatography. *BJGE.* 2012;373-80.
13. Musella M, Barbalace G, Capparelli G. Magnetic resonance imaging in evaluation of the common bile duct. *BJBE.* 2003;16-9.
14. Jenkins JT, Glass G, Ballantyne S, Fullarton GM. Effect of MRCP introduction on ERCP practice: are there implications for service and training? *Gut.* 2006;55(9):1365-6.
15. Moon JH, Cho YD, Cha SW. The detection of bile duct stones in suspected biliary pancreatitis: comparison of MRCP, ERCP, and Intraductal US detection of bile duct stones in biliary pancreatitis. *American J Gastroenterol.* 2005;100:1051-7.
16. Nagar AB. Affiliation: VA Connecticut Healthcare System, Yale University, Building 4, 950 Campbell Ave, West Haven, CT 06516, USA. F Gorelick. Prevention of post-ERCP pancreatitis: a little antacid might go a long way. *Gut.* 2008;57(11):1492-3.
17. Sotoudehmanesh R, Khatibian M, Kolahdoozan S. Indomethacin may reduce the incidence and severity of acute pancreatitis after ERCP. *American J Gastroenterol.* 2007;102:978-83.
18. Wang P, Shen Li Z, Liu F. Risk factors for ERCP-related complications: prospective multicenter study risk factors for ERCP-related complications. *American J Gastroenterol.* 2009;104:31-40.
19. Freeman ML, Nelson DB, Sherman S. Complications of endoscopic biliary sphincterotomy. *N Engl J Med.* 1996;335:909-18.
20. Loperfido S, Angelini G, Benedetti G. Major early complications from diagnostic and therapeutic ERCP: a prospective multicenter study. *Gastrointest Endosc.* 1998;48:1-10.
21. Masci E, Toti G, Mariani A. Complications of diagnostic and therapeutic ERCP: a prospective multicenter study. *Am J Gastroenterol.* 2001;23-28.
22. Howard TJ, Tan T, Lehman GA. Classification and management of perforations complicating endoscopic sphincterotomy. *Surgery.* 1999;126:658-63.
23. Andriulli A, Loperfido S, Napolitano G. Incidence rates of post-ERCP complications: a systematic survey of prospective studies. *Am J Gastroenterol.* 2007;102:1781-8.

Cite this article as: Ilbarasi MN, Abdulla Elfargani SI, Alhasi MA, Mohamed SH, Nagi HM. Endoscopic retrograde cholangiopancreatography in Benghazi our experience with 443 cases. *Int Surg J* 2016;3:1787-90.