

## Case Report

# Eating styrofoam balls presented as intestinal obstruction- PICA associated with bezoar: a rare case report and review of literature

Altaf G. Haji<sup>1\*</sup>, Naveen Sivakumar<sup>1</sup>, Bala Piramanayagam<sup>1</sup>, A. Palit<sup>2</sup>

<sup>1</sup>Department of Surgery, <sup>2</sup>Department of Radiology, George Elliot NHS Hospital, England

**Received:** 01 November 2022

**Revised:** 13 November 2022

**Accepted:** 15 November 2022

### \*Correspondence:

Altaf G. Haji,

E-mail: [altaf.haji2@nhs.net](mailto:altaf.haji2@nhs.net)

**Copyright:** © the author(s), publisher and licensee Medip Academy. This is an open-access article distributed under the terms of the Creative Commons Attribution Non-Commercial License, which permits unrestricted non-commercial use, distribution, and reproduction in any medium, provided the original work is properly cited.

## ABSTRACT

Gastrointestinal obstruction secondary to foreign body bezoars (industrial materials, plastic, tissue paper, sponge) have been reported but foreign body bezoar with styrofoam has never been reported in literature. PICA associated bezoars are an unusual complication and reports say that a wide variety of substances are consumed, ranging from socks, newspapers, and sofa pillows to dirt and hair and in this case, it was ingestion of styrofoam balls. Styrofoam being foam plastic does not breakdown or get absorbed in body when ingested, but its persistent ingestion creates bezoar which can fill the whole gastrointestinal tract.

**Keywords:** Styrofoam, Bezoar, Obstruction

## INTRODUCTION

A gastrointestinal bezoar is defined as an indigestible conglomeration of foreign material (food, hair, seeds, or another ingested substance) located in the gastrointestinal tract. Bezoars are classified according to the component material: phytobezoars (indigestible vegetable fibre), trichobezoars (ingested hair), lactobezoars (milk protein and mucus), lithobezoars, and pharmacobezoars (medications that have not dissolved).<sup>1,2</sup> On the other hand, PICA is an eating disorder where a person compulsively eats things that aren't food and don't have any nutritional value or purpose.

## CASE REPORT

An 83-year-old caucasian female presented to our acute surgical take with a 3-days history of classical acute gastrointestinal obstruction, comprising of worsening abdominal distension, abdominal pain, and vomiting. Her past medical history comprised of Alzheimer's/dementia,

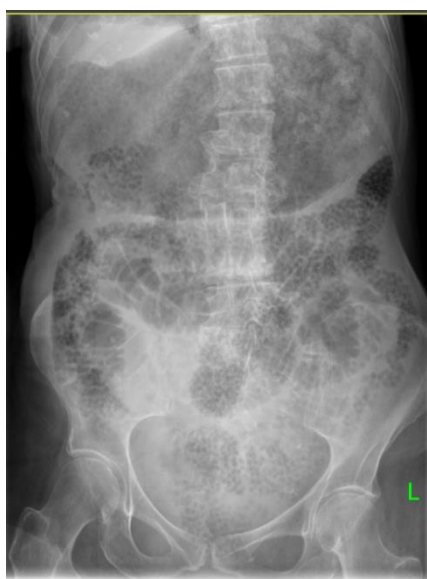hyperlipemia, hypertension, central retinal vein occlusion, previous left sided pleural effusion, and consolidation. She was living alone with a package of care. Her family reported that there was evidence of half-eaten and missing styrofoam packaging balls and thus even raised safeguarding concerns.

On clinical examination she was hemodynamically stable. Her abdomen was grossly distended on examination and was tender all over. Bowel sounds were audible, PR examination showed loose stool in the rectum with visible evidence of styrofoam beads.

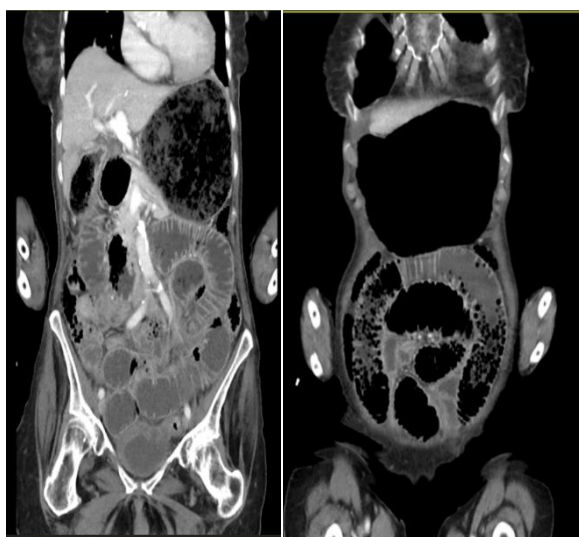
Her blood results showed elevated white cells (WCC), neutrophils and CRP. Her WCC was  $13.22 \times 10^9/l$ , her neutrophils were  $10.56 \times 10^9/l$  and her CRP was 26. An abdominal X-ray was performed by the emergency department as well as a CT of the abdomen and pelvis; both of which revealed grossly dilated stomach and small bowel loops packed with Styrofoam beads, suggestive of obstruction.

She was admitted and managed non-operatively with fluid resuscitation, pain control, bowel rest with nasogastric tube decompression and serial abdominal exams. She started opening her bowels, but nasogastric tube decompression was continued due to persistent vomiting and non-resolving abdominal distention. Given her multiple co-morbidities and poor physiological reserve, the decision was made to manage her conservatively. Unfortunately, the ward staff caught the patient on one occasion re-ingesting styrofoam directly from her passed stool. Three days later she had cardiac arrest. CPR and resuscitative measures were initiated but she could not be revived. It seems she had aspirated.

Foreign body bezoar with styrofoam has never been reported in literature and to best of our knowledge, this is first reported case of 'styrofoam bezoar' presentation.



**Figure 1: X-ray abdomen.**



**Figure 2: CT image.**

## DISCUSSION

Styrofoam is an expanded polystyrene (EPS) composed of about 5% polystyrene (PS) and 95% air. It is used for insulation, packaging and manufacturing of food containers like cups, plates.<sup>3</sup> Thousands of small units of styrene, called monomers, link together to form large molecules of polystyrene by a process called polymerization. It starts as small spherical beads with a typical diameter of 0.5-1.5 mm. Potential toxicity of polystyrene microplastic particles have been studied mostly in animal models and marine life and it has been established that polystyrene microparticles induces a significant reduction in the richness and diversity of the gut bacterial microbiota.<sup>4</sup>

Bezoars are seen very infrequently with an incidence of less than 1% in the general population and are rare causes of gastrointestinal obstruction.<sup>5</sup> Bezoars are an unusual complication of pica, but when they occur, they can be devastating, resulting in a 30% mortality rate if untreated. Pica has been linked to both iron and zinc deficiencies, as well as to psychological disturbance.<sup>6</sup> The term Pica is derived from the Latin word for magpie, a bird known for its no discriminating appetite. A wide variety of substances are consumed, ranging from socks, newspapers, and sofa pillows to dirt and hair and in this case styrofoam.

Physicians should keep bezoars in mind as they can be diagnostic challenge in cases of unexplained abdominal symptoms, especially in females and patients with psychiatric disorders, nursing home residents with dementia or patients with neurological disorders. It has been reported that patients with gastroparesis may also be susceptible to gastric outlet syndrome if they develop a phytobezoar.<sup>7</sup>

Bezoars are usually located in the stomach, followed by the intestines as the second most frequent localization. It has been seen that any condition which decreases motility of gastrointestinal tract or causes stricturing of bowel can predispose/precipitate the obstruction due to any kind of bezoar. Most commonly reported conditions are seen in patients with previous gastric surgeries or bowel resections, history of peptic ulcer disease or conditions causing like Crohn's disease, radiation enteropathy, diaphragm disease due to NSAID abuse, carcinoma of the gastrointestinal tract, chronic dehydration, hypothyroidism, diabetes, and in some cases, connective tissue-related disorders.<sup>7</sup>

Phytobezoars are the most common types of bezoar but phytobezoar-induced small bowel obstruction is a rare clinical situation, accounting for less than 5% of all mechanical intestinal obstructions.<sup>8</sup>

Bezoars are readily diagnosed by X-ray abdomen, ultrasound, or computed tomography, and can also be recognized at endoscopy.<sup>9</sup>

Radiographically, styrofoam bezoar, like phytobezoars, are well-circumscribed intraluminal masses that have a heterogeneous appearance, often with a mottled, air-bubble pattern and an absence of mesenteric fat stranding.<sup>10</sup> This appearance is because Styrofoam is composed of about 5% polystyrene (PS) and 95% air. A recent study of bezoars in China by Kuang et al examined risk factors for small bowel obstruction caused by bezoars and found that major diameter measured on CT scans was a significant independent predictor.<sup>11</sup> In general, bezoars most commonly occur in the distal small intestine but in this case whole GI tract was packed with styrofoam beads.

Diagnosis of bezoar is often delayed, but once established, there are several treatment options available. Medically, treatment with prokinetic agents is often sufficient. If the lesion is confined to the stomach or duodenum or to colon, endoscopic/colonoscopic decompression/fragmentation with forceps or snares can be employed to diagnose and deconstruct the bezoar with a goal of alleviating the bowel obstruction.<sup>12</sup> Additionally, for gastric bezoars, Coca-Cola has been shown to be an effective dissolution agent.<sup>13</sup> For those with failure to progress or worsening clinical symptoms, surgery is the gold standard method to relieve obstruction and avoid complications. Intra-operatively, the bezoar may be fragmented and 'milked' to the cecum or resected via enterotomy.

## CONCLUSION

Styrofoam being 'foam plastic' does not breakdown or get absorbed in body when ingested and its persistent ingestion creates bezoar which can fill the whole gastrointestinal tract and cause gastro intestinal obstruction. Radiographically, styrofoam bezoar appear as masses with a mottled, air-bubble pattern. It can be diagnostic challenge, especially in females and patients with psychiatric disorders, nursing home residents with dementia or patients with neurological disorders and raises safeguarding issues for family members/carers.

*Funding: No funding sources*

*Conflict of interest: None declared*

*Ethical approval: Not required*

## REFERENCES

- Iwamuro M, Okada H, Matsueda K, Inaba T, Kusumoto C, Imagawa A, et al. Review of the diagnosis and management of gastrointestinal bezoars. *World J Gastrointest Endosc.* 2015;7(4):336-45.
- Yau KK, Siu WT, Law BK, Cheung HY, Ha JP, Li MK. Laparoscopic approach compared with conventional open approach for bezoar-induced small-bowel obstruction. *Arch Surg.* 2005;140(10):972-5.
- Saima QM, Bhanger MI, Hasany SM, Khuhawar MY. Sorption behavior of impregnated styrofoam for the removal of Cd(II) ions. *Colloid Surf A.* 2006;279(1-3):142-8.
- Usman S, Razis AFA, Shaari K, Azmai MNA, Saad MZ, Isa NM. Polystyrene microplastics induce gut microbiome and metabolome changes in Javanese medaka fish (*Oryzias javanicus* Bleeker, 1854). *Toxicol Rep.* 2022;9:1369-79.
- Park SE, Ahn JY, Jung HY, Na S, Park SJ, Lim H, et al. Clinical outcomes associated with treatment modalities for gastrointestinal bezoars. *Gut Liver.* 2014;8(4):400-7.
- Tay YK, Levy ML, Metry DW. Trichotillomania in childhood: case series and review. *Pediatrics.* 2004;113(5):e494-8.
- Dhakar OP, Dhakar M, Bhandari D. Phytobezoar leading to gastric outlet obstruction in a patient with diabetes. *BMJ Case Rep.* 2014;2014:bcr2013200661.
- Pujar KA, Pai AS, Hiremath VB. Phytobezoar: a rare cause of small bowel obstruction. *J Clin Diagn Res.* 2013;7(10):2298-9.
- Gayer G, Jonas T, Apter S, Zissin R, Katz M, Katz R, et al. Bezoars in the stomach and small bowel--CT appearance. *Clin Radiol.* 1999;54(4):228-32.
- Chen YC, Liu CH, Hsu HH, Yu CY, Wang HH, Fan HL, et al. Imaging differentiation of phytobezoar and small-bowel faeces: CT characteristics with quantitative analysis in patients with small-bowel obstruction. *Eur Radiol.* 2015;25(4):922-31.
- Kuang LQ, Zhao DW, Cheng C, Wang Y. Prediction of Small Bowel Obstruction Caused by Bezoars Using Risk Factor Categories on Multidetector Computed Tomographic Findings. *Biomed Res Int.* 2016;2016:6569103.
- Ted XG, Richard E, Jared R. S2257 Colonoscopic Decompression of a Bezoar-Induced Small Bowel Obstruction. *American J Gastroenterol.* 2021;116:S963.
- Ladas SD, Kamberoglou D, Karamanolis G, Vlachogiannakos J, Zouboulis-Vafiadis I. Systematic review: Coca-Cola can effectively dissolve gastric phytobezoars as a first-line treatment. *Aliment Pharmacol Ther.* 2013;37(2):169-73.

**Cite this article as:** Haji AG, Sivakumar N, Piramanayagam B, Palit A. Eating styrofoam balls presented as intestinal obstruction- PICA associated with bezoar: a rare case report and review of literature. *Int Surg J* 2022;9:2034-6.