

Case Report

Multidisciplinary management of gastrocolic fistula post ingestion of multiple magnetic beads: a case report

Niraj Bhusakhare^{1*}, Arpan Jain², Nitin Sharma³, Vinod Singh¹, Sanjay Goyal⁴,
Jogesh C. Marhual¹, Samir Kathale⁵

¹Department of General Surgery, ²Department of Gastroenterology, ³Department of Pediatric Surgery, ⁴Department of Anesthesia, ⁵Department of Radiology, Sparsh Multispeciality Hospital NABH Certified, Bhilai, Chhattisgarh, India

Received: 27 September 2022

Accepted: 17 October 2022

*Correspondence:

Dr. Niraj Bhusakhare,

E-mail: dr.bond303@gmail.com

Copyright: © the author(s), publisher and licensee Medip Academy. This is an open-access article distributed under the terms of the Creative Commons Attribution Non-Commercial License, which permits unrestricted non-commercial use, distribution, and reproduction in any medium, provided the original work is properly cited.

ABSTRACT

Foreign body ingestion is quite common in pediatric population, and these cases are usually difficult to manage due to delay in diagnosis. Ingestion of multiple magnetic foreign bodies together is very dangerous and can lead to serious complications like bowel obstruction, fistula and even death. Urgent endoscopic retrieval followed by surgical exploration, if required remains the best approach for removing multiple ingested magnets, thus preventing further injury to the gastrointestinal tract. We report a case of a 2-year-old child who developed a gastrocolic fistula following the ingestion of multiple magnetic beads, which remained undiagnosed weeks after ingestion. Most of the magnetic beads were successfully retrieved endoscopically, however a few remained despite extensive search. Hence the patient underwent emergency laparotomy which showed a gastrocolic fistula, was subsequently repaired after removal of remaining magnetic beads remaining magnetic beads from the colon.

Keywords: Magnetic, Foreign body, Fistula

INTRODUCTION

In children, especially those aged 6 months to 3 years, foreign body ingestion is common and is a serious health problem. In majority of cases, it is unintentional. Ingestion of multiple magnets in children is very rare. Children may be attracted to a variety of foreign bodies such as coins, toys, jewellery, magnets, and batteries. In cases where older children are involved it could be with psychological conditions such as autism, attention-deficit hyperactivity disorder and psychosis.^{1,2}

Ingestion of magnets and button batteries foreign bodies can have significant morbidity and mortality. The frequency of foreign body ingestion is rising these days. Majority of ingested foreign bodies leave gastrointestinal tract naturally without need of any intervention and a wait and watch approach is generally indicated at least initially or till the patient develops any ominous symptoms.

However, ingestion of multiple magnets or a magnet with a ferromagnetic substance poses a unique set of possible complications that may require a different approach to manage such patients.³

After swallowing more than one magnet the magnetic force allows the objects in the intestine to find each other despite being at different regions in the bowel.⁴ The magnets can therefore cause two regions of bowel to adhere together with great strength and do not separate. The resulting ischemia and pressure necrosis can cause bowel perforations, volvulus and fistulas.^{5,6}

CASE REPORT

A 2-year-old male child presented to the outpatient department (OPD) with a 5-month history of abdominal pain and constipation. His symptoms persisted despite receiving medications at a primary healthcare facility. His

oral intake was good, no dysphagia, no vomiting was reported. He had no history of fever, upper respiratory tract symptoms, chest pain, surgeries, or allergies. There was no history of any developmental delay.

On examination

He was fully alert, oriented with no signs of dehydration. His vitals were stable. Per abdomen examination showed soft abdomen with mild tenderness over epigastric and umbilical region with no obvious guarding or rigidity.

Multidisciplinary management

Radiology

X-ray abdomen at admission showed multiple magnetic beads in a garland pattern over left upper quadrant of abdomen (Figure 1a). Computed tomography (CT) abdomen also showed magnetic beads in similar fashion, probably near posterior wall of antrum in the stomach (Figure 1b). Their ingestion was not witnessed by parents.

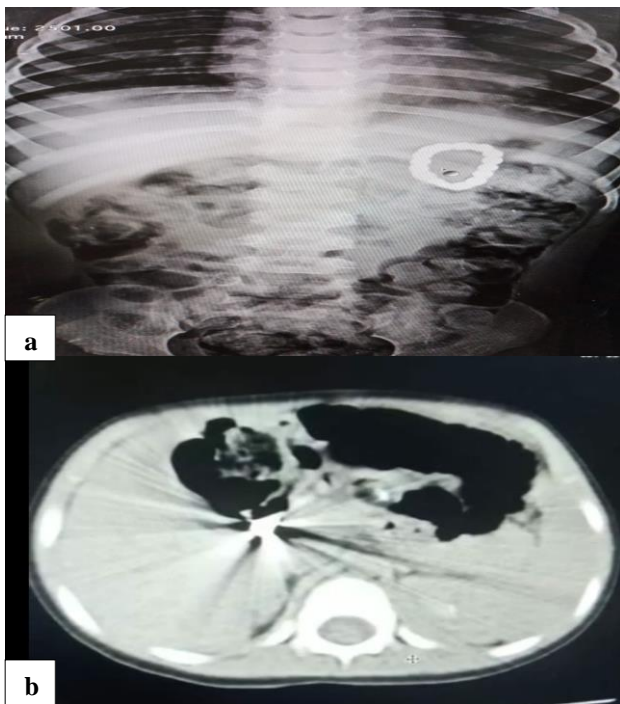


Figure 1: (a) X-ray showing a chain of 18 magnetic beads forming a ring left side of abdomen; and (b) CT scan showing multiple magnetic beads in shape of ring near the posterior wall of stomach suspected gastrocolic fistula.

Endoscopy

An urgent upper gastrointestinal (GI) endoscopy was performed during which multiple magnets were found embedded within the posterior wall of the antrum of stomach and surrounded by ulcerations, from which 14 magnetic beads retrieved (Figure 2a). Remaining 4

magnetic beads are present into gastrocolic fistula for which patient was taken up for an emergency laparotomy. His pre-operative laboratory tests included a complete blood count. Coagulation and biochemical profiles were within normal ranges.

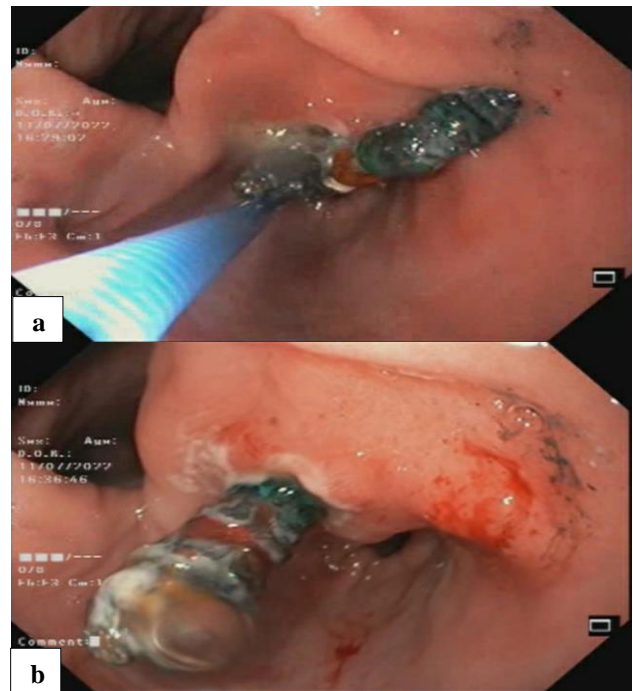


Figure 2: (a) Endoscopic view of a magnetic bead within the posterior wall of antrum of stomach; and (b) endoscopic view of some magnetic beads embedded within the gastric mucosa.

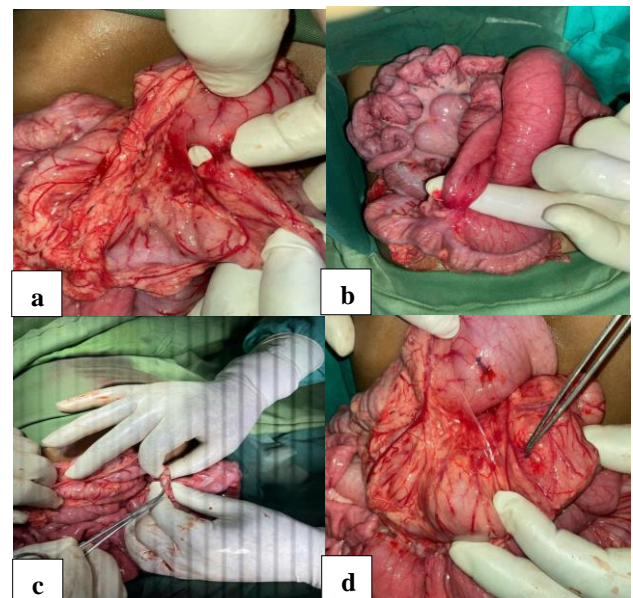


Figure 3: (a) Well defined gastrocolic fistula between stomach and transverse colon; (b) adherent ileal loop with proximal dilatation and collapse of distal bowel loops; (c) retrieved 4 magnetic beads from transverse colon; and (d) primary repair of either side.

Surgical

The posterior wall of antrum of the stomach was found adherent to the transverse colon, forming a gastrocolic fistula. The magnets were present within the fistula and transverse colon. Only 4 beads were removed via the colonic opening after the fistula was divided. The magnetic beads were round in shape, each measuring about 4 mm in diameter. The fistula was repaired on either side by primary closure.

The child was stable following surgery. The nasogastric tube was removed, and oral feeding was started on the third postoperative day which he tolerated without any pain or vomiting. On the fifth postoperative day, the child was discharged in a healthy state with his happy parents.

DISCUSSION

In children, foreign body ingestion is very common and major health problem. These cases are difficult to diagnose and manage. Annual Incidence is approximately 100,000 cases, resulting in an annual mortality of approximately 1500.¹⁻³ Younger children are especially susceptible because of their natural curiosity and oral mode of exploration. Most ingested objects are harmless when they are small and blunt, and they can be spontaneously evacuated from the GI tract. However, morbidity and mortality in these cases are influenced by several factors such as the type of the foreign body, its physical size, shape, the presence of toxic components, and the site of lodgment within the GI tract.²

Ingestion of multiple magnets in children is a rare entity. Solitary magnets can pass the GI tract without any complications without any intervention usually and require only serial radiographic monitoring. Multiple magnets have a high chance of causing bowel complications such as obstruction, perforations and fistulas.⁷

Swallowed magnets have a wide spectrum of clinical presentations that are most apparent within a week of ingestion, however, the presentation can be weeks to months later. These cases can present with a sore throat, vomiting, constipation, abdominal pain, and even peritonitis. Ingestion of multiple magnets can have a complicated course with overt symptoms, even without evident peritoneal signs. Pressure necrosis with subsequent perforation, small bowel obstruction, volvulus, or fistula formation can occur. Thus, at least half of the patients who have ingested multiple magnets require surgical intervention.

About 80% of the cases of foreign body ingestion can be diagnosed using plain radiography. X-rays can identify foreign bodies in most cases and can also determine the size, shape, and relationship between the foreign body and surrounding structures. However, plastic objects and most fish bones are radiolucent, and diagnosis can be challenging.⁸

Magnetic beads can sometimes be mistaken for a single chain of beads or a bracelet, and the plurality of magnetic objects sometimes cannot be precisely determined using plain radiography or computed tomography. In addition, intra-operative fluoroscopy is vital for confirming the complete extraction of foreign bodies and to localize them when they are difficult to palpate.⁹

The management of ingested magnets is not standardized, and several protocols have been described in the literature. When a single magnet of less than 5 cm in size and has blunt edges is ingested without any other metallic objects or signs of peritoneal irritation, observation is universally accepted. However, when multiple magnets are ingested, several approaches have been proposed. When magnets are located within the prepyloric part of the GI tract, retrieval by endoscopy is recommended. In contrast, to prevent further damage to the bowel, surgical intervention by laparoscopy or laparotomy is advised when multiple magnets are found beyond the pylorus.¹⁰

Tsai et al reported five cases of multiple magnet ingestion, each presenting with non-bilious vomiting and abdominal pain. All patients were initially evaluated using repeated X-rays followed by surgical exploration. Complications, including pressure necrosis, perforation, fistula formation, and bowel obstruction, occurred in four of these cases. In one, repeated imaging showed migration of the magnets to the bowel without symptoms or complications upon exploration, suggesting that asymptomatic children can be closely followed using serial X-rays to monitor the foreign body progression. Early surgical consultation remains imperative when multiple magnets have been ingested, particularly when more than 12 hours have elapsed. Nevertheless, endoscopic management of complicated cases has been described in the literature.¹¹

Phen et al reported a case of multiple magnet ingestion in a 19-month-old child complicated by a gastroduodenal fistula. It was successfully resolved by endoscopic removal and supportive care, avoiding the need for surgical intervention.¹²

In our case, endoscopy was performed which retrieved 14 magnetic beads out of 18 magnetic beads necessitating surgical intervention for complete removal and repair of the gastrocolic fistula. Careful tissue handling during surgery and cautious retrieval of the magnetic objects is crucial to avoid multiple enterotomies, further morbidity, and lengthening the hospital stay, noting that magnets can easily migrate and adopt various shapes.

CONCLUSION

Paediatric foreign body ingestion can present atypically and pose a diagnostic and management dilemma. Therefore, physicians should maintain a high index of suspicion in such cases, especially in young children in whom unintentional ingestion is common. When multiple magnets have been ingested, early surgical intervention is

crucial if endoscopy alone does not allow sufficient resolution, and a meticulous surgical technique with radiographic imaging is required for safe retrieval of the magnetic objects and thus preventing their further migration and unwanted complications including death.

Funding: No funding sources

Conflict of interest: None declared

Ethical approval: Not required

REFERENCES

1. Kramer RE, Lerner DG, Lin T. Management of ingested foreign bodies in children: a clinical report of the NASPGHAN Endoscopy Committee. *J Pediatr Gastroenterol Nutr.* 2015;60:562-74.
2. Chen MK, Beierle EA: Gastrointestinal foreign bodies. *Pediatr Ann.* 2001;30:736-42.
3. Abbas MI, Oliva-Hemker M, Choi J. Magnet ingestions in children presenting to US Emergency Departments, 2002-2011. *J Pediatr Gastroenterol Nutr.* 2013;57:18-22.
4. Oestreich AE. Danger of multiple magnets beyond the stomach in children. *J Natl Med Assoc.* 2006;98:277-9.
5. Hernandez AE, Gutierrez SRC, Barrios JE. Intestinal perforation caused by magnetic toys. *J Pediatr Surg.* 2007;42:13-6.
6. Tay ET, Weinberg G, Levin TL. Ingested magnets: the force within. *Pediatr Emerg Care.* 2004;20(13):466-7.
7. Centers for Disease Control and Prevention (CDC). Gastrointestinal injuries from magnet ingestion in children - United States, 2003-2006. *MMWR Morb Mortal Wkly Rep.* 2006;55:1296-300.
8. Waters AM, Teitelbaum DH, Thorne V, Bousvaros A, Noel RA, Beierle EA. Surgical management and morbidity of pediatric magnet ingestions. *J Surg Res.* 2015;199:137-40.
9. August A, Mueller C. Early recognition is important when multiple magnets masquerade as a single chain after foreign body ingestion. *J Pediatr Surg Case Rep.* 2016;13:8-9.
10. Vijaysadan V, Perez M, Kuo D. Revisiting swallowed troubles: intestinal complications caused by two magnets - a case report, review and proposed revision to the algorithm for the management of foreign body ingestion. *J Am Board Fam Med.* 2006;19:511-6.
11. Tsai J, Shaul DB, Sydorak RM, Lau ST, Akmal Y, Rodriguez K: Ingestion of magnetic toys: report of serious complications requiring surgical intervention and a proposed management algorithm. *Perm J.* 2013;17:11-4.
12. Phen C, Wilsey A, Swan E, Falconer V, Summers L, Wilsey M. Non-surgical management of gastroduodenal fistula caused by ingested neodymium magnets. *Pediatr Gastroenterol Hepatol Nutr.* 2018;21:336-40.

Cite this article as: Bhusakhare N, Jain A, Sharma N, Singh V, Goyal S, Marhual JC, Kathale S. Multidisciplinary management of gastrocolic fistula post ingestion of multiple magnetic beads: a case report. *Int Surg J* 2022;9:1890-3.