

## Case Report

# Appendicular mass with pseudomyxoma peritonei: a case report

Brahampreet S. Kang<sup>1</sup>, Anshika Arora<sup>2\*</sup>, Meena Harsh<sup>3</sup>

<sup>1</sup>Department of General Surgery, <sup>2</sup>Department of Surgical Oncology, <sup>3</sup>Department of Pathology, Himalayan Institute of Medical Sciences, Swami Rama Himalayan University, Dehradun, Uttarakhand, India

**Received:** 15 September 2022

**Revised:** 14 October 2022

**Accepted:** 15 October 2022

**\*Correspondence:**

Dr. Anshika Arora,

E-mail: [anshikaarora@srhu.edu.in](mailto:anshikaarora@srhu.edu.in)

**Copyright:** © the author(s), publisher and licensee Medip Academy. This is an open-access article distributed under the terms of the Creative Commons Attribution Non-Commercial License, which permits unrestricted non-commercial use, distribution, and reproduction in any medium, provided the original work is properly cited.

### ABSTRACT

Pseudomyxoma peritonei is an infrequently occurring clinical entity having an annual incidence of less than two per million. It is originated from the rupture of a tumour filled with mucinous substance. The intra-abdominal viscera are usually covered with a jelly-like substance. This syndrome originates most frequently from tumours of the appendix or ovaries. Genetic history is expected to play a role in the appendicular mucocele. The disease advances due to the presence of microbial agents expressed in carcinomas associated with gelatinous ascites. It typically has an insidious onset with a non-exclusive presentation like an increase in abdominal girth and associated abdominal pain with locoregional dissemination initially and dissemination to multiple sites later. The main sign is pelvic ascites. Diagnosis is made by combining radiological imaging with histopathology. Ultrasound aids in identifying the pelvic mass, peritoneal implants, calcifications, effusion, septa, the associated tumours (e.g., ovaries), the involvement of mesentery, and finalizing the surgical strategy. Usually, this condition is adequately treated by combining surgical excision and/or hyperthermic intra-peritoneal chemotherapy (HIPEC), which may be omitted by selecting the patient carefully.

**Keywords:** Appendicular mass, Pseudomyxoma peritonei, Mucinous cyst

### INTRODUCTION

Pseudomyxoma peritonei (PMP) is an infrequently occurring clinical entity having an annual incidence of less than two per million.<sup>1,2</sup> The majority of cases are diagnosed at a later stage due to its sluggish progression. There is evidence of recurrence, hence, imaging studies should be of utmost importance and the cases should be promptly referred to an oncologist. The treatment of this condition is best achieved by a team of specialists, nurses trained in oncology and pharmacists. For that, one should have a thorough understanding of the presentation and course of the disease.

We present an unusual case of appendicular mass with pseudomyxoma peritonei discovered in a female patient.

### CASE REPORT

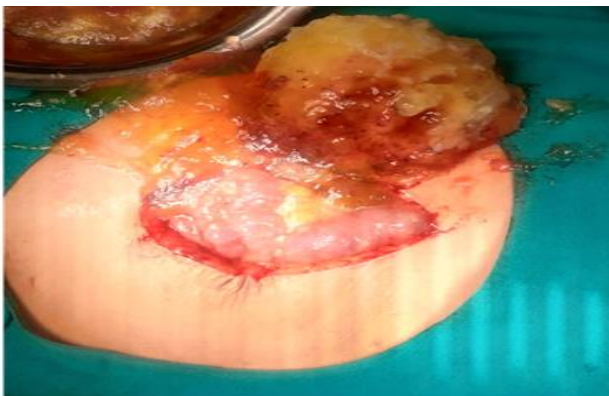A 66 years old female, with type 2 diabetes mellitus, for five years presented to the outpatient department (OPD) with chief complaints of pain abdomen for two months. The pain was gradual onset, dull, localized to the right iliac fossa, progressive, non-radiating. It was associated with an inability to pass urine, stool and flatus intermittently for the past 1.5 months. No other symptoms were noticed by the patient. She underwent a total abdominal hysterectomy around 20 years back.

On physical examination, a mass was palpable in the right lower abdomen (right iliac fossa, RIF), not crossing mid-line, which moved down with inspiration.

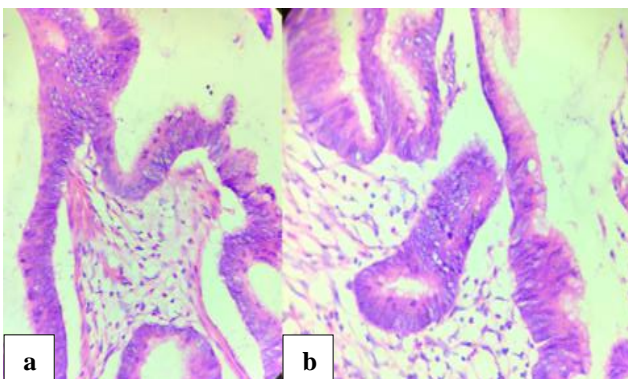
All the laboratory parameters were within normal range. Thoraco-abdominal contrast-enhanced computed tomography (CT) scan was performed after an abdominal sonogram which showed an irregular solid lesion in the RIF with moderate ascites.

The contrast enhanced CT scan showed a heterogeneously enhancing mass lesion measuring approx. 8×5×5.5 cm in the RIF with diffuse omental thickening. A hypodense lesion of the left adrenal gland was also seen with moderate ascites, suggestive of neoplastic etiology. Contrast enhanced CT scan was followed by fine-needle aspiration cytology, in which ascitic fluid was negative for malignant cells.

The tumour markers CA 19-9 and CA 125 were within normal limits; however, CEA was slightly raised (8.06 µg/l).



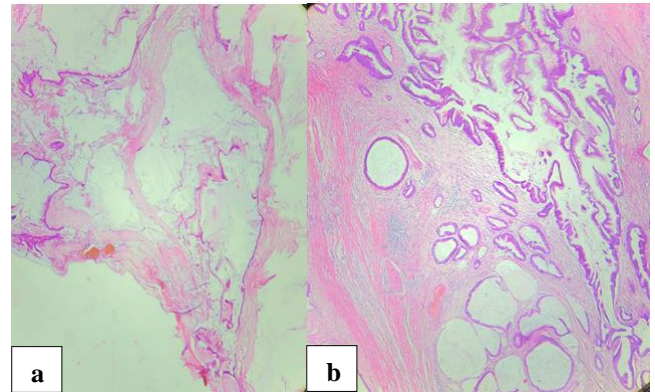
**Figure 1: Appendicular mass- an intraoperative image.**



**Figure 2: (a) and (b) Cytological atypia.**

An exploratory laparotomy was performed, which showed mucinous deposits in the whole abdomen, including visceral and parietal peritoneum. A ruptured mass containing mucin was seen near the appendix base. It was measuring approximately 5×6 cm. Uterus and bilateral ovaries were absent and there was no liver metastasis. An appendectomy was done, followed by peritoneal lavage and peritoneal biopsy. The sample was sent to evaluate the histopathology, which showed signet ring cells, moderate

chronic inflammatory infiltrates, few calcifications with bone formation. The mesenteric and peritoneal tissue sections showed large mucinous pools with intense hyalinising fibrotic reaction separating pools of mucin. These findings were consistent with high-grade pseudomyxoma peritonei; accordingly, chemotherapy was given.



**Figure 3: (a) and (b) Gland of variable shapes and sizes amidst mucin pools with some showing stratification.**

## DISCUSSION

Pseudomyxoma peritonei is an infrequent clinical condition occurring annually in less than one in two million people.<sup>3</sup>

Werth first described PMP in 1884. It is caused due to the rupture of a tumour filled with mucin. It is associated with a thick gelatinous coating over the intra-peritoneal viscera, however, there is no invasion of the viscera.<sup>4</sup> PMP represents a wide spectrum of diseases that ranges from mucinous ascites to frank mucinous carcinomatosis.<sup>5</sup>

PMP is most commonly ovarian (60%) or appendiceal (30%) in origin. Genetic history was expected to play a crucial role in the appendicular mucocele. The disease advances due to the presence of microbial agents expressed in carcinomas associated with gelatinous ascites and also with MUC5AC and MUC2 expression in mucinous peritoneal carcinomatosis. **Error! Bookmark not defined.** There is a probability of the presence of various enteric bacteria in pseudo myxoma peritonei.<sup>6,7</sup>

It can affect both genders but is more prevalent in women in their 50s.<sup>8,9</sup> It typically has an insidious onset with clinical features such as an increase in girth of the abdomen, abdominal pain with locoregional dissemination initially and dissemination to multiple sites later. Fairise et al described numerous implantation zones, suggesting that these cells have poor adhesive properties; epithelial cells proliferate to produce mucinous deposits causing local destruction followed by fibrosis that leads to obstruction in viscera and thereafter a pelvic mass, and symptoms of bowel obstruction.<sup>10,11</sup>

The main sign is pelvic ascites. Biology does not help establish the diagnosis, but the tumour markers (CA 19-9, CEA) detect early recurrences.<sup>12</sup> Diagnosis is made by combining radiological imaging with histopathology.<sup>2,13</sup> There is also the likelihood of genetic mutations; hence, they should be considered for diagnosis and guide treatment.<sup>14</sup>

Ultrasound is done to identify an ovarian mass, effusion, implants, calcifications, septa, the associated tumours, the extension of the disease on mesentery, and in finalizing the surgical approach.

#### **Pathology: WHO and TNM classification**

The classification included: group I: mucinous cystadenomas; group II: mucinous lesions (low recurrence); group III: mucinous lesions (high recurrence); and group IV: mucinous adenocarcinoma.

#### **Treatment**

Routinely, classical treatment is a dual approach i.e., by combining surgical excision and/or hyperthermic intraperitoneal chemotherapy (HIPEC).<sup>15</sup> Intraoperative chemotherapy and postoperative chemotherapy significantly enhance the prognosis.<sup>16</sup> Due to the undifferentiated characteristics of the tumour, radiotherapy is not much efficient. Despite different surgical approaches, rupture of the appendiceal mucocele must be avoided.<sup>17</sup>

If there is a presence of malignancy, removal of all the peritoneal lesions must be ensured. In the absence of an aggressive treatment, pseudo myxoma peritonei usually leads to mortality due to an accumulation of mucin in the mass. The retrospective non-randomised trial showed a better prognosis when treated principally by surgical means along with intraperitoneal chemotherapy than with cytoreductive surgery.<sup>18</sup>

Some authors propose the pressurized intraperitoneal aerosol chemotherapy to avoid hyperthermic form (CHIP) complications. However, this treatment is yet in experimental stage and can be performed only in specialized centres.<sup>19</sup>

Chua et al concluded that surgery (mass reduction) and intraperitoneal chemotherapy was favourable to surgery alone.<sup>20</sup> Wheeler et al in a case series showed 64% five-year survival rate with cytoreductive surgery without chemotherapy; Youssef et al showed a five-year and 10-year survival rate of 69% and 57%, respectively.<sup>21,22</sup>

Additionally, McBride et al in a meta-analysis concluded that mass reduction through surgery along with intraperitoneal chemotherapy is associated with increased mortality and morbidity compared with resection alone.<sup>23</sup>

Overall, the inclusive results and the need for an intraperitoneal chemotherapy in some patients can be omitted by careful patient selection. Since, the patient in this case report was diagnosed with evidence of neoplasm, a satisfactory outcome was possible with intraperitoneal chemotherapy.

#### **CONCLUSION**

The present case showed that PMP is a disease of gradual progression. There is an importance of careful evaluation of histology reports, for better management. Our patient had an adequate result; however, more research is needed in support of the available evidence to confirm that there can be an equivalent outcome in pseudo myxoma peritonei treated with surgery and hyperthermic intraperitoneal chemotherapy versus surgery alone.

*Funding: No funding sources*

*Conflict of interest: None declared*

*Ethical approval: Not required*

#### **REFERENCES**

1. Smeenk RM, van Velthuysen ML, Verwaal VJ, Zoetmulder FA. Appendiceal neoplasms and pseudomyxoma peritonei: a population based study. *Eur J Surg Oncol.* 2008;34:196-201.
2. Mittal R, Chandramohan A, Moran B. Pseudomyxoma peritonei: natural history and treatment. *Int J Hyperthermia.* 2017;33(5):511-9.
3. Smeenk RM, van Velthuysen ML, Verwaal VJ, Zoetmulder FA. Appendiceal neoplasms and pseudomyxoma peritonei: a population based study. *Eur J Surg Oncol.* 2008;34:196-201.
4. Jivan S, Bahal V. Pseudomyxoma peritonei. *Postgrad Med J* 2002;78:170-2..
5. Wrafter PF, Connelly T, Khan JS, Joyce WP. Pseudomyxoma peritonei diagnosed 19 years after appendectomy. *BMJ Case Rep.* 2015;bcr2015211706.
6. Semino-Mora C, Liu H, Macavoy T, Nieroda C, Studeman K, Sardi A, et al. Pseudomyxoma peritonei: is disease progression related to microbial agents? A study of bacteria, MUC2 and MUC5AC expression in disseminated peritoneal adenomucinosis and peritoneal mucinous carcinomatosis. *Ann Surg Oncol.* 2008;15(5):1414-23.
7. O'Connell JT, Hacker CM, Barsky SH. MUC2 is a molecular marker for pseudomyxoma peritonei. *Mod Pathol.* 2002;15:958-72.
8. Derelle AL, Tissier S, Granger P, Barbary C, Rousseau A, Laurent V, et al. Diagnostic précoce de pseudomyxome péritonéal localisé à la zone de rupture d'une mucocèle appendiculaire: imagerie et aspects anatomopathologiques. *J Radiol.* 2007;88:289-95.
9. Zerai N, Chahtane A, Lakhdar A, Khabouz S, Berrada R, Rhrab B, et al. La maladie gélatineuse du

- péritoine à propos d'un cas. *Médecine du Maghreb.* 1996;59:34-6.
10. Fairise A, Barbary C, Derelle AL, Tissier S, Granger P, Marchal F, et al. Mucocele of the appendix and pseudomyxoma peritonei. *Journal De Radiologie.* 2008;89:751-62.
  11. Buell-Gutbrod R, Gwin K. Pathologic diagnosis, origin, and natural history of pseudomyxoma peritonei. *Am Soc Clin Oncol Educ Book.* 2013:221-5.
  12. Pugin F, Bouquet De Jolinière J, Major A, Khomsi F, Guillou L, Peter M, Ben Ali N, Egger B, Feki A. Pseudomyxoma Peritonei: A Case Report Diagnosed in a 47-Year-Old Woman with Chronic Pelvic Abdominal Pain and Appendicular Origin: Review of the Literature and Management. *Front Surg.* 2017;4:41.
  13. Sulkin TV, O'Neill H, Amin AI, Moran B. CT in pseudomyxoma peritonei: a review of 17 cases. *Clin Radiol.* 2002;57(7):608-13.
  14. Sio TT, Mansfield AS, Grotz TE, Graham RP, Molina JR, Que FG, Miller RC. Concurrent MCL1 and JUN amplification in pseudomyxoma peritonei: a comprehensive genetic profiling and survival analysis. *J Hum Genet.* 2014;59(3):124-8.
  15. Dartigues P, Isaac S, Villeneuve L, Glehen O, Capovilla M, Chevallier A, Croce S, Kaci R, Lang-Averous G, Laverriere MH, Leroux-Broussier A, Mery É, Poizat F, Valmary-Degano S, Verrielle-Beurrier V, Gilly FN, Bibeau F *Ann Pathol.* 2014;34(1):14-25.
  16. Hubner M, Teixeira H, Boussaha T, Cachemaille M, Lehmann K, Demartines N. PIPAC-Chimiothérapie intrapéritonéale vaporisée. Un traitement innovateur de la carcinose péritonéale. *Rev Med Suisse.* 2015;11:1325-30.
  17. Wrafter PF, Connelly T, Khan JS, Joyce WP. Pseudomyxoma peritonei diagnosed 19 years after appendectomy. *BMJ Case Rep.* 2015;bcr2015211706.
  18. Buell-Gutbrod R, Gwin K. Pathologic diagnosis, origin, and natural history of pseudomyxoma peritonei. *Am Soc Clin Oncol Educ Book.* 2013:221-5.
  19. Solaas W, Giger-Pabst U, Zieren J, Reymond MA. Pressurized intrapéritonéal aerosol chemotherapy (PIPAC): occupational health and safety aspects. *Surg Oncol (2013)* 20:3504–11.10.1245/s10434-013-3039-x
  20. Chua TC, Moran BJ, Sugarbaker PH, Levine EA, Glehen O, Gilly FN, et al. Early- and long-term outcome data of patients with pseudomyxoma peritonei from appendiceal origin treated by a strategy of cytoreductive surgery and hyperthermic intraperitoneal chemotherapy. *J Clin Oncol.* 2012;30(20):2449-56.
  21. Wheeler BR, Reddy SK, Kenwright D, Keating JP. Treating pseudomyxoma peritonei without heated intraperitoneal chemotherapy--a first look in New Zealand. *N Z Med J.* 2014;127(1389):31-9.
  22. Youssef H, Newman C, Chandrakumaran K, Mohamed F, Cecil TD, Moran BJ. Operative findings, early complications, and long-term survival in 456 patients with pseudomyxoma peritonei syndrome of appendiceal origin. *Dis Colon Rectum.* 2011;54(3):293-9.
  23. McBride K, McFadden D, Osler T. Improved survival of patients with pseudomyxoma peritonei receiving intraperitoneal chemotherapy with cytoreductive surgery: a systematic review and meta-analysis. *J Surg Res.* 2013;183:246-52.

**Cite this article as:** Kang BS, Arora A, Harsh M. Appendicular mass with pseudomyxoma peritonei: a case report. *Int Surg J* 2022;9:1923-6.