

Original Research Article

Efficacy and durability of tricortical syndesmotic screw fixation in ankle fractures: a clinical prospective study

Kamal Kumar Arora¹, Priti Chaudhary², Rajesh Kapila¹, Raminder Singh^{1*}

¹Department of Orthopaedics, GMC, Amritsar, Punjab, India

²AIIMS, Bathinda, Punjab, India

Received: 04 September 2022

Revised: 30 September 2022

Accepted: 10 October 2022

***Correspondence:**

Dr. Raminder Singh,

E-mail: kka1967@yahoo.com

Copyright: © the author(s), publisher and licensee Medip Academy. This is an open-access article distributed under the terms of the Creative Commons Attribution Non-Commercial License, which permits unrestricted non-commercial use, distribution, and reproduction in any medium, provided the original work is properly cited.

ABSTRACT

Background: Ankle fractures represent 10% of all fractures with an incidence of around 137/105 population per year. These fractures are most of the times associated with syndesmotic injuries due to rotation of the limb with foot fixed/axial loading as a result of high velocity injuries. The syndesmosis is ruptured as a result of a torsional movement of the talus or as a result of a severe abduction force. Diastasis requires the rupture of three strong ligaments and the interosseous membrane and therefore represents a very substantial insult to the ankle at tibio-fibular joint and requires fixation. A syndesmosis screw through fibular plate prevents normal movement between the distal tibia and the fibula to allow healing and stability. Tricortical fixation provides more durability during axial loading and ankle movements while walking. The present clinical prospective study was carried out with an aim to evaluate the efficacy and durability of tricortical fixation of syndesmotic injuries, by one 3.5 mm screw through fibular plate.

Methods: The present clinical prospective study was carried out at a tertiary institute of Punjab on 50 IPD patients admitted through emergency/outdoor patient department.

Results: The 70% of the cases with surgical fixation of diastasis of syndesmosis gained normal range of motion at ankle joint after six weeks of immobilization in plaster of Paris (POP) back slab.

Conclusions: Tricortical fixation of syndesmotic injuries, by one 3.5 mm screw through fibular plate is a must as it provides stability and durability during axial loading and ankle movements while walking.

Keywords: Ankle fractures, Syndesmotic injuries, Tricortical fixation

INTRODUCTION

Ankle fractures represent 10% of all fractures with an incidence of around 137/105 population per year,¹ making these the second most common lower limb fractures after hip fractures.² The mean age at injury is 45 years, significantly older than that of patients sustaining isolated ankle sprains.¹ Both injuries have a bimodal distribution, with peak incidences of ankle injuries in younger men and older women and a 50-year gap between peaks.¹ These are typically low-energy injuries with the majority occurring due to simple falls or sport.^{1,3}

Even open ankle fractures are predominantly low-energy injuries caused by simple falls with the highest incidence in elderly women.⁴

These fractures are most of the times associated with syndesmotic injuries due to rotation of the limb with foot fixed/axial loading as a result of high velocity injuries. The syndesmosis is ruptured in ankle fractures as a result of a torsional movement of the talus that forces the tibia and fibula apart or as a result of a severe abduction force. However, the ligaments are rarely visualized or subject to MRI scanning, and their integrity is surmised from

radiographic diastasis of the syndesmosis. Diastasis requires the rupture of three strong ligaments and the interosseous membrane and therefore represents a very substantial insult to the ankle. Therefore, ankle fractures that result in a diastasis at inferior tibio-fibular joint require syndesmotic fixation.⁵

There are no definitive answers regarding the best treatment option (i.e., operative vs nonoperative, and tight rope vs screw or screw through fibular plate), and hardware removal. A syndesmosis screw through fibular plate prevents normal movement between the distal tibia and the fibula to allow healing and stability.^{6,7} Recently, a survey of the orthopaedic trauma association (OTA) members also showed a high grade of variability and controversy in the treatment of ankle fractures.⁸

Tricortical fixation to address syndesmotic injury is thought to be better than quadricortical fixation as it is considered to be more dynamic fixation than quadricortical fixation which is a more rigid fixation and provides more durability during axial loading and ankle movements while walking.

Screws, screw through fibular plate, K-wires, staples, nonabsorbable sutures, button-sutures and biodegradable implants all have been used with their proponents.^{9,10}

The present clinical prospective study was carried out with an aim to evaluate the efficacy and durability of tricortical fixation of syndesmotic injuries, by one 3.5 mm screw through fibular plate, as a result of ankle fractures/ fracture dislocations with associated disruption of syndesmosis.

METHODS

The present clinical prospective study was carried out at a government medical college, Amritsar on 50 IPD patients by simple random sampling method, admitted through emergency/outdoor patient department, from June 2020 to May 2021, with their prior consent to participate in the present study after explaining all the details about the study to them. Prior approval of the ethical committee was taken before the commencement of the study.

Inclusion criteria

Skeletally mature patients, closed fractures, fresh fractures were included in the study.

Exclusion criteria

Malignancy (primary or metastatic), Gustilo type I, II, IIIB, IIIC fractures, patients having co-morbidities like diabetes mellitus, uncontrolled hypertension, patients on steroid therapy, thyroid abnormality, and hyperactive parathyroids. Patients who were chronic alcoholics, drug addicts, chronic smokers and mentally challenged patients, patients with deranged LFT (liver function tests)

and/or deranged renal function tests. Patients medically unfit for surgery. Old neglected fractures [>12 weeks].

Detailed history regarding mode and mechanism of injury was documented followed by standard emergency evaluation and investigations. First aid in emergency in the form of splintage, elevation, [after close reduction of the fracture fragments since the syndesmotic injury is associated with bimalleolar/ trimalleolar fracture], was done. Skin over the ankle was examined for any swelling, blisters, abrasions, lacerations, punctured wound if any. Thorough radiological examination and pre-anesthetic check-up, before surgery, was carried upon them. All the patients were operated upon under spinal anaesthesia with administration of prophylactic broad-spectrum antibiotic [cefuroxime 1.5 gm] before the start of surgery.

Lateral malleolus was fixed with fibular plate after reduction of it [checked by Mercedes Benz sign] and was seconded with the fixation of medial malleolus [tension band wiring/ malleolar screws] prior to reduction of syndesmosis by one 3.5 mm screw [tricortical fixation] through fibular plate at 3.5 cm above the ankle joint. patient was splinted post operatively with broad spectrum intravenous antibiotics for five days and oral antibiotics thereafter till the removal of stitches. Check dressing was done on third post operative day and the patient was discharged on 12th post operative day after stitch removal.

Statistical analysis

The IBM SPSS software package version 20.0 (Armonk, NY: IBM Corp) [30] used for data analysis. Number and percent were used to describe qualitative data. Variables normality of distribution was verified using the Kolmogorov-Smirnov, Shapiro and D'Agostino tests. Range (minimum and maximum), mean, standard deviation used to describe quantitative data. Comparing normally distributed quantitative variables between 2 groups was performed using Student-test. Significance of results was judged at the 5% level. P value statistically significant at $p \leq 0.05$.

RESULTS

All the patients were regularly followed up in outdoor patient department at three, six, 12 and finally at six months to check the integrity of wound and the screws placed. The 70% of the cases with surgical fixation of diastasis of syndesmosis gained normal range of motion at ankle joint after six weeks of immobilization in plaster of Paris [POP] back slab. Partial weight bearing started in orthosis at six weeks and full weight bearing/ driving was allowed at nine weeks. The average Olerud and Molander score of the patients was 87 points (range, 80-96). All patients had returned to levels of work and daily living activities similar to before the injury. Average dorsiflexion of the ankle was 21° (range, 10°-40°), and average plantarflexion was 40° (range, 20°-55°). The difference relative to the uninjured side was 8° of

dorsiflexion and 6° of plantarflexion. The presence of any types of obliteration of syndesmotoc did not affect the results or range of motion of the ankle (p>0.05).

There was loss of reduction in two [04%] due to premature weight bearing with breakage of the screws. A total of 04 [08%] reported infection [superficial infection 03(06%) {deep infection 01(02%)}. The patients with superficial infection were put on suitable intravenous antibiotics for six weeks after getting the culture and sensitivity report and it was resolved eventually. The deep infection was associated with the exposure of the implant which was removed, with thorough debridement, irrigation and local application of platelet rich plasma augmented with vacuum assisted closure of the wound with suitable intravenous antibiotics for six weeks after getting the culture and sensitivity report with continuation of immobilization. There was loosening of screws in two elderly females [>65 years] with poor bone stock due to post-menopausal osteoporosis. Persistent pain after surgery was reported in 05 [10%] of the cases out which 02 [04%] had severe pain on weight bearing and underwent for ankle arthrodesis to get rid of their pain. Only 02 [04%] of the cases reported symptomatic hardware for which no active intervention but reassurance was given to the patient.



Figure 3: syndesmotoc screw.



Figure 4: Fibular plate.

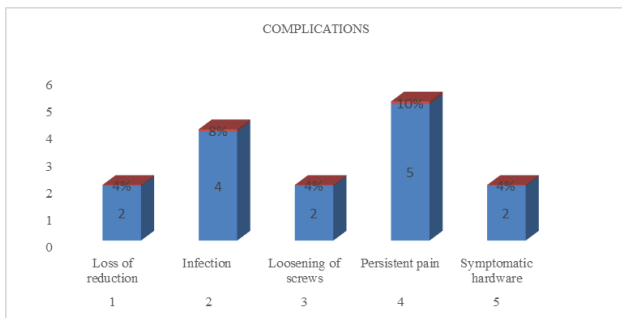


Figure 1: Complications (graphical representation).

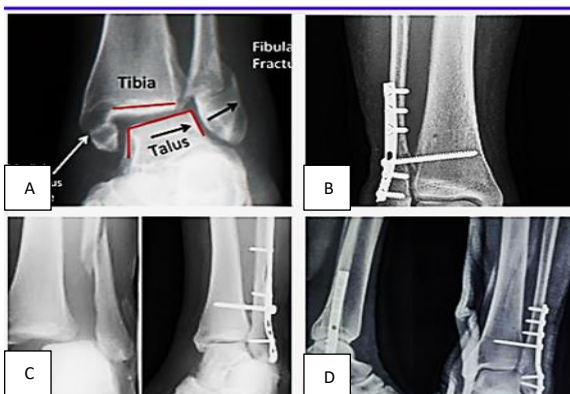


Figure 2 (A-D): Mechanism of injury to syndesmosis. Case 1 post operative x-ray (with syndesmotoc screw fixation through plate), case 2 post operative x-ray (with syndesmotoc screw fixation through plate), case 3 pre and post operative x-ray (with syndesmotoc screw fixation through plate).

Table 1: Olerud-Molander functional score.

Variables	Degree	Score
Pain	None	25
	While walking on uneven surface	20
	While walking on even surface outdoors	15
	While walking indoors	10
	Constant and severe	05
Stiffness	None	10
	stiffness	00
Swelling	None	10
	Only evenings	05
Stair climbing	Constant	00
	No problem	10
	Impaired	05
Running	Impossible	00
	Possible	05
Jumping	Impossible	00
	Possible	05
Squatting	No Problem	00
	Impossible	10
Supports	None	10
	Taping, wrapping	05
	Stick, crutch	00
	Same as before	20
Work / ADL	Loss of tempo	15
	Change to simpler job /part time work	10
	Severely impaired work capacity	00

Table 2: Results showing age, sex, side, mode, hospital stay, weight bearing and complications.

Parameters		N (%)	
Age (Years)		21-30	06 (12)
		31-40	06 (12)
		41-50	32 (64)
		51-60	02 (04)
Sex		Male	44 (88)
		Female	06 (12)
Side		Right	42 (84)
		Left	08 (16)
Associated injuries		Fracture fibula	22 (44)
		Bimalleolar fracture	28 (56)
Mode of injury		Road side accidents	04 (08)
		Direct trauma	06 (12)
		Fall	40 (80)
Stay in hospital		Seven days	42 (84)
		Seven to ten days	06 (12)
		More than ten days	02 (08)
Weight bearing	Partial weight bearing	06 weeks	50 (100)
	Full weight bearing	09 weeks	50 (100)
Functional results		Excellent	36 (72)
		Good	10 (20)
		Fair	04 (08)
Range of motion at ankle joint		Average dorsiflexion	21°
		Average plantarflexion	40°
Complications		Loss of reduction	02 (04)
		Infection	04 (08)
		Loss of fixation	02 (04)
		Persistent Pain	05 (10)
		Symptomatic hardware	02 (04)

DISCUSSION

Syndesmotic disruption is quite common in bimalleolar fractures due to subluxation/rotation of the talus bone. Screws, Screw fixation through fibular plate, K-wires, staples, non-absorbable sutures, 6 button-sutures and biodegradable implants all have been used with their proponents.^{9,10}

Screw fixation through fibular plate is most widely practiced, with 51% of orthopaedic surgeons using 3.5-mm screws, penetrating three of four cortices (67%) with equal numbers of surgeons preferring one or two screws (44% each).¹¹

Xenos et al found that two screws conferred significantly greater strength to the syndesmosis than one, with the first construct failing at a mean of 11.0 newton-meters (range, 5.0 to 15.0 newton-meters) and the second, at a mean of 6.2 newton-meters (range, 2.0 to 10.0 newton-meters) ($p=0.0005$); but concluded that these are more prone to failure due to more rigid fixation.¹²

Hoiness et al concluded that functional outcomes are better with 3.5-mm tricortical screws in comparison to those with one 4.5-mm screw spanning four cortices. The Olerud Molander functional score (0-100) (Table 1) in their study was significantly higher in the tricortical group (77 points) compared with the quadricortical group (66 points) ($p=0.025$) at 3 months.⁷

The Olerud Molander functional score in the present tricortical fixation study was 87 which is reasonably good.

Kwon et al revealed that four-cortex fixation exposes the patient to an additional risk of complications with case reports of posterior tibial tendon tear caused by damage from the tip of the screw.¹³

McBryde et al quantitated torsional force, the degree of rotation and the amount of syndesmotic widening at ankle joint. They conducted two-tailed t-test comparing no fixation with fixation at 2.0 cm and indicated less syndesmotic widening with screw placed at 2.0 cm

($p=0.04$). Two-tailed t-test comparing first screw fixation through fibular plate at 2.0 cm and second at 3.5 cm indicated less syndesmotic widening with screw placed at 2.0 cm ($p=0.07$). Pragmatically, 3.5 mm screws had a smaller head that was less likely to cause irritation as compared to 4.5 mm screw post operatively.¹⁴

Olerud studied 16 osteo-ligamentous lower-leg preparations and concluded that the screw should be inserted with the ankle in dorsiflexion as for each 10-degree increase in plantarflexion during insertion, a 1-degree residual deficit in dorsiflexion would result.¹⁵

Fractures around the ankle joint should be fixed as early as possible.

Høiness and Strømsøe reported increased rates of wound infection and longer hospital stay in patients undergoing late fixation when compared with patients undergoing early operation.⁷ Scheper et al reported that in their study, none of the 60 ankle fractures treated within one day developed an infectious wound complication, whereas in the group treated after day one 11% (16 out of 145) did develop an infectious wound complication ($p=0.004$). Ten were minor and six were major complications.¹⁶

In a similar study Mont et al reported that a delay in surgery predicts a significantly poorer clinical outcome.¹⁷

In present study all the patients were operated between 24-48 hours of admission in institution resulting in very less rate of complications.

Asloun et al and White et al proved that the use of a fibular nail / plate may obviate many of these concerns by allowing fracture fixation with lower rates of wound complications.^{18,19} Their study included 71 patients (mean age 53 ± 19): plate fixation group ($n=35$) and intramedullary nailfixation group ($n=36$ the final comparative series included 32 cases of plate fixation and 28 cases of intramedullary nail fixation. Union, post-operative complications and Kitaoka and Olerud-Molander functional scores were analysed after one year of follow-up. There were significantly fewer complications and better functional score (Olerud-Molander score) with intramedullary nailing/with plate fixation.

In present study fibular fractures were fixed with plate with satisfactory outcome.

Earlier studies have reported poor outcomes of operative treatment in elderly patients with high rates of complications particularly in postmenopausal women due to poor bone quality.^{20,21}

Beauchamp et al compared the results of treatment in 126 patients over 50 years of age who had suffered a displaced fracture of the ankle. Though operative fixation achieved better fracture positions than conservative

management, but was associated with a very high complication rate in women.²⁰

Salai and associates found in a prospective randomized trial of 84 patients older than 65 years who had displaced ankle fractures, that at a mean follow-up of 37.5 months, patients treated nonoperatively had significantly higher clinical outcome scores than those treated operatively.²¹

The present study also encountered loosening of screws in 04% of the cases due to postmenopausal deficient bone stock.

Cartilage damage on talus was a predictor of posttraumatic osteoarthritis at follow-up and was associated with persistent pain. No correlation was found between the number of lesions and the outcome but worse outcomes were found with deeper lesions and those on the anterior or lateral talus or the medial malleolus.²² A further investigation of the articular cartilage assessment using arthroscopy found the most common site of damage is the talus followed by the distal tibia and fibula and finally the medial malleolus.²³

The present study also encountered 10% incidence of post operative persistent pain due to secondary osteoarthritis of tibio-talar joint.

Limitations

Less common incidence of this fracture and small sample size are limitations of present study. These findings need further evaluation on a larger sample size to confirm the findings of present study.

CONCLUSION

Tricortical fixation of syndesmotic injuries of distal tibio fibular joint, by one 3.5 mm screw through fibular plate is a must as it provides stability and durability during axial loading and ankle movements while walking. It is also comparatively better than quadricortical fixation as it provides a less rigid fixation and thus there are less chances of fixation failure.

ACKNOWLEDGEMENTS

Author would like to thanks to the patients included in the study for their unconditional support.

Funding: No funding sources

Conflict of interest: None declared

Ethical approval: The study was approved by the Institutional Ethics Committee

REFERENCES

1. Court-Brown CM, McBirnie J. Adult ankle fractures-an increasing problem? *Acta Orthop.* 1998;69(1):43-7.

2. Court-Brown CM, Caesar B. Epidemiology of adult fractures: a review. *Injury.* 2006;37(8):691–697. 4596 76
3. Daly PJ, Fitzgerald RH, Melton LJ. Epidemiology of ankle fractures in Rochester, Minnesota. *Acta Orthop Scand.* 1987;58(5):539-44
4. Bugler KE, Clement ND, Duckworth AD, et al. Open ankle fractures: who gets them and why? *Arch Orthop Trauma Surg.* 2015;135(3):297-303.
5. Albers GH, Kort AF, Middendorf Prjm, Et Al. Distal tibiofibular synostosis after ankle fracture: a 14-year follow-up study. *J Bone Joint Surg Br.* 1996;78: 250.
6. Chissell Hr, Jones J: The influence of a diastasis screw on the outcome of Weber type-C ankle fractures. *J Bone Joint Surg Br.* 1995;77:435.
7. Hoiness P, Stromsoe K. Tricortical versus quadricortical syndesmosis fixation in ankle fractures: a prospective, randomised study comparing two methods of syndesmosis fixation. *J Orthop Trauma.* 2004;18(6):331-37.
8. Coles CP, Tornetta P, Obrebsky WT. Ankle fractures: an expert survey of orthopaedic trauma association members and evidence-based treatment recommendations. *J Orthop Trauma.* 2019;33(9):e318-24.
9. McBryde A, Chiasson B, Wilhelm A, Donovan F, Ray T, Bacilla P. Syndesmotic screw placement: a biomechanical analysis. *Foot Ankle Int.* 1997;18(5):262-6.
10. Rano JA, Savoy-Moore RT, Fallat LM. Strength comparison of allogenic bone screws, bioabsorbable screw and stainless steelscrew fixation through fibular plate. *J Foot Ankle Surg.* 2002;41(1):6-15.
11. Bava E, Charlton T, Thordarson D. Ankle fracture syndesmosis fixation and management: the current practice of orthopedic surgeons. *Am J Orthop (Belle Mead, NJ).* 2010;39(5):242-6.
12. Xenos JS, Hopkinson WJ, Mulligan ME. The tibiofibular syndesmosis. Evaluation of the ligamentous structures, methods of fixation, and radiographic assessment. *J Bone Joint Surg Am.* 1995;77(6):847-56.
13. Kwon JY, Campbell JT, Myerson MS. Posterior tibial tendon tear after 4-cortex syndesmotic screw fixation through fibular plate: a case report and literature review. *J Orthop Trauma.* 2012;26(6):e66-9.
14. McBryde A, Chiasson B, Wilhelm A. Syndesmotic screw placement: a biomechanical analysis. *Foot Ankle Int.* 1997;18(5):262-6.
15. Olerud C. The effect of the syndesmotic screw on the extension capacity of the ankle joint. *Arch Orthop Trauma Surg.* 1985;104(5):299-302.
16. Schepers T, De Vries MR, Van Lieshout EM. The timing of ankle fracture surgery and the effect on infectious complications: a case series and systematic review of the literature. *Int Orthop.* 2013;37(3):489-94.
17. Mont MA, Sedlin ED, Weiner LS. Postoperative radiographs as predictors of clinical outcome in unstable ankle fractures. *J Orthop Trauma.* 1992;6(3):352-7.
18. Asloum Y, Bedin B, Roger T. Internal fixation of the fibula in ankle fractures: a prospective, randomized and comparative study: plating versus nailing. *Orthop Traumatol Surg Res.* 2014;100(4):S255-59.
19. White TO, Bugler KE, Appleton P. A prospective randomised controlled trial of the fibular nail versus standard open reduction and internal fixation for fixation of ankle fractures in elderly patients. *Bone Joint J.* 2016;98B(9):1248-52.
20. Beauchamp CG, Clay NR, Thexton PW. Displaced ankle fractures in patients over 50 years of age. *Bone Joint Surg Br.* 1983;65(3):329-32.
21. Salai M, Dudkiewicz I, Novikov I. The epidemic of ankle fractures in the elderly: is surgical treatment warranted? *Arch Orthop Trauma Surg.* 2000;120(9):511-3.
22. Stufkens SA, Knupp M, Horisberger M. Cartilage lesions and the development of osteoarthritis after internal fixation of ankle fractures: a prospective study. *J Bone Joint Surg Br.* 2010;92(2):279-86.
23. Hintermann B, Regazzoni P, Lampert C. Arthroscopic findings in acute fractures of the ankle. *J Bone Joint Surg Br.* 2000;82(3):345-51.

Cite this article as: Arora KK, Chaudhary P, Kapila R, Singh R. Efficacy and durability of tricortical syndesmotic screw fixation in ankle fractures: a clinical prospective study. *Int Surg J* 2022;9:1851-6.