

Case Report

Pheochromocytoma in elderly people: case report

Shikhil Puzhakkal, Pradeep Puthen Veetil*

Department of Endocrine Surgery, Baby Memorial Hospital, Kozhikode, Kerala, India

Received: 22 August 2022

Revised: 14 September 2022

Accepted: 15 September 2022

*Correspondence:

Dr. Pradeep Puthen Veetil,

E-mail: pradeepputhenveetil@yahoo.co.in

Copyright: © the author(s), publisher and licensee Medip Academy. This is an open-access article distributed under the terms of the Creative Commons Attribution Non-Commercial License, which permits unrestricted non-commercial use, distribution, and reproduction in any medium, provided the original work is properly cited.

ABSTRACT

Pheochromocytoma in elderly people is a very rare disease and surgical removal is the only cure. Here we present an 81-year-old gentleman with multiple co morbidities with left adrenal incidentaloma. He was diagnosed to have left pheochromocytoma with biochemical evaluation. He underwent laparoscopic adrenalectomy after a prolonged preparation with alpha and beta blockers. This is the second oldest patient with histo-pathological diagnosis of pheochromocytoma. So high index of suspicion is needed to diagnose pheochromocytoma and a prolonged preoperative preparation is required in elderly patients. As he had high pheochromocytoma of adrenal scaling score (PASS), he is under close follow up.

Keywords: Pheochromocytoma, Elderly, Laparoscopic adrenalectomy, PASS score

INTRODUCTION

Pheochromocytomas are rare tumors usually seen in 4th to 5th decade of life. It is very rarely diagnosed in elderly as adrenal incidentalomas. Here we present a case of 81-year-old gentleman with hypertension, diabetes mellitus and coronary artery disease with left adrenal incidentaloma. Biochemically, he was diagnosed to have pheochromocytoma and was managed with pre-operative alpha and beta blockers, followed by laparoscopic adrenalectomy. Histopathology confirmed the the diagnosis of pheochromocytoma and had an aggressive scoring [Pheochromocytoma of the Adrenal gland Scaled Score (PASS) of 5]. As per literature, our patient represents the second oldest patient with a histopathological diagnosis of pheochromocytoma. After surgery his anti-hypertensive medications and oral hypoglycemic agents were reduced to minimum.

CASE REPORT

We are presenting a case of an 81-year-old gentleman with h/o hypertension on three anti-hypertensives

including a beta blocker, type 2 diabetes mellitus on insulin for 10 years and coronary artery disease on dual antiplatelets for 6 years, presented to us with left adrenal incidentaloma of size 5x4x3 cm. He was otherwise well with the exception of h/o dyspnoea on exertion grade 2. There were no symptoms of headache/ sweating/ palpitation/ chest pain/ abdominal pain. No f/h/o sudden death/ young stroke. On examination, the vitals were stable, with elevated blood pressure of 150/90 mmHg with no orthostatic hypotension and presence of bilateral pedal edema. Per abdomen was soft, non-tender and no mass was palpable. Other systems were within normal limits.

He underwent hormonal evaluation for left adrenal incidentaloma which showed elevated plasma free metanephrines and normetanephrines (Table 1). He was thus diagnosed to have pheochromocytoma. The CT of the abdomen showed 51x43x39 mm mass in the left supra renal region with absolute wash out of <60% with necrosis and hemorrhage in the mass (Figure 1). The right adrenal was separately seen which showed atheromatous changes in the abdominal aorta and a duodenal diverticulum.

Table 1: Lab report.

Lab reports		
S.cortisol (1 mg overnight dexamethasone suppression test)	2.3 mcg/dl	(<1.8)
Aldosterone renin ratio	3.5	(<30)
DHEA-S	57.4	
Plasma free metanephrine	591	(7.9-88)
Plasma free normetanephrine	2360	(20-135)
ECHO	LVEF 67% No RWMA, Normal LVSF, LVDD	
S. creatinine	1.5 mg/dl	
Sodium	143 meq/dl	
Potassium	4.2 meq/dl	

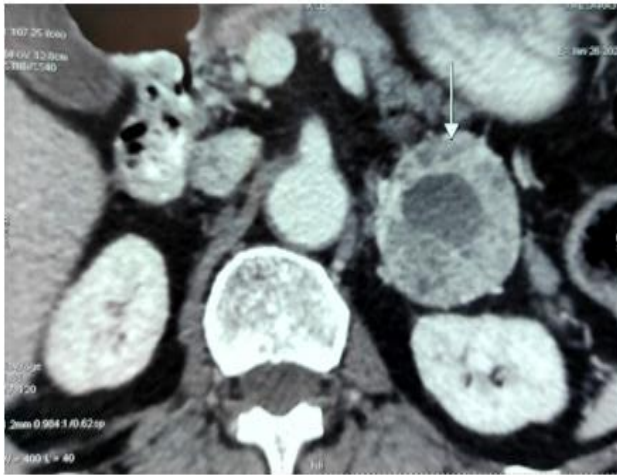


Figure 1: CT abdomen showing left adrenal mass with necrosis.

He was prepared for surgery with fluid intake of 3-4 l/day, high salt intake and started on alpha adrenergic blockade Prazosin which is a selective blocker with low dose 2.5 mg once daily. It was gradually increased to the maximum dose of 17.5 mg in divided doses as per his blood pressure over 4 weeks. On the 3rd week of alpha adrenergic receptor blockade, betablocker (metoprolol) was added to tackle tachycardia which was due to the unopposed action of alpha blockade and also due to vasodilatation.

After one month of alpha and beta blockade, he underwent laparoscopic trans-peritoneal left adrenalectomy (Figure 4). Peri operative period was uneventful. Intra operatively, maximum blood pressure recorded was 150/90 mmHg. Post operatively there were no hypotension or hypoglycemia. His sugars were controlled without insulin. He was started on oral fluids on post

operative day 2 and discharged on day 5. During discharge, he was on antiplatelets, one anti-hypertensive drug, and an oral hypoglycemic agent. His histopathology reported as pheochromocytoma with PASS score of 5 and was decided to keep on close follow up (Figure 2 and 3). He was on follow up for last 3 months with normal plasma free metanephrines and normetanephrines and also controlled sugars and blood pressure.

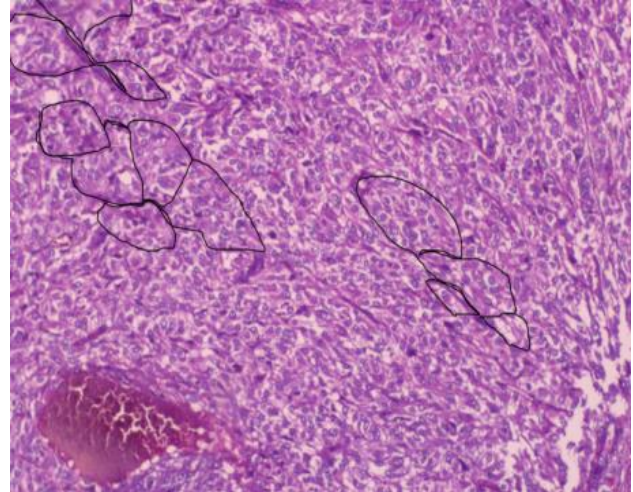


Figure 2: HPE shows 'zellballen' appearance.

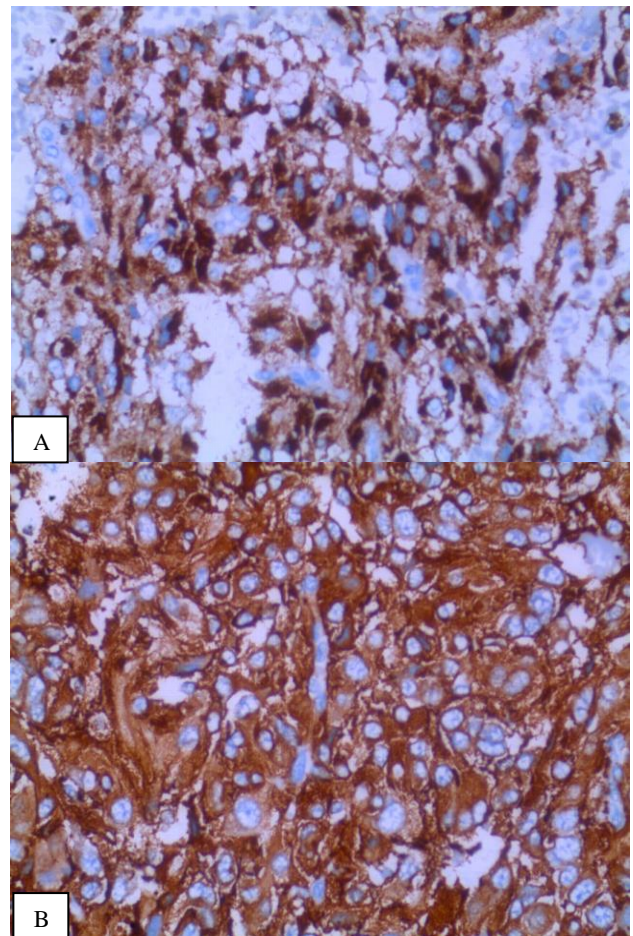


Figure 3: (A) Chromogranin positive; (B) synaptophysin positive.

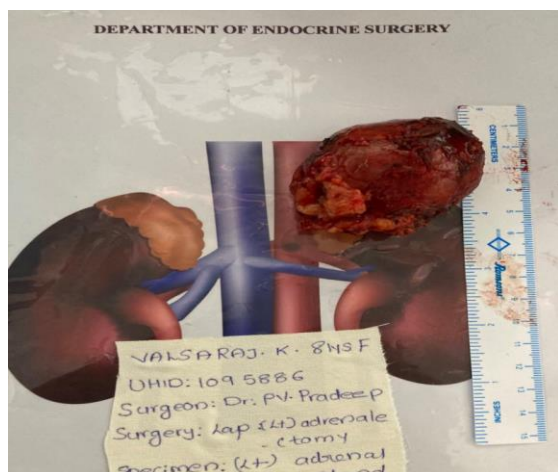


Figure 4: Specimen picture of left adrenalectomy.

DISCUSSION

Pheochromocytomas are neuroendocrine tumors of the adrenal gland which secretes excess amount of catecholamines. They show symptoms such as headache, sweating, palpitation and mimic many other conditions.¹ Prevalence of pheochromocytoma is around 0.05% in autopsy series and 0.1-0.6% in hypertensive patients.² It is commonly seen in 4th-5th decade of age. It is very rare in the old age groups; the oldest patient with histopathological diagnosis of pheochromocytoma was made in an 85-year-old lady and now our patient is listed as second in the literature.³

Our patient demonstrated that the diagnosis of pheochromocytoma is difficult in the elderly because of lack of classical symptoms due to aging, co-morbidities and medications. It can also be due to age dependant modification of metabolism of catecholamines and change of receptors including baroreceptors in different target organs.⁴ As our patient was on beta blockers, which is a common anti-hypertensive, it can perplex the symptoms of sympathetic over activity. As in our case, the co-morbidities like coronary artery disease may baffle the clinical features of pheochromocytoma.

Pheochromocytomas are more likely diagnosed as adrenal incidentalomas in the elderly as in our case and also with less symptoms.⁵ Larger tumors are paradoxically associated with less symptoms and low catecholamine levels due to metabolism of catecholamines within the tumor by catechol-o-methyl transferase enzyme. It is also due to prolonged catecholamine levels can be associated with desensitization or tachyphylaxis which leads to diminished responsiveness of the tissues to catecholamines.⁶

In our patient, the hormonal work-up was done in view of adrenal incidentaloma, which showed elevated plasma free metanephrines and normetanephrines. Meta iodo benzyl guanidine (MIBG) scan or genetic evaluation was not done in this case. He underwent a preoperative alpha adrenergic receptor blockade with prazosin along with salt intake and plenty of oral fluid. This was done in order to reduce the cardiovascular complications in peri operative periods in old patients with pheochromocytoma, titrating the dose of prazosin is challenging. Usually alpha blocker is started 10-14 days prior to the procedure and adequate alpha blockade means normal blood pressure without much orthostatic hypotension. In this case, it took almost a month to get control of blood pressure with maximum dose of prazosin and beta blocker was added later

As laparoscopic adrenalectomy is safe in elderly patients with pheochromocytoma, he underwent laparoscopic left adrenalectomy.⁷ Peri operatively he had no blood pressure fluctuation and had smooth recovery which was contrary to the study by Srougi et al.⁸ Post operatively, his anti-hypertensive medications dose decreased and insulin was stopped. This was done due to the relative increase in insulin sensitivity after withdrawal of catecholamines.

It is difficult to predict the malignancy in biopsy specimen, as invasion into an adjacent area and metastasis are the criteria to diagnose metastasis in pheochromocytoma. Histopathological examination include PASS (Pheochromocytoma of Adrenal gland Scaled Score) and GAPP (Grading system for Adrenal Pheochromocytoma and Paraganglioma) scoring which suggest the aggressiveness of the tumor. It showed 5 and 6 scores respectively in our case which needs close and long follow up.⁹

CONCLUSION

In conclusion, pheochromocytomas are rarely seen in elderly patients however, we should have a high suspicion for pheochromocytoma in elderly patients with hypertension and an adrenal incidentaloma. It is important to note that prolonged alpha adrenergic blockade may be needed in older patients to have a smooth peri-operative period. It is also understood that laparoscopic adrenalectomy is safe in elderly patients with pheochromocytoma.

Funding: No funding sources

Conflict of interest: None declared

Ethical approval: Not required

REFERENCES

1. Reisch N, Peczkowska M, Januszewicz A, Neumann HP. Pheochromocytoma: presentation, diagnosis and treatment. *Journal of hypertension*. 2006;24(12):2331-9.

2. Beard CM, Sheps SG, Kurland LT, Carney JA, Lie JT. Occurrence of pheochromocytoma in Rochester, Minnesota, 1950 through 1979. In *Mayo Clinic Proceedings*. 1983;58(12):802-4.
3. Karumanchery R, Nair JR, Hakeem A, Hardy R. An unusual case of back pain: A large Pheochromocytoma in an 85 year old woman. *International Journal of Surgery Case Reports*. 2012;3(1):16-8.
4. DiMaria CN, Rasquin LI, Hung Pinto WA. The highs and lows of an unknown pheochromocytoma in an elderly patient. *Case Reports in Endocrinology*. 2019; 2019.
5. Ayala A, Corpas E, Larrad-Jiménez Á, Serrano-Pascual Á, Blackman MR. Physiology and diseases of the adrenal glands in the elderly. In *Endocrinology of Aging*. Elsevier; 2021: 333-369.
6. Bravo E, Fouad-Tarazi F, Rossi G, Imamura M, Lin WW, Madkour MA, Wicker P, et al. A reevaluation of the hemodynamics of pheochromocytoma. *Hypertension*. 1990;15(2_supplement):I128.
7. Gunseren KO, Cicek MC, Bolat D, Yeni S, Vuruskan H, Oz Gul O, et al. Is laparoscopic adrenalectomy for pheochromocytoma safe and effective in geriatric patients?. *International Journal of Clinical Practice*. 2021;75(9):e14427.
8. Srougi V, Chambo JL, Tanno FY, Soares IS, Almeida MQ, Pereira MA, et al. Presentation and surgery outcomes in elderly with pheochromocytoma: a comparative analysis with Young patients. *International Braz J Urol*. 2016;42:671-7.
9. Kimura N, Takekoshi K, Naruse M. Risk stratification on pheochromocytoma and paraganglioma from laboratory and clinical medicine. *Journal of clinical medicine*. 2018;7(9):242.

Cite this article as: Puzhakkal S, Veetil PP. Pheochromocytoma in elderly people: case report. *Int Surg J* 2022;9:1776-9.