

Case Report

Incidental diagnosis and treatment of posterior urethral valve in a child with osteogenesis imperfecta: a case report

Uzodimma E. Onwuasoanya^{1*}, Olalekan O. Olatise², Nonso O. Epundu³, Martins C. Igbokwe¹,
Odinaka I. Ikeugwoke⁴, Adefola R. Adetunbi¹, David O. Orji¹

¹Department of Surgery, ²Department of Medicine, ³Department of Paediatrics, ⁴Department of Radiology, Zenith Medical and Kidney Centre, Abuja, Nigeria

Received: 22 July 2022

Accepted: 16 August 2022

***Correspondence:**

Dr. Uzodimma E. Onwuasoanya,
E-mail: ejike31@gmail.com

Copyright: © the author(s), publisher and licensee Medip Academy. This is an open-access article distributed under the terms of the Creative Commons Attribution Non-Commercial License, which permits unrestricted non-commercial use, distribution, and reproduction in any medium, provided the original work is properly cited.

ABSTRACT

Posterior urethral valve is the commonest cause of both urinary tract obstruction and chronic renal disease in male children. The patients may present with the complications of the disease such as impaired renal function, urinary tract infection, or anaemia. Reports abound about the association of other congenital defects with posterior urethral valve but few studies have reported the association of this disease with osteogenesis imperfecta. An 8-year-old male on management for osteogenesis imperfecta who presented to our facility following renal function test in keeping with impaired renal function and imaging result in keeping with right renal agenesis and left renal parenchymal disease, these investigations were done as part of work up for surgical treatment of osteogenesis imperfecta. Evaluation revealed posterior urethral valve and he had valvotomy with Mohan's urethral valvotome with satisfactory improvement in urine stream and renal function after the procedure. Posterior urethral valve can also occur with osteogenesis imperfecta not commonly reported to occur with it. Diagnosis of posterior urethral valve should be ruled out in any male patient with congenital abnormality to avoid missing the diagnosis when present as this can lead to renal failure.

Keywords: Posterior urethral valve, Osteogenesis imperfect, Congenital defects

INTRODUCTION

Posterior urethral valve was first described by Hampton et al in 1919.¹ Congenital obstructing posterior urethral membrane was first proposed by Dewan and Goh, later supported by histologic studies by Baskin.² It can be defined as a congenital obstructing membrane within the lumen of the posterior urethra and occur only in males.³ It has an estimated incidence of 1:4,000–8,000 and is the most common cause of both urinary tract obstruction in male infants and chronic renal disease in children.^{3,4}

The exact embryology of the condition is not completely understood, but it is believed to arise mainly as a result of an anomalous insertion of the mesonephric duct into the

primitive fetal cloaca.^{3,5} Young's original description divided posterior urethral valves into 3 types as follows: type 1-valves representing folds extending inferiorly from the verumontanum to the membranous urethra; type 2-bicuspid valves as leaflets radiating from the verumontanum proximally to the bladder neck; and type 3-valves as concentric diaphragms within the prostatic urethra, either above or below the verumontanum.¹

The affected patients may present with the complications of the disease such as urinary tract infection, sepsis, impaired renal function, anaemia and failure to thrive.⁵⁻⁷ Diagnosis is usually confirmed postnatally with micturating cystourethrogram which shows the classical posterior urethral dilatation and bladder trabeculations.⁶⁻⁸

The standard treatment of the condition is endoscopic valve ablation.⁹ Other means of valve ablation include the use of an endoscopic loop resectoscope, hook diathermy electrode, cold knife urethrotome, balloon catheter and valvulotome.⁹

Urodynamic studies to assess bladder and voiding functions are also important in the follow up protocol.¹⁰

CASE REPORT

An 8-year-old male on management for osteogenesis imperfecta by the orthopaedic surgeons which was diagnosed when he was 4 years old. He was being worked up for surgery for the above diagnosis and during the pre-operative abdominopelvic ultrasound scan and kidney function test he was found to have right renal agenesis with left renal parenchymal disease and deranged renal function respectively. He was subsequently referred to the paediatric nephrologist and urologist at our facility. History taking revealed a positive history of poor stream and anorexia but no associated hesitancy, intermittency, painful micturition or abdominal distension.

Physical examination revealed a child that was small for age who was pale with abnormal shaped lower limbs, curved almost like windswept deformities.

Investigations done were - full blood count (white blood count- $8.4 \times 10^9/l$, haemoglobin-10.9 g/dl, platelet- $252 \times 10^{12}/l$), kidney function test (potassium- 3.2 mmol/l, creatinine- 242 $\mu\text{mol}/l$, urea- 11.2 mmol/l), urinalysis (protein+, others-normal), and urine culture (no growth).

Micturating cystourethrogram revealed dilated posterior urethra with severe right vesicoureteric reflux (Figure 1).

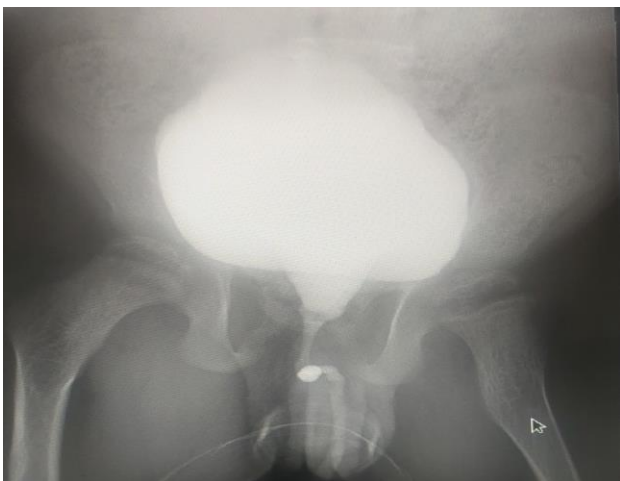


Figure 1: Micturating cystourethrogram (MCUG) showing dilated posterior urethra.

A diagnosis of posterior urethral valve was made and urethral catheter was passed while he was worked up for surgery. He subsequently had valvotomy using Mohan's

urethral valvotome (Figure 2) with markedly improved urine stream after the procedure. Urethral catheter was passed after the procedure and left for 3 days before removal; this was followed by the discharge of the patient.

Follow up review 9 days after surgery revealed marked improvement in the urine stream with remarkably improved appetite and weight gain. Kidney function test done revealed potassium of 3.1 mmol/l, creatinine of 196 $\mu\text{mol}/l$ and urea of 5.7 mmol/l. Urinalysis done was normal. He was planned for ultrasound evaluation of residual urine volume and uroflowmetry on next follow up visit.



Figure 2: Mohan's urethral valvotome.

DISCUSSION

Our index patient presented at 8 years of age, this was in keeping with studies done in South Western and Eastern Nigeria where they found that 57.1% and 52% of patients respectively presented after the age of 1.^{7,11} The late presentation in our environment may be due to paucity of prenatal ultrasound scan, ignorance, and poverty from the parents of the affected children, or paucity of medical specialists and well-equipped hospitals.

Although the diagnosis in our index patient was incidental, history taking revealed a positive history of poor stream which was one of the presentations of posterior urethral valve. Evaluation also revealed failure to thrive, impaired renal function, and anaemia which were some of the reported complications that can follow posterior urethral valves, other complications were urinary tract infections and sepsis.⁵⁻⁷

Our index patient also has osteogenesis imperfecta as associated congenital defect, this defect has not been associated with posterior urethral valve from previous studies where congenital defects in the cardiovascular, urogenital, gastrointestinal and central nervous systems have been reported in males with posterior urethral valve.^{12,13}

The diagnosis of posterior urethral valve was confirmed with micturating cystourethrogram that revealed the classical dilated posterior urethra and severe right vesicoureteric reflux.

The unilateral right vesicoureteric reflux seen in this patient can be explained by the pop off phenomenon seen in posterior urethral valve where pressure was relieved from the better kidney to preserve renal function as much as possible. The abdominal ultrasound scan done revealed right renal agenesis thus explaining why the vesicoureteric reflux was to the right as the right kidney was worse than the left so pressure was relieved from the left towards the worse right kidney to preserve as much renal function as possible.

The patient was treated by valvotomy using Mohan's urethral valvotome which was one of the reported means of ablating posterior urethral valves.⁹ This procedure is particularly very useful in developing countries where paediatric cystoscopes are not readily available and the clinicians cannot revert to the obsolete open surgery or catheter balloon ablation for treatment of posterior urethral valves.

The initial follow ups monitoring of the patient was done with voiding diary and serum creatinine which were part of the standard non-invasive post operative monitoring protocols for patients treated for posterior urethral valve.¹⁴ He was planned for uroflowmetry and ultrasound evaluation of residual urine volume on the next follow up visit.

CONCLUSION

Posterior urethral valve is a common cause of urinary tract obstruction and chronic renal disease in male children. Most children in our environment with the disease present late. Posterior urethral valve can occur with other congenital abnormalities not commonly reported with it such as osteogenesis imperfecta. High index of suspicion is thus pertinent in any male child with congenital abnormality to avoid missing the diagnosis of posterior urethral valve when present as this can lead to renal failure.

Funding: No funding sources

Conflict of interest: None declared

Ethical approval: Not required

REFERENCES

1. Young HH, Frontz WA, Baldwin JC. Congenital Obstruction of the Posterior Urethra. J Urol. 1919;3:289-365.
2. Dewan PA, Goh DG. Variable expression of the congenital obstructive posterior urethral membrane. Urology. 1995;45:507-9.
3. Krishan A, De Souza A, Konyeti R, Baskin LS. The anatomy and embryology of posterior urethral valves. J Urol. 2006;175:1214-20.
4. Brownie E, Wragg R, Robb A, Chandran H, Knight M, McCarthy L. Current epidemiology and antenatal presentation of posterior urethral valves. Outcome of BAPS CASS National Audit. J Pediatr Surg. 2019;54:318-21.
5. Nasir AA, Ameh EA, Abdur-Rahman LO, adeniran JO, Abraham MK. Posterior urethral valve. World J Pediatr. 2011;7:205-16.
6. Hodges SJ, Patel B, Mclorie G, Atala A. Posterior urethral valves. Scientific World J. 2009;9:1119-26.
7. Ikuero SO, Balogun BO, Akintomide TE, Ikuero AO, Akinola RA, Gbelee HO, et al. Clinical and radiological characteristics of Nigerian boys with posterior urethral valves. Pediatr Surg Int. 2008;24:825-9.
8. Warren J, Pike JG, Leonard MP. Posterior urethral valves in Eastern Ontario- A 30 year perspective. Can J Urol. 2004;11:2210-5.
9. Sarhan O, El- Ghoneimi A, Hafez A, Dawaba M, Ghali A, Ibrahim el-H. Surgical Complications of posterior urethral valve ablation: 20 years experience. J Pediatr Surg. 2010;45:2222-6.
10. Holmdahl G, Sillen U. Boys with posterior urethral valves: Outcome concerning renal function, bladder function and paternity at ages 31-44 years. J Urol. 2005;174:1031-4.
11. Odetunde OI, Odetunde OA, Ademuyiwa AO, Okafor HU, Ekwochi U, Azubuike JC, et al. Outcome of late presentation of posterior urethral valves in a resource limited economy: Challenges in management. Int J Nephrol. 2012;345298.
12. Heikkila J, Taskinen S, Toppari J, Rintala R. Posterior urethral valves are often associated with cryptorchidism and inguinal hernias. J Urol. 2008;180:715-7.
13. Mondal K, Maheshwari A, Aneja S, Seth A. A case of Down syndrome with a posterior urethral valve. Indian J Nephrol. 2012;22:403-5.
14. Capitanucci ML, Marciano A, Zaccara A, La Sala E, Mosiello G, De Gennaro M. Long term bladder function follow up in boys with posterior urethral valves: Comparison of non-invasive Vs invasive urodynamic studies. J Urol. 2012;188:953-7.

Cite this article as: Onwuasoanya UE, Olatise OO, Epundu NO, Igbokwe MC, Ikeugwoke OI, Adetunbi AR, Orji DO. Incidental diagnosis and treatment of posterior urethral valve in a child with osteogenesis imperfecta: a case report. Int Surg J 2022;9:1640-2.