

## Case Report

# Management of cholecystocolonic fistula: a rare case report

Davinder Kumar<sup>1\*</sup>, Durgesh Goyal<sup>1</sup>, Prabjhot Singh<sup>1</sup>, Ritu Bhukal<sup>2</sup>, Anjali Singla<sup>1</sup>

<sup>1</sup>Department of General Surgery, <sup>2</sup>Department of Pathology, Pt. Bhagwat Dayal Sharma PGIMS, Rohtak, Haryana India

**Received:** 14 July 2022

**Accepted:** 04 August 2022

**\*Correspondence:**

Dr. Davinder Kumar,

E-mail: dashay517@gmail.com

**Copyright:** © the author(s), publisher and licensee Medip Academy. This is an open-access article distributed under the terms of the Creative Commons Attribution Non-Commercial License, which permits unrestricted non-commercial use, distribution, and reproduction in any medium, provided the original work is properly cited.

### ABSTRACT

Cholecystocolonic fistula is a rare condition usually found intraoperatively if not managed may lead to serious consequences. In this case report we described a case of a 52-year-old female who was following in outpatient department (OPD) for epigastric hernia found to have cholecystocolonic fistula which was managed operatively with cholecystectomy with excision of fistula with primary repair of colon. The patient had an uneventful recovery.

**Keywords:** Gall bladder, Transverse colon, Fistula, Cholecystectomy

### INTRODUCTION

Cholecystocolonic fistula is the rare condition but is the second most common intestinal fistula after cholecystoduodenal fistula.<sup>1</sup> This condition is usually more common in females in their 6th and 7th decade.

Most common pathogenic mechanism is chronic inflammation in gallbladder due to gallstones. Diarrhea is the most common symptom noted.

Others vary from pain to life threatening complications like severe hemorrhage or biliary ileus.<sup>3</sup> Diagnosis is often achieved intra-operatively due to nonspecific symptoms. Rarity, non-specific symptoms and diagnostic challenges makes it a unique surgical entity.

Failure to identify may result in complications like perforation with fecal peritonitis may lead to sepsis or death.<sup>5</sup>

### CASE REPORT

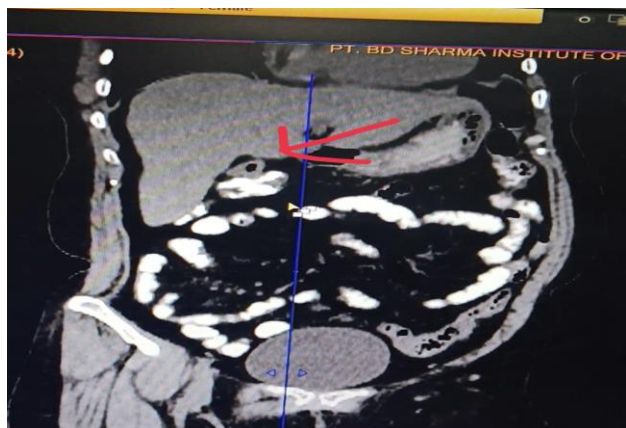A 52-year-old female resident of Shahjahanpur, Uttar Pradesh came to outpatient department (OPD) with

complaints of upper abdominal pain and swelling for 2 year and There was no history of fever. On physical examination the patient was febrile and her vital signs were stable. Abdomen was non distended and non-tender. A 2×2 cm lump with cough impulse present in midline at supraumbilical region. Routine blood investigations were within normal limits. Abdominal ultrasonography shows 1 cm defect at supraumbilical region and tiny calculi in gallbladder and air in lumen of gallbladder. A contrast enhanced computed tomography (CECT) abdomen was done which shows contracted gallbladder with small focal outpouching abutting the hepatic flexure of colon with loss of interface and tiny intraluminal air loculi in the gallbladder lumen- likely chronic cholecystitis with possible cholecysto-enteric fistula (Figure 1).

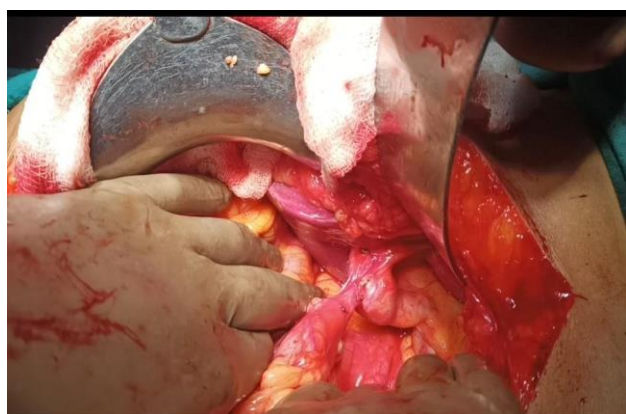Surgical management for cholecystocolonic fistula was planned and the patient underwent cholecystectomy with excision of fistula with fistula tract with primary repair of colon (Figures 2 and 3).

A fibrosed gallbladder with fistula between fundus of gallbladder and hepatic flexure of colon. Fistula was around 3 cm in length and base was 1×1 cm. Postoperative

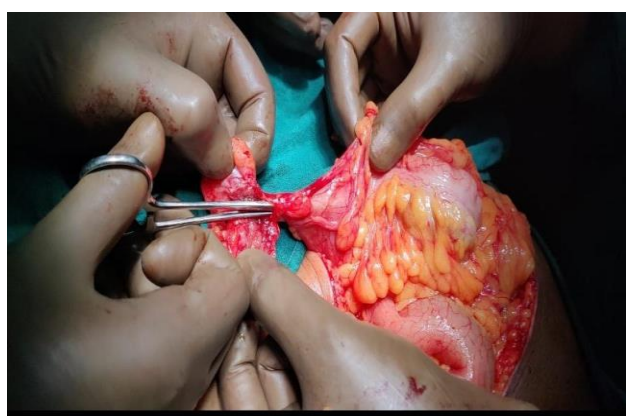
course was uneventful and the patient was discharged on postoperative day 8.



**Figure 1: CECT showing air in gallbladder and outpouching abutting colon.**



**Figure 2: Intraoperative photo of cholecystocolonic fistula.**



**Figure 3: Intraoperative photograph showing fistulous tract.**

## DISCUSSION

In this report we are describing a case of cholecystocolonic fistula which was discovered incidentally.

Cholecystocolonic fistula is a rare entity most commonly found in females in their 60s or 70s.<sup>1</sup> Presentations vary from asymptomatic patient to life threatening hemorrhage or biliary ileus.<sup>3</sup>

Here in our case patient was asymptomatic. Considering the cause, it is most commonly associated with gallstone.<sup>6</sup> Not frequent but cholecystoduodenal fistula is also associated with gallbladder carcinoma.<sup>5</sup>

Triad of diarrhea, right hypochondrium pain and cholangitis generally considered as typical picture of cholecystocolonic fistula but are rarely reported.<sup>7</sup>

Cholecystocolonic fistula may cause acute symptoms like biliary ileus which may cause colonic perforation or fecal peritonitis, massive bleeding.

Diagnosis of cholecystocolonic fistula is usually made intraoperatively when gallbladder found adhered to colon leading to change in management.

If diagnosed preoperatively then uncomplicated cholecystocolonic fistula can be managed by laparoscopic cholecystectomy with colonic resection or by laparotomy. Here we did open cholecystectomy with resection of fistula tract with primary repair of colon. The Postoperative patient had an uneventful hospital stay.

Cholecystocolonic fistula, if associated with a common bile duct, requires endoscopic retrograde cholangiopancreatography (ERCP) to relieve biliary obstruction which releases pressure from fistula may lead to spontaneous resolution.<sup>1</sup>

Complicated cases like biliary ileus or fecal peritonitis may require colostomy or decompression/exteriorization.<sup>1</sup>

## CONCLUSION

Cholecystocolonic fistula is a rare entity most common in females in 6<sup>th</sup> or 7<sup>th</sup> decade often diagnosed intraoperatively leading to change in management but diagnosed preoperatively patients can be managed by laparoscopy or laparotomy. Most of the patients are asymptomatic and diarrhea is a key symptom in uncomplicated cases. In uncomplicated cases diverting colostomy is not required. In short, diagnosis of cholecystocolonic fistula requires high suspicion and if missed intraoperation may cause fecal peritonitis or sepsis.

*Funding: No funding sources*

*Conflict of interest: None declared*

*Ethical approval: Not required*

## REFERENCES

1. Costi R, Randone B, Violi V, Scatton O, Sarli L, Soubrane O, Dousset B, Montariol T. Cholecystocolonic fistula: facts and myths. A review

- of the 231 published cases. *J Hepatobiliary Pancreat Surg.* 2009;16(1):8-18.
2. Glenn F, Reed C, Grafe WR. Biliary enteric fistula. *Surg Gynecol Obstet.* 1981;153(4):527-31.
  3. Agha RA, Fowler AJ, Saetta A. The SCARE statement: consensus-based surgical case report guidelines. *Int J Surg.* 2016;34:180-6.
  4. Angrisani L, Corcione F, Tartaglia A. Cholecystocolonic fistula (CF) is not a contraindication for laparoscopic surgery. *Surg Endosc.* 2001;15:1038-41.
  5. Chowbey PK, Bandyopadhyay SK, Sharma A. Laparoscopic management of cholecystoenteric fistulas. *J Laparoendosc Adv Surg Tech.* 2016;16:467-72.
  6. Singh AK, Gervais D, Mueller P. Cholecystocolonic fistula: serial CT imaging features". *Emerg Radiol.* 2004;10(3):1-2.
  7. Sinha S, Pullan RD. Cholecystocolonic fistula: an unusual cause of large bowel obstruction. *Br J Hosp Med.* 2006;67:434-5.
  8. Gelbman A. Gallstone ileus with cholecystocolonic fistula. *Emerg Radiol.* 2006;12:199-200.

**Cite this article as:** Kumar D, Goyal D, Singh P, Bhukal R, Singla A. Management of cholecystocolonic fistula: a rare case report. *Int Surg J* 2022;9:1662-4.