

Original Research Article

The 'Assam' technique: a simple, reproducible and leak proof technique of pancreaticojejunostomy after Whipple's procedure

Digvijoy Sharma^{1*}, Saikat Mallik², Hitesh Kalita³

¹Department of Gastro-intestinal and Hepato-pancreatico-biliary Surgery, ²Department of General Surgery, ³Department of Medical Gastroenterology, Narayana Superspeciality Hospital, Guwahati, Assam, India

Received: 04 July 2022

Revised: 05 August 2022

Accepted: 15 September 2022

***Correspondence:**

Dr. Digvijoy Sharma,

E-mail: digz.sarma@yahoo.in

Copyright: © the author(s), publisher and licensee Medip Academy. This is an open-access article distributed under the terms of the Creative Commons Attribution Non-Commercial License, which permits unrestricted non-commercial use, distribution, and reproduction in any medium, provided the original work is properly cited.

ABSTRACT

Background: Pancreatico-enteric anastomoses after Whipple's pancreaticoduodenectomy (PD) has truly remained Achilles' heel in this technically challenging and complex surgery. Many techniques have been developed over decades to reduce the rate of postoperative pancreatic fistula (POPF), which is still the major cause of morbidity and mortality even in the current era.

Methods: A retrospective review of all patients who underwent Whipple's PD by the same surgical team from August 2019 to February 2022 was performed.

Results: A total of 41 patients underwent classical Whipple's PD with the new technique of PJ during the study period. No patient developed clinically significant PF. Delayed gastric emptying was seen in three patients and surgical site infection occurred in three patients. The rate of overall morbidity was 14.3%.

Conclusions: This simple and innovative technique significantly reduces the risk of POPF irrespective of pancreatic texture and duct diameter. It is easily reproducible without adversely affecting the operative time.

Keywords: Whipples, Pancreaticoduodenectomy, Post operative pancreatic fistula, Pancreaticojejunostomy

INTRODUCTION

Pancreaticoduodenectomy (PD) is a complex, technically demanding procedure performed primarily for malignant diseases involving the periampullary structures. Even in the present era although operative mortality in patients undergoing PD has significantly reduced, high postoperative morbidity still remains an area of concern. It may range from 40% to 50%.¹⁻⁶ Postoperative pancreatic fistula (POPF) is the most dreaded complication, ranging from 5% to 30% as per previous studies.^{7,8} Many methods and techniques have been described in literature to reduce the risk of POPF, including the use of prophylactic octreotide, sealants and glue¹¹, and refinements in pancreatic reconstruction techniques.⁹⁻¹² Pancreaticogastrostomy (PG) and pancreatico-

jejunostomy (PJ) are the two modes of drainage out of which PJ is the most commonly performed procedure worldwide.

The aim of the study is to present a simple and reproducible technique with an intent to significantly reduce POPF rates irrespective of pancreatic texture and pancreatic duct diameter.

METHODS

A retrospective study of consecutive patients who underwent Whipple's PD by the same surgical team from August 2019 to February 2022 at Narayana Superspeciality Hospital, Guwahati, Assam was performed after clearance from ethical board. Patients of

age 10 years and above who underwent surgical treatment only, were included in the study. There were no exclusion criteria. Data considered for analysis were: demographic data, etiology, pancreatic texture, pancreatic duct diameter, POPF, postoperative complications and hospital stay. The diagnosis of POPF was made as per the international study group for pancreatic surgery (ISGPS) definition.

Definition of POPF

According to the updated consensus, the former grade A POPF is redefined as a biochemical leak, and the clinically relevant POPF is redefined as a drain output of any measurable volume of fluid with an amylase level more than 3 times the upper limit of serum amylase activity on postoperative day 3, associated with a clinically significant patient morbidity.

The ‘Assam’ technique

After completion of pancreaticoduodenectomy, the pancreatic remnant is dissected off the underlying structures for approximately 1 cm. The Roux loop of transected jejunum is delivered into the resection bed through a transmesocolic window and placed parallel to the cut end of pancreas. A full thickness incision is given over the antimesenteric border of jejunal limb for a length just smaller than the cephalo-caudal diameter of the pancreatic stump. Stay sutures are taken with prolene 4-0 passing through full thickness of jejunal limb and pancreatic stump at both the angles. These sutures are held with babcocks forceps as shown in Figure 1 thereby aligning the jejunal limb and pancreatic stump against each other. Now serial 4-0 prolene sutures are taken serially 5 mm apart through full thickness of posterior pancreatic stump parenchyma and posterior jejunotomy wall from cranial to caudal end. Transductal sutures are taken at 7,6,5’O clock positions inferiorly and 11,12,1’O clock positions superiorly (preplaced sutures) to keep the pancreatic duct open. Posterior layer anastomosis is completed by tying the sutures serially. An infant feeding tube corresponding to the duct diameter is placed into the PD and into the jejunal end, acting as a transanastomotic stent. The preplaced anterior transductal sutures are completed by taking bites through the anterior jejunotomy wall. The rest of anterior layer is completed in a similar fashion taking full thickness bites of pancreatic parenchyma and jejunal wall (Figures 1-3).

Statistical analysis and sample size

As there were no control groups in this study, only descriptive measures were used. All patients undergoing Whipple’s PD during the study period were taken as sample size as the aim of this study was to describe a surgical technique. The results are reported as mean with range, and percentage. All analysis were done with the help of Microsoft office 2019.

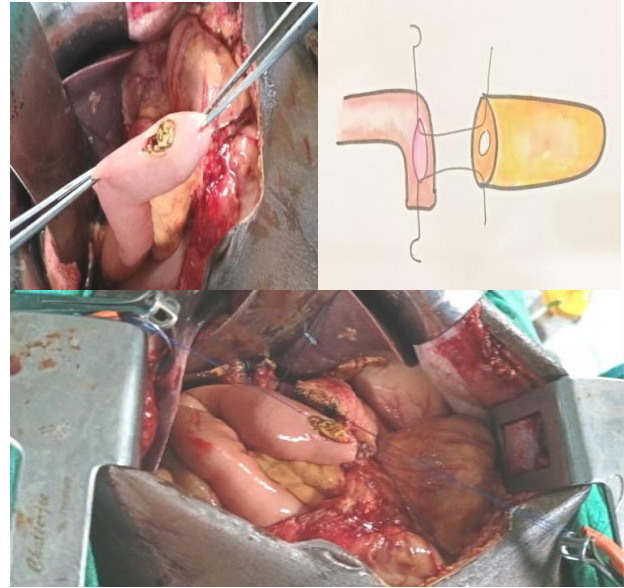


Figure 1: Jejunotomy, jejunal and pancreatic angle stay suture placement and alignment of jejuna limb and pancreatic stump.

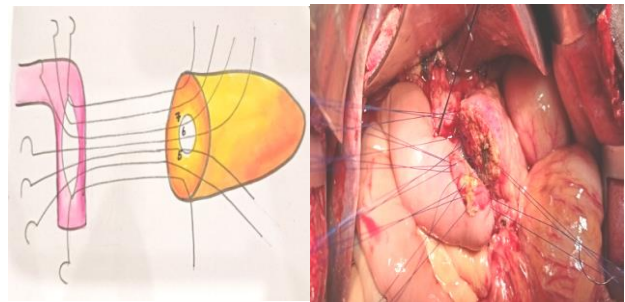


Figure 2: Posterior layer stay sutures placement.

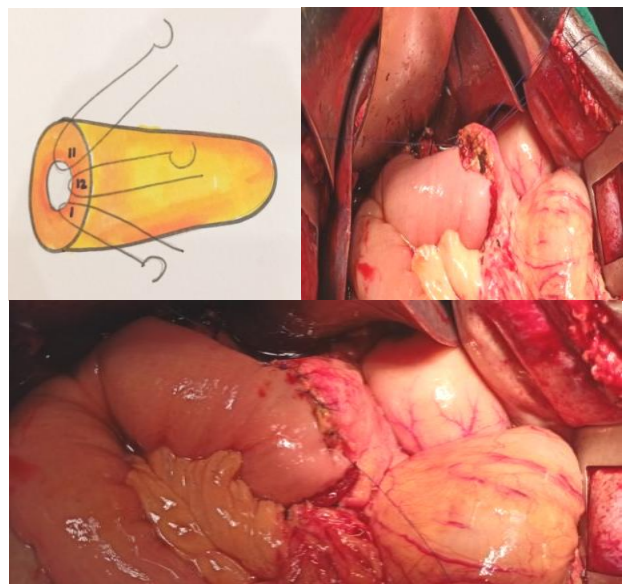


Figure 3: Anterior layer preplaced stay sutures placement, completion of posterior and anterior layer anastomosis.

RESULTS

Forty -one patients underwent classical Whipple’s PD using the described technique of PJ during the study period. Twenty-nine (70.7%) of them were men and 12 (29.3%) were women with a mean age of 44.6 years (Figure 4).

The etiology is shown in Table 1. The mean operative time for the surgical procedure from skin incision to closure was 270±40.0 min. Pancreatic parenchyma was soft in 16(39%) patients, firm in 20 (48.7%) and hard in 5 (12.1%) patients. The pancreatic duct diameter was <3 mm in 18 (43.9%) patients and >3 mm in 23 (56.1%) (Figures 5 and 6).

No patient developed clinically significant PF. Two patients developed biochemical leak which resolved without any intervention. Delayed gastric emptying was seen in 3 patients and surgical site infection in 3 patients.

The rate of overall morbidity was 14.3%. The mean hospital stay was 8.0±3.0 days. There were 2 mortalities due to sepsis in one patient and post pancreatotomy hemorrhage with multiorgan failure in the other patient (Figure 7).

Table 1: Etiology.

Etiology	Patient number (n)
Carcinoma head of pancreas	13
Distal CBD cholangiocarcinoma	17
Ampullary carcinoma	7
Solid pseudopapillary epithelial neoplasm	2
Duodenal carcinoma	2

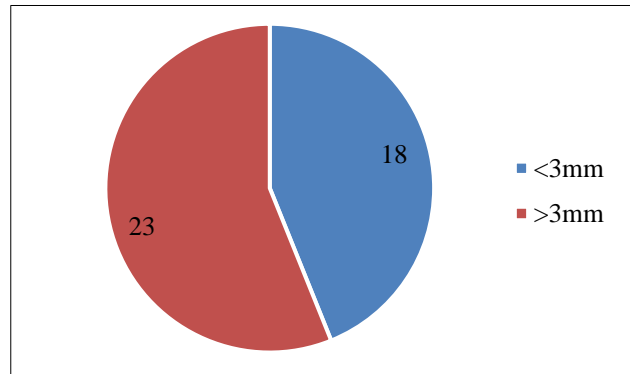


Figure 6: PD diameter (n).

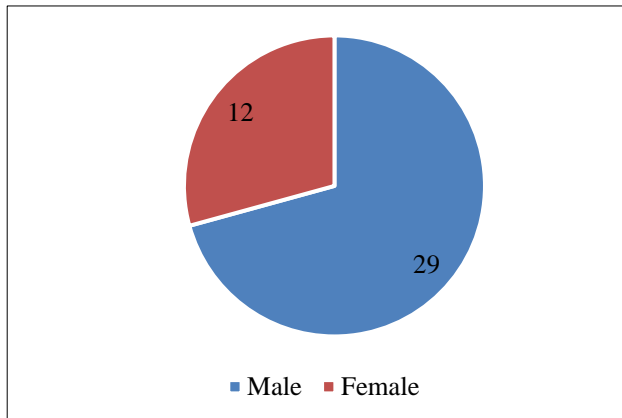


Figure 4: Demography.

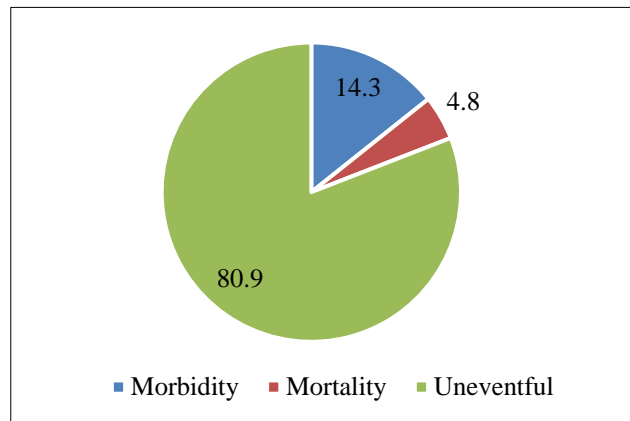


Figure 7: Post operative events (%).

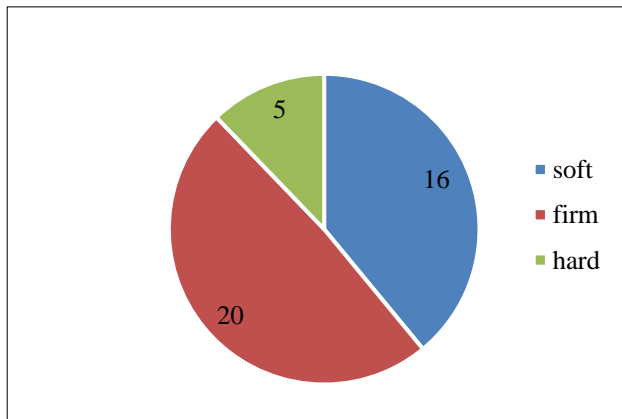


Figure 5: Pancreatic texture (n).

DISCUSSION

Pancreatico-enteric anastomoses after Whipple’s PD has truly remained Achilles’ heel in this technically challenging and complex surgery. There is an ongoing debate about the most effective pancreatic reconstruction technique with the literature showing variable results.^{2,13,14} The two commonly performed techniques are PG and PJ, and studies have been unable to prove superiority of one technique over the other.^{15,16} PJ is the most commonly performed technique of pancreatic anastomosis, as it is more physiological. The various methods of PJ are duct-to-mucosa, invagination, and binding PJ. Binding PJ proposed by Peng et al two decades back resulted in nil POPF rates, however the technique was complex and not easily reproducible.¹⁷ Some other studies using the same technique demonstrated reduced incidence

of POPF.^{13,18} However in the European population, binding PJ did not reduce the incidence of POPF.¹⁹

It should therefore be emphasized that the consistent practice of a single standardized technique of pancreatico-enteric anastomosis can help to reduce the incidence of complications. To reduce the risk of POPF and thereby reduce the subsequent morbidity, we designed a new technique that we have termed the “Assam technique”, which is simple, reproducible and almost leak proof. However, the small sample size being the limitation of the study, this technique needs to be applied to a larger study population for recommending its universal adoption.

CONCLUSION

This simple and innovative technique of PJ significantly reduces the risk of POPF irrespective of pancreatic texture and duct diameter. It is easily reproducible without adversely affecting the operative time.

ACKNOWLEDGEMENTS

Authors would like to acknowledge Dr. Swapnil Verma for proof reading and corrections of the manuscript.

Funding: No funding sources

Conflict of interest: None declared

Ethical approval: The study was approved by the Institutional Ethics Committee

REFERENCES

- Figueras J, Sabater L, Planellas P, et al. Randomized clinical trial of pancreaticogastrostomy versus pancreaticojejunostomy on the rate and severity of pancreatic fistula after pancreaticoduodenectomy. *Br J Surg* 2013;100:1597–605.
- Topal B, Fieuws S, Aerts R, Weerts J, Feryn T, Roeyen G, et al. Pancreaticojejunostomy versus pancreaticogastrostomy reconstruction after pancreaticoduodenectomy for pancreatic or periampullary tumours: a multicentre randomised trial. *Lancet Oncol*. 2013;14(7):655-62.
- Addeo P, Delpero JR, Paye F, Oussoultzoglou E, Fuchshuber PR, Sauvanet A, et al. Pancreatic fistula after a pancreaticoduodenectomy for ductal adenocarcinoma and its association with morbidity: a multicentre study of the French Surgical Association. *HPB (Oxford)*. 2014;16(1):46-55.
- Muscari F, Suc B, Kirzin S, Hay JM, Fourtanier G, Fingerhut A, et al. Risk factors for mortality and intra-abdominal complications after pancreatoduodenectomy: multivariate analysis in 300 patients. *Surgery*. 2006;139(5):591-8.
- Winter JM, Cameron JL, Campbell KA, Arnold MA, Chang DC, Coleman J, et al. 1423 pancreaticoduodenectomies for pancreatic cancer: A single-institution experience. *J Gastrointest Surg*. 2006;10(9):1199-210.
- Yeo CJ, Cameron JL, Sohn TA, Lillemoe KD, Pitt HA, Talamini MA, et al. Six hundred fifty consecutive pancreaticoduodenectomies in the 1990s: pathology, complications, and outcomes. *Ann Surg*. 1997;226(3):248-57.
- Bassi C, Butturini G, Molinari E, Mascetta G, Salvia R, Falconi M, Gumbs A, Pederzoli P. Pancreatic fistula rate after pancreatic resection. The importance of definitions. *Dig Surg*. 2004;21(1):54-9.
- Schäfer M, Müllhaupt B, Clavien PA. Evidence-based pancreatic head resection for pancreatic cancer and chronic pancreatitis. *Ann Surg*. 2002;236:137-48.
- Kollmar O, Moussavian MR, Richter S, de Roi P, Maurer CA, Schilling MK. Prophylactic octreotide and delayed gastric emptying after pancreaticoduodenectomy: results of a prospective randomized double-blinded placebo-controlled trial. *Eur J Surg Oncol*. 2008;34(8):868-75.
- Graham JA, Johnson LB, Haddad N, Al-Kawas F, Carroll J, Jha R, et al. A prospective study of prophylactic long-acting octreotide in high-risk patients undergoing pancreaticoduodenectomy. *Am J Surg*. 2011;201(4):481-5.
- Lillemoe KD, Cameron JL, Kim MP, Campbell KA, Sauter PK, Coleman JA, Yeo CJ. Does fibrin glue sealant decrease the rate of pancreatic fistula after pancreaticoduodenectomy? Results of a prospective randomized trial. *J Gastrointest Surg*. 2004;8(7):766-72.
- Motoi F, Egawa S, Rikiyama T, Katayose Y, Unno M. Randomized clinical trial of external stent drainage of the pancreatic duct to reduce postoperative pancreatic fistula after pancreaticojejunostomy. *Br J Surg*. 2012;99(4):524-31.
- Peng SY, Wang JW, Lau WY, Cai XJ, Mou YP, Liu YB, Li JT. Conventional versus binding pancreaticojejunostomy after pancreaticoduodenectomy: a prospective randomized trial. *Ann Surg*. 2007;245(5):692-8.
- Crippa S, Cirocchi R, Randolph J, Partelli S, Belfiori G, Piccioli A, et al. Pancreaticojejunostomy is comparable to pancreaticogastrostomy after pancreaticoduodenectomy: an updated meta-analysis of randomized controlled trials. *Langenbecks Arch Surg*. 2016;401(4):427-37.
- Perivoliotis K, Sioka E, Tatsioni A, Stefanidis I, Zintzaras E, Zacharoulis D. Pancreatogastrostomy versus Pancreatojejunostomy: An Up-to-Date Meta-Analysis of RCTs. *Int J Surg Oncol*. 2017;7526494.
- Wente MN, Shrikhande SV, Müller MW, Diener MK, Seiler CM, Friess H, Büchler MW. Pancreaticojejunostomy versus pancreaticogastrostomy: systematic review and meta-analysis. *Am J Surg*. 2007;193(2):171-83.
- Peng S, Mou Y, Cai X, Peng C. Binding pancreaticojejunostomy is a new technique to minimize leakage. *Am J Surg*. 2002;183(3):283-5.

18. Kim JM, Hong JB, Shin WY, Choe YM, Lee GY, Ahn SI. Preliminary results of binding pancreaticojejunostomy. *Korean J Hepatobiliary Pancreat Surg.* 2014;18(1):21-5.
19. Casadei R, Ricci C, Silvestri S, Campra D, Ercolani G, D'Ambra M, Pinna AD, Fronda GR, Minni F. Peng's binding pancreaticojejunostomy after pancreaticoduodenectomy. An Italian, prospective,

dual-institution study. *Pancreatology.* 2013;13(3):305-9.

Cite this article as: Sharma D, Mallik S, Kalita H. The 'Assam' technique: a simple, reproducible and leak proof technique of pancreaticojejunostomy after Whipple's procedure. *Int Surg J* 2022;9:1710-4.