

## Case Series

# Spontaneous retroperitoneal hematoma in COVID-19 patients

Teodor D. Atanasov, Katya T. Todorova\*, Alexandar I. Tsvetanov

Department of Surgery, Sofamed Hospital, Sofia, Bulgaria

**Received:** 09 June 2022

**Accepted:** 02 July 2022

**\*Correspondence:**

Dr. Katya T. Todorova,

E-mail: [katya.todorova@gmail.com](mailto:katya.todorova@gmail.com)

**Copyright:** © the author(s), publisher and licensee Medip Academy. This is an open-access article distributed under the terms of the Creative Commons Attribution Non-Commercial License, which permits unrestricted non-commercial use, distribution, and reproduction in any medium, provided the original work is properly cited.

### ABSTRACT

Severe acute respiratory syndrome coronavirus 2 (SARS-CoV-2) is a novel coronavirus that has led to a global pandemic and unfortunately has caused a health crisis. Severe coronavirus disease 2019 (COVID-19) can manifest with bilateral pneumonia and hypoxemic respiratory failure but also can affect different organ systems. Spontaneous rectus sheath haematomas and retroperitoneal haematomas are recognized, rare, complications of anti-coagulation therapy, including LMWH. A prompt diagnosis is important to antagonize anticoagulation and prevent further bleeding. Massive bleeding into the retroperitoneum represents a problem not only because of the loss of intravascular volume, but also because the increase in abdominal pressure may compromise perfusion to different organs, such as the liver, gut, and kidneys. We present 3 cases of severe spontaneous soft tissue hematomas (SSTH) in patient with SARS-CoV-2 infection, who were taking low molecular weight heparin for prophylaxis of DIC and venous thromboembolism. First one is 56-year-old female patient with retroperitoneal and extraperitoneal haematoma presenting with dysuria and haematuria, the second one is 67-year-old male patient with iliopsoas haematoma and the third one is 51-year-old female patient with rectus sheath haematoma. All patients were treated conservatively. Clinicians should be attentive about bleeding complications as retroperitoneal haematomas in COVID-19 patients on anticoagulant therapy. There is no consensus on management of retroperitoneal haematomas. Each decision as conservative treatment, embolization or surgery should be made according to the clinical stability of the patient and by risk and benefit assessment.

**Keywords:** Retroperitoneal hematoma, Low molecular weight heparin, COVID-19, Non-operative treatment

### INTRODUCTION

SARS-CoV-2 is a novel coronavirus that has led to a global pandemic and unfortunately has caused a health crisis. Severe coronavirus disease 2019 (COVID-19) can manifest with bilateral pneumonia and hypoxemic respiratory failure but also can affect different organ systems.<sup>1</sup>

One of the causes of high mortality in COVID-19 patients is increased risk of disseminated intravascular coagulation (DIC) and venous thromboembolism as

evidenced by altered coagulation profile like elevated D-dimers.<sup>2</sup> To combat this hypercoagulable state, patients infected with COVID-19 should be properly anticoagulated to reduce ischemic risk.<sup>3</sup> Haemorrhagic complications, even uncommon ones such as retroperitoneal haemorrhage, can occur following anticoagulant administration.<sup>4</sup>

We presented 3 cases of severe spontaneous soft tissue hematomas (SSTH) in patient with SARS-CoV-2 infection, who were taking low molecular weight heparin for prophylaxis of DIC and venous thromboembolism.

## CASE SERIES

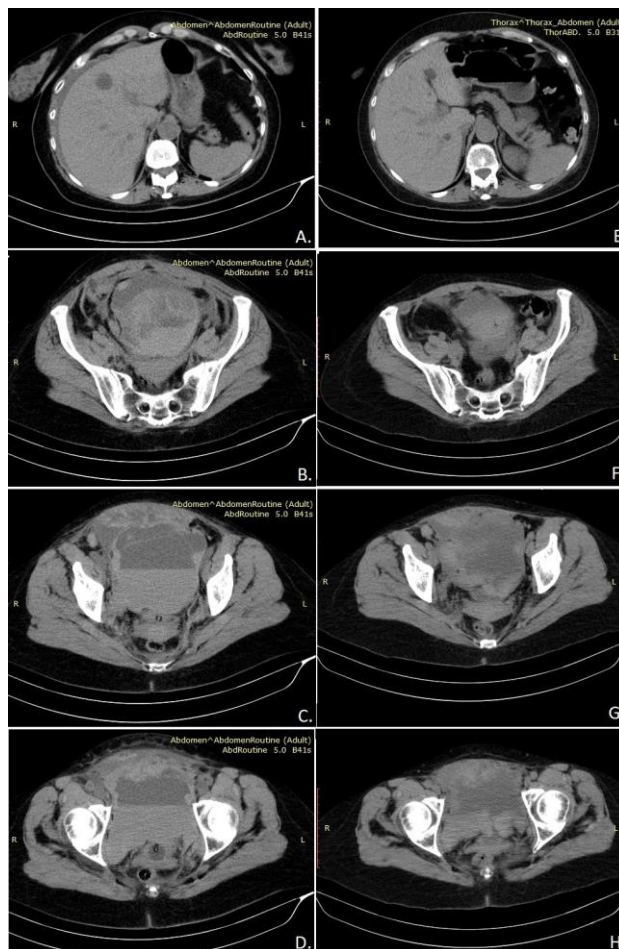
### Case 1: Retroperitoneal and extraperitoneal haematoma presenting with dysuria and haematuria

A 56-year-old woman presented with fatigue, cough and high body temperature. Her past medical history included Hashimoto's disease. Her symptoms had begun 12 days before admission. The last 5 days she was taken azithromycin 500 mg. daily. She took no anticoagulant or antiaggregants before admission. Vital sign on admission showed body temperature (T) 36.9°C, blood pressure (BP) 130/90 mmHg, pulse rate (PR) 110 bpm, blood oxygen saturation (SpO<sub>2</sub>) 91-92% on room air. The initial laboratory tests revealed haemoglobin level 140 g/l, ferritin 622.3ng/ml. Her D-dimer was slightly elevated 359 ng/ml. The chest roentgenography showed bilateral ground glass and consolidative opacities-bilateral interstitial infiltrates, mostly in the left. She was started on antibiotic (ampicillin/sulbactam and levofloxacin), dexamethasone, remdesivir, famotidine, supplementary oxygen and subcutaneous nadroparin as prophylaxis 0.6 ml/daily.

Seven days after admission, the patient complained of dysuria, pain when urinating, haematuria, pain in the lower abdomen. Vital signs: BP-90/60 mmHg, PR-123 bpm, blood SpO<sub>2</sub> 85% on room air. Physical examination showed pain in the lower abdomen, mostly in the suprapubic region, with no peritoneal reaction. CT scan and laboratory test were performed. CT scan showed large collection in the pelvis (13.9/12.2/11.5 cm.)-dorsal of the abdominal wall, indefinable from her, located on broad base to the right rectus abdominis muscle. The collection was liquid and oval shaped, separated with many levels of sedimentation dorsally compressing the uterus, the sigmoid colon and the bladder. In cranial direction the formation was followed retroperitoneal to the two common and external iliac arteries. There was intraperitoneal liquid collection-perihepatic and in the right and left lateral canal (Figure 1 A-D).

Laboratory test showed haemoglobin (HGB) level 71 g/l, haematocrit (HCT)-21.1%. Her D-dimer was in normal range. Prothrombin time (PT)-17.9 s, activated partial thromboplastin time (aPTT)-59.1, international normalized ratio (INR)-1.52 and platelet count (PLT)-302. From the urine laboratory there was haematuria 2+. The patient was transferred to the ICU. Blood transfusions were performed, the antibiotic therapy was changed to meropenem 3×2 g, haemostatic medications were administrated (etamsylate, vitamin C, calcium gluconate), anticoagulation was discontinued. The patient's condition gradually improved. On the 5th day in the ICU patient's haemoglobin level raised up to 124 g/l. She was transferred in the COVID-19 ward. Control abdominal ultrasound and CT scan were performed before the discharge (on the 10th day of the previous CT). They showed reduction and organisation of the haematoma in the abdominal wall and no liquid

collection in the abdominal cavity (Figure 1 E-H). The patient was discharged on the 17th day from the admission. Haemoglobin level on the discharge day was 136 g/l. Control CT scan 1 year later showed no evidence of the hematoma-full resorption.

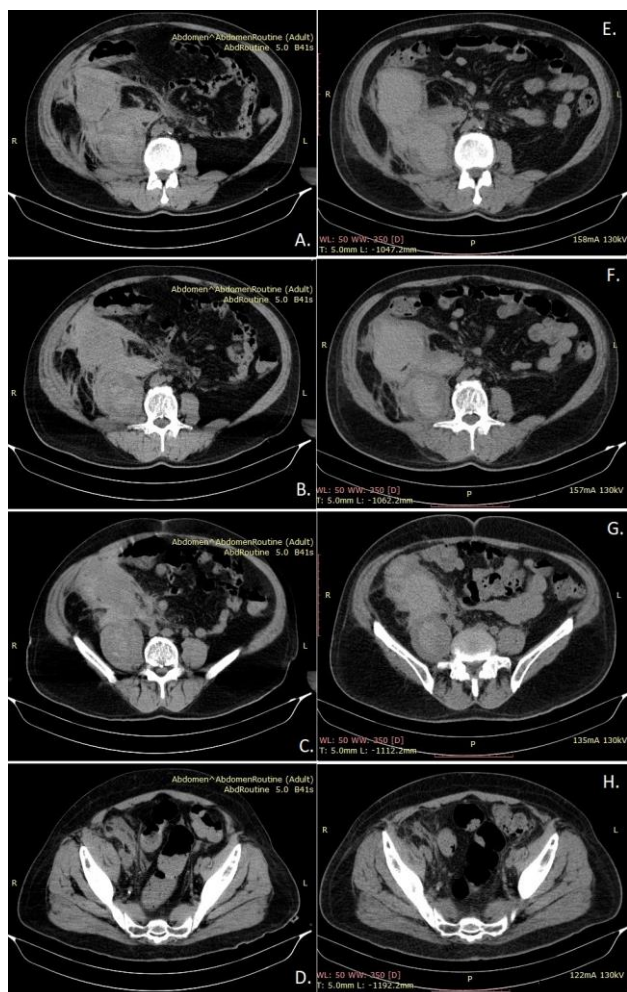


**Figure 1: Retroperitoneal haematoma - first CT (A, B, C, D) and control CT on the 10th day (E, F, G, H).**

### Case 2: Iliopsoas hematoma

A 67-year-old man presented with fatigue, cough and shortness of breath. His symptoms begun 6 days before the admission. PCR test for COVID-19 was performed, positive. Roentgenography of the chest performed 6 days before admission showed bilateral interstitial infiltrates. Then he started treatment with levofloxacin, dipyridamole, famotidine, methylprednisolone, serratiopeptidase, supplements. Previous day before the admission CT scan of the chest was performed. It showed bilateral interstitial pneumonia related to SARS-CoV-2 infection, moderate degree of involvement, late stage of development. After the CT scan his therapy was changed-apixaban and colchicine were added. His medical history showed newly discovered diabetes and arterial hypertension. Medication were empagliflozin/metformin hydrochloride 5/1000 mg, enalapril maleate/hydrochlorothiazide 20/12.5 mg, bisoprolol 10 mg daily. Vital sign on

admission showed T 36, 60C, BP-120/80 mmHg, PR-103 bpm, SpO<sub>2</sub>-93% on room air. The initial laboratory tests revealed haemoglobin level 149 g/l, CRP 118.4 mg/l, creatinine 228.0 μmol/l, PLT 98.0 10<sup>9</sup>/l. His D-dimer was slightly elevated 359 ng/ml. PT, aPTT, INR and platelet count all were within the normal laboratory range. He was started on antibiotic (cefoperazone/sulbactam), dexamethasone, famotidine, supplementary oxygen and subcutaneous nadroparin as prophylaxis 0.6 ml/daily.

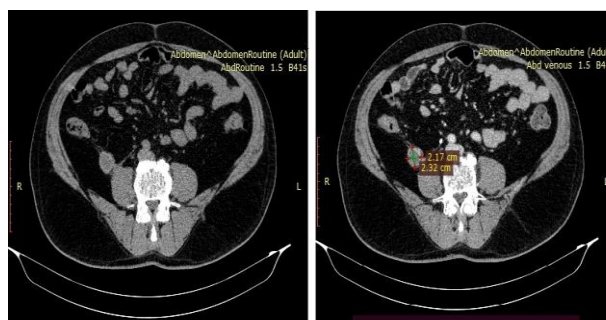


**Figure 2: Iliopsoas haematoma - first CT (A, B, C, D) and control CT on the 7th day (E, F, G, H).**

On the 11th evening after the admission the patient fainted in the bathroom. Quickly he became conscious with no need of CPR. He complained of pain in the right lumbar region. From the physical examination there were hypotension and tachycardia: BP 80/40 mmHg and HR 125, pain in the right lumbar region. The abdomen was soft with no sign of peritoneal reaction. Per recti there were no signs of bleeding. Emergency laboratory tests showed HGB 75g/l, HCT 22.7%, PLT 232.0 10<sup>9</sup>/l, K<sup>+</sup> 5.7 mmol/l, Na<sup>+</sup> 127 mmol/l, blood creatinine 219 μmol/l, blood urea 27.1mmol/l. From the urine test there were sign of haematuria. Emergency CT scan of the abdomen was performed. It showed large hetero dense

collection along the whole right psoas muscle, starting from the beginning of psoas muscle on the level of L1-L2 caudally along iliac muscle to his insertion in the little tuberculum of the femur. There was retroperitoneal collection with size 12.9/6.3/6.4 cm (Figure 2 A-D). The patient was transferred to the ICU. Then, anticoagulation was discontinued, and treatment started with IV fluid, transfusions of packed red cells and Fresh frozen plasma, diuretics. The antibiotic therapy was switched to Clindamycin. Haemoglobin level raised up to 90 g/l and stood stable for the next 7 days. The patient was transferred to general surgery department for condition monitoring. Control CT scan of the abdomen was performed 7 days after the previous one. It showed slight reduction and signs of organisation of the haematoma (Figure 2 E-H). Patient was discharged on the 20th day of the admission. One month after the symptoms of haematoma control laboratory tests showed HGB 131 g/l and HCT 38.7%. D-dimer was in normal range.

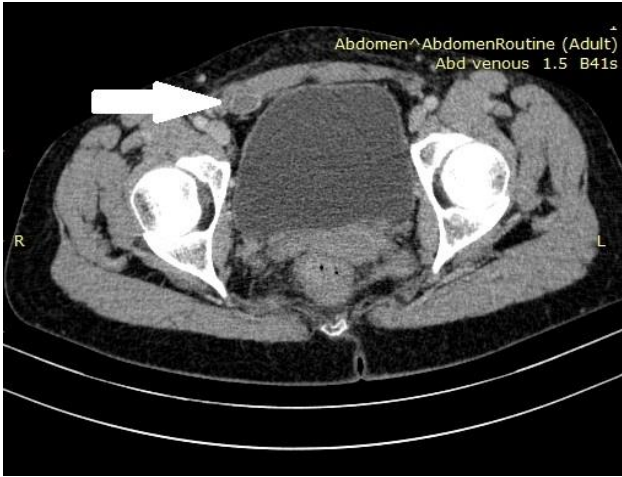
Control CT scan was performed 1 year after the hospitalisation. It showed that the size of the haematoma was reduced to 2.17/2.32cm (Figure 3). The patient had no subjective symptoms.



**Figure 3: Iliopsoas hematoma - control CT (1 year).**

### Case 3: Rectus sheath hematoma

A 51-year-old woman presented with fatigue, nausea, high body temperature, shortness of breath. Her past medical history included thalassemia minor. Her symptoms began 9 days before admission. For 6 days she took azithromycin, after that cefixime and levofloxacin, dexamethasone and enoxaparin 0.4 ml. Vital sign on admission showed T 36.8°C, BP-100/60 mmHg, PR-78 bpm, SpO<sub>2</sub>-95% on room air. The initial laboratory tests revealed haemoglobin level 116 g/l, CRP 6.9 mg/l, PLT 183×10<sup>9</sup> /l. Her D-dimer was slightly elevated 359. PT, aPTT, INR and platelet count all were within the normal laboratory range. Chest CT scan showed bilateral interstitial pneumonia related to SARS-CoV-2 infection, peak to consolidation and organisation stage, moderate parenchymal involvement. She was started on antibiotic (clindamycin), methylprednisolone, remdesivir, famotidine, pulmicort inhalations, supplementary oxygen and subcutaneous nadroparin as prophylaxis 0.4 ml/daily.



**Figure 4: Rectus sheath haematoma - control CT.**

Three days after the admission, the patient complained of abdominal pain. From the physical examination the abdomen was soft, with no peritoneal reaction, there was palpable formation in the right rectus abdominis muscle with size around 6 cm. Abdominal ultrasound was

performed. It showed abundant, poorly demarked, mostly hypo echogenic collection in the abdominal wall, under the fascia of the right rectus abdominis muscle-haematoma in the abdominal wall, limited under the fascia of the right rectus abdominis muscle. Blood laboratory revealed HGB 80 g/l, HCT 24.6%, CRP 22.1. The nadroparine was discontinued. Transfusion of 1-unit red blood cells, 1-unit fresh frozen plasma and 1-unit convalescent blood plasma were performed. The haematoma started to resorb and colouring of the skin appeared in that area. The whole lower abdomen, pelvis, both inguinal regions, pubis and labia were first dark blue, purple than changed to green and yellow. To the time of discharge the colouring was almost disappeared. After transfusions haemoglobin level raised to 100 g/l. On the 13th day from the admission the patient was discharged. 30 days after the ultrasound of the abdomen control CT scan was performed. It showed haematoma under the fascia of the right rectus abdominis muscle in organisation stage-hypo dense well delimited collection with size 1.27/1.21 cm (Figure 4). The patient had no subjective symptoms. One year after that, control CT scan showed full resorption.

**Table 1: Characteristics of the reported cases.**

Characteristics	Patient 1	Patient 2	Patient 3
Age (in years)	56	67	51
Sex	F	M	F
Comorbidities	Hashimoto's disease	Diabetes, hypertension	Thalassemia minor
Clinical presentation at admission days from symptoms onset to admission	12	6	9
Symptoms	Fatigue, cough, fever	Fatigue, cough, shortness of breath	Fatigue, nausea, fever, shortness of breath
SpO2 at admission on room air	91%	93%	95%
Days from admission to presence of the haematoma	7	11	3
Length of hospital stay	17	20	13
Exitus	Discharged	Discharged	Discharged
Inflammatory index at admission			
haemoglobin, g/l	140	149	116
Platelets, ×10 <sup>9</sup> /l	210	98	183
Haematocrit, %	41.7	43.7	35.6
D-dimer, mcmol/l	359	305	239
Ferritin, ng/ml	622.3	311.4	354.8
PT, INR	N/A	1.0	0.95
PTT, sec	N/A	12.3	11.8
C-reactive protein, mg/l	57.6	118.4	6.9
Inflammatory index at the presence of haematoma			
Haemoglobin, g/l	71	75	80
Platelets, ×10 <sup>9</sup> /l	302	232	250
Haematocrit, %	21.1	22.7	24.6
D-dimer, mcmol/l	272	173	N/A
Ferritin, ng/ml	316.1	372	N/A
PT, INR	1.52	1.23	N/A
PTT, sec	17.9	14.6	N/A

Continued.

Characteristics	Patient 1	Patient 2	Patient 3
<b>C-reactive protein, mg/l</b>	14.9	30.1	22.1
<b>Treatment during hospitalisation remdesivir</b>	Yes	No	Yes
<b>Steroids</b>	Dexamethasone	Dexamethasone	Dexamethasone/ Methylprednisolone
<b>LMWH prophylaxis</b>	Yes	Yes	Yes
<b>Need for oxygen supplement</b>	Yes (NIV)	Yes (NIV)	Yes (NIV)

N/A: not available; PT prothrombin time; INR: international normalized ratio; LMWH: low molecular weight heparin; NIV: non-invasive ventilation.

## DISCUSSION

First reported clinical case of retroperitoneal haemorrhage due to lumbar artery bleeding in a patient of COVID-19 being treated with enoxaparin was publicized in June 2020.<sup>3</sup> In this report attention was paid to clinicians, who should be vigilant about bleeding complications such as retroperitoneal haemorrhage in COVID-19 patients on anticoagulation.<sup>3</sup> It was well known that one of the causes of mortality in COVID-19 patients was venous thromboembolism (VTE) as evidenced by altered coagulation profile like high elevated D-dimer, fibrinogen, factor VIII.<sup>5</sup> This disorder of the haemostasis may be due to severe inflammatory state. This combination of inflammation and thrombosis can be referred to thromboinflammation or COVID-19 associated coagulopathy.<sup>6</sup> Systemic response to this thrombo-inflammatory reaction may lead to VTE, deep vein thrombosis (DVT), pulmonary thromboembolism (PTE), acute coronary syndrome (ACS), brain stroke, sepsis-induced coagulopathy (SIC) and DIC.<sup>7</sup> Available scientific reports showed arteriovenous thromboembolism (6.6%), PTE (2.4-35%), isolated lower limbs DVT (0.9-54%), proximal DVT (0.5-25%), major bleeding (2.7%), and mortality (8.7-44%) in patients with SARS-CoV-2 who received anticoagulants.<sup>8</sup> Concerning these findings, anticoagulation therapies have become important part of the treatment among inpatient and particularly ICU admitted subjects with COVID-19 disease.<sup>9</sup> So far there was no general consensus, about details of anticoagulation prescription. Enoxaparin, UFH, fondaparinux, aspirin and direct oral anticoagulants (DOAC) including rivoraxaban, apixaban and dabigatran are recommended in different guidelines.<sup>7-9</sup> Clinicians agreed to use low-molecular weight heparin (LMWH) in critically ill COVID-19 patients. However, routine administration of LMWH in non-severe cases was controversial.<sup>9,10</sup> Interim analysis of pooled data from the ACTIV-4a, REMAPCAP and ATTACC randomised clinical trials suggested that LMWH was beneficial for patients not requiring intensive care support.<sup>11</sup> However, there have to be consciousness about the bleeding risk associated with COVID-19. The interim analysis of the previous-mentioned clinical trials paused enrolment of critically ill patients due to futility and a potential for harm due to higher rates of bleeding in these patients.<sup>11</sup> Systematic review of incidence of VTE and bleeding amongst hospitalised patients with COVID-19 found that the incidence was 17% for VTE, 7.1% for pulmonary

embolism (PE), 7.8% for bleeding and 3.9% for major bleeding.<sup>12</sup> Cases of spontaneous rectus sheath (RSH), and retroperitoneal haematomas (RPH) have also been described, both of which were rare pre-COVID-19.<sup>3,4</sup>

Spontaneous rectus sheath haematomas and retroperitoneal haematomas were recognized, rare, complications of anti-coagulation therapy, including LMWH. The mortality rate of these conditions was up to 20%. A prompt diagnosis was important to antagonize anticoagulation and prevent further bleeding. Massive bleeding into the retroperitoneum represented a problem not only because of the loss of intravascular volume, but also because the increase in abdominal pressure may compromise perfusion to different organs such as the liver, gut and kidneys.<sup>13</sup> The pathogenesis of retroperitoneal haematoma was unknown. Except as a complication of anticoagulation therapy, more rarely in the setting of clotting disorder or traumatic injury during the patient's mobilisation in the prone position.<sup>14,15</sup> There was a hypothesis that pre-existing microvascular atherosclerosis could increase sensitivity to rupture and microtrauma such as cough or vomiting could lead to retroperitoneal bleeding.<sup>16</sup> It was uncertain whether SARS-CoV-2 have direct effect on endothelial cells that cause haemorrhage events. Other hypotheses have been raised, too. The affinity of SARS-Cov-2 for angiotensin-converting enzyme 2 receptors on endothelial cells can directly damage vessels, causing rupture of the vessel wall. On the other hand, renin-angiotensin-aldosterone system dysregulation may led to increased blood pressure, causing haemorrhagic events.<sup>17</sup> There was reported case of ilio-psoas haematoma in COVID-19 patient with no anticoagulation therapy.<sup>1</sup>

The current case series showed retroperitoneal haematomas in three COVID-19 patients on prophylactic dose anticoagulants (LMWH). Symptoms of the patients was different, as a result of the different location of the haematoma. First patient presented with lower abdominal pain, dysuria and haematuria, due to compression of the bladder from the haematoma. The second case was presented with Lenk's triad: severe flank pain, haemodynamic shock, palpable mass-typical for the ilio-psoas haematoma. Contrast-enhanced CT played important role in diagnosis, providing a wide range of information about the volume, spatial extent and compressive complications or extravasation.<sup>15</sup> It was

performed on two of the patients. Control CT scan was performed on the third patient 30 days after the presence of haematoma. She was diagnosed with abdominal ultrasound. Initial treatment of all patients consisted cessation of the anticoagulants, transfusion therapy, volume resuscitation and supportive measures. When the patient is haemodynamically unstable, unpredictable large soft tissue haematoma can be treated with arterial embolization as it is minimally invasive with quick therapeutic effect when compared with surgical treatment.<sup>3</sup> All three patients were discharged with no further complications.

## CONCLUSION

COVID-19 is known to cause hypercoagulable state, requiring the use of anticoagulant therapy. Until the optimal anticoagulation therapy is proved by randomised trials, there is no clarity about the right dose and type of the anticoagulants in COVID-19 patients. Clinicians should be attentive about bleeding complications as retroperitoneal haematomas in COVID-19 patients on anticoagulant therapy. There is no consensus on management of retroperitoneal haematomas. Each decision as conservative treatment, embolization or surgery should be made according to the clinical stability of the patient and by risk and benefit assessment.

*Funding: No funding sources*

*Conflict of interest: None declared*

*Ethical approval: Not required*

## REFERENCES

1. Erdinc B, Raina JS. Spontaneous Retroperitoneal Bleed Coincided with Massive Acute Deep Vein Thrombosis as Initial Presentation of COVID-19. *Cureus*. 2020;12(8):e9772.
2. Cattaneo M, Bertinato EM, Birocchi S, Brizio C, Malavolta D, Manzoni M, et al. Pulmonary embolism or pulmonary thrombosis in COVID-19? Is the recommendation to use high-dose heparin for thromboprophylaxis justified? *Thromb Haemost*. 2020.
3. Patel I, Akoluk A, Douedi S, Upadhyaya V, Mazahir U, Costanzo E, et al. Life-Threatening Psoas Hematoma due to Retroperitoneal Hemorrhage in a COVID-19 Patient on Enoxaparin Treated with Arterial Embolization: A Case Report. *J Clin Med Res*. 2020;12(7):458-61.
4. Mahboubi-Fooladi Z, Arabi PK, Khazaei M, Nekooghadam S, Shadbakht B, Moharamzad Y, et al. Parenteral Anticoagulation and Retroperitoneal Hemorrhage in COVID-19: Case Report of Five Patients. *SN Compr Clin Med*. 2021:1-6.
5. Zhou F, Yu T, Du R, Fan G, Liu Y, Liu Z, et al. Clinical course and risk factors for mortality of adult inpatients with COVID-19 in Wuhan, China: a retrospective cohort study. *Lancet*. 2020;395(10229):1054-62.
6. Ranucci M, Ballotta A, Di Dedda U, Bayshnikova E, Dei Poli M, Resta M, et al. The procoagulant pattern of patients with COVID-19 acute respiratory distress syndrome. *J Thromb Haemost*. 2020;18(7):1747-51.
7. Li Y, Xu Y, Shi P. Antiplatelet/anticoagulant agents for preventing thrombosis events in patients with severe COVID-19: a protocol for systematic review and meta-analysis. *Medicine*. 2020;99(32):e21380.
8. Moores LK, Tritschler T, Brosnahan S. Prevention, diagnosis, and treatment of VTE in patients with coronavirus disease: CHEST Guideline and Expert Panel Report. *Chest*. 2019;158(3):1143-63.
9. Antithrombotic Therapy in Patients with COVID-19. Available at: <https://www.covid19treatmentguidelines.nih.gov/the-rapies/antithrombotic-therapy>. Accessed on 11 February 2021.
10. Tang N, Bai H, Chen X, Gong J, Li D, Sun Z. Anticoagulant treatment is associated with decreased mortality in severe coronavirus disease 2019 patients with coagulopathy. *J Thromb Haemost*. 2020;18(5):1094-9.
11. Talasaz AH, Sadeghipour P, Kakavand H, Aghakouchakzadeh M, Tassell B, Kordzadeh-Kermani E, et al. Antithrombotic therapy in COVID-19: systematic summary of ongoing or completed randomized trials, 2021.
12. Jimenez D, Garcia-Sanchez A, Rali P, Muriel A, Bikdeli B, Ruiz-Artacho P, et al. Incidence of VTE and bleeding among hospitalized patients with coronavirus disease 2019: a systematic review and meta-analysis. *Chest*. 2020;159(3):1182-96.
13. González C, Penado S, Llata L, Valero C, Riancho JA. The clinical spectrum of retroperitoneal hematoma in anticoagulated patients. *Medicine (Baltimore)*. 2003;82(4):257-62.
14. Balkan C, Kavakli K, Karapinar D. Iliopsoas haemorrhage in patients with haemophilia: results from one centre. *Haemophilia*. 2005;11(5):463-7.
15. Llitjos JF, Daviaud F, Grimaldi D. Ilio-psoas hematoma in the intensive care unit: a multicentric study. *Ann Intensive Care*. 2016;6:8.
16. Cattaneo M, Bertinato EM, Birocchi S, Brizio C, Malavolta D, Manzoni M, et al. Pulmonary Embolism or Pulmonary Thrombosis in COVID-19? Is the Recommendation to Use High-Dose Heparin for Thromboprophylaxis Justified? *Thromb Haemost*. 2020;120(8):1230-2.
17. Nannoni S, de Groot R, Bell S, Markus HS. Stroke in COVID-19: A systematic review and meta-analysis. *Int J Stroke*. 2021;16(2):137-49.

**Cite this article as:** Atanasov TD, Todorova KT, Tsvetanov AI. Spontaneous retroperitoneal hematoma in COVID-19 patients. *Int Surg J* 2022;9:1464-9.