

Original Research Article

Role of laparoscopy in complicated appendectomy

Desh Pal Singh, Sharadendu Bali, Maneshwar Singh Utaal*

Department of Surgery, Maharishi Markandeshwar Institute of Medical Sciences and Research, Mullana, Ambala, Haryana, India

Received: 22 September 2016

Accepted: 26 September 2016

***Correspondence:**

Dr. Maneshwar Singh Utaal,

E-mail: maneshwar@live.com

Copyright: © the author(s), publisher and licensee Medip Academy. This is an open-access article distributed under the terms of the Creative Commons Attribution Non-Commercial License, which permits unrestricted non-commercial use, distribution, and reproduction in any medium, provided the original work is properly cited.

ABSTRACT

Background: There is definitely added advantage of laparoscopic operations in the form of lesser hospital stay, lesser wound infection, early work resumption, lesser pain and agony to patients. Most of the surgeons now prefer these minimally invasive procedures. Laparoscopy has become the number one choice of educated and affording patients.

Methods: This is a retrospective study of perforated and gangrenous appendix in the patients operated in our hospital during the last five years. The parameters studied were age of the patients, sex, episode number, duration of pain before presentation in hospital, operative time, conversion rate, wound infection, post-operative intra-abdominal abscess formation, stay in hospital and expenditure on surgery for disposables and antibiotics.

Results: It was seen that average operative time in open surgery was 67.5 minutes and 104 minutes in laparoscopic surgery, with a conversion to open in about 20% of the cases. Oral feeding in the open group was around the 5th day while it was around 2nd day in the laparoscopic group. Average hospital stay was also low in the laparoscopic group, being only around 5 days in laparoscopic group and around 8 days in the open group. Overall complications were also low in the laparoscopic surgery group.

Conclusions: It was noted that though conversion to open operation was definitely high but there were other advantages of laparoscopic surgery as well. Stay in the hospital, beginning of oral feeds, requirement of analgesics, wound infection, intra-abdominal abscess; pulmonary complications were less in laparoscopy group.

Keywords: Appendectomy, Open vs laparoscopic appendectomy

INTRODUCTION

In present era of minimal access surgery most of the surgeons are very well trained in laparoscopic surgical maneuvers in hepatobiliary, resection-anastomoses of gut, anal surgeries, thoracic and urological operations. The surgeons have now started doing more complex operations due to increased sophistication, availability of good quality of instruments and growing surgical experience. These things have also improved the final outcome of any kind of surgery simple or complicated. There is definitely added advantage of laparoscopic operations in the form of lesser hospital stay, lesser wound infection, early work resumption, lesser pain and

agony to patients. In obese patients the time taken for operations is more but there are fewer complications with minimal access surgery as compared to open procedures. Even in first trimester of pregnancy laparoscopic appendectomy and other operations are safer with laparoscopy.¹ Most of the surgeons now prefer these minimally invasive procedures. Laparoscopy has become the number one choice of educated and affording patients. Acute appendicitis has many complications at the time of presentation because of waiting for spontaneous recovery, delay in diagnosis by peripheral health care workers or reluctance of patients for undergoing operation due to financial constraints. We analyzed the data in our hospital of patients who were operated in previous years for different surgeries.

Complicated acute appendicitis was one category for this analysis. As mentioned in the surgical text books the following are the complication of acute appendicitis.²

- Perforation of appendix and then appendicular abscess
- Appendicular mass
- Mucocele of the appendix
- Neoplasms of appendix (operative or post-operative diagnosis)
- Peritonitis
- Intestinal obstruction

Diagnosis of acute appendicitis

The diagnosis of acute appendicitis may be straight forward or difficult in some situations. The criteria used for diagnosis of acute appendicitis are;

- History of pain abdomen with localization of pain in right iliac region
- Constitutional symptoms
- Clinical examination of patient
- Blood examination
- Biochemical test e.g. C-reactive proteins
- Radiological examination USG, CT and MRI scan

All these investigations are available in most of the hospitals. The diagnosis of acute appendicitis and its complications can be done easily with surety. We did a retrospective comparative study of eighty-one patients of perforated appendix. We did not consider the other complicated cases like appendicular mass, peritonitis or intestinal obstruction. The patients with mass was treated conservatively and later on operated by open or laparoscopically when resolved. The technique for surgery used in our hospital was same as is being used in other places both for open and laparoscopy.

Method adopted for laparoscopic appendectomy

Experience of a surgeon

Ours is a teaching hospital and we have senior faculty of laparoscopic surgeons. The senior surgeons in this hospital are available round the clock and most of the emergency and routine operations are done by them only, particularly complicated cases. The surgical faculty has good laparoscopic experience.

Use of multiport

We used multiport method for appendicular perforation. The surgeons were more comfortable with multiport. Moreover, we do not have single port laparoscope and accessories in our hospital.

Appendicular stump closure

In our cases we close the appendicular stump with Vicryl no. 3-0 suture ligation very securely. This suture has less chances of slippage and so leakage from the stump.³ The chances of intra-abdominal abscess formation may be higher due to fragile nature of necrotic appendicular tissue.⁴ In complicated acute appendicitis the caecal wall is always edematous or gangrenous, the stump of appendix was not buried with Z suture or encircling the caecal wall.

Peritoneal lavage

In all our cases we did peritoneal lavage very meticulously and sincerely.⁵ The thorough lavage reduced postoperative intra-abdominal abscess and peritonitis.⁶ The European guideline also recommends thorough peritoneal lavage and aspiration in complicated appendicitis.⁷ Though the use of peritoneal lavage is a controversial issue because of fear of spreading the infection in whole abdominal cavity.⁸ Some studies show no added advantage of peritoneal lavage.

Drainage of abdomen

We routinely employed drainage of abdominal cavity to reduce post-operative fluid collection and intra-abdominal infection. It is also recommended in the literature.¹⁰ But controversy exist with this issue also.^{11,12}

Open surgical procedure

In open surgical procedure the conventional method of removal of appendectomy was employed. We started with Rutherford Morison muscle cutting incision for easy approach, incision was increased laterally and medially when required. Appendectomy was done as described in standard text books. Purse string sutures or Z- suture were not used as there was edema or gangrenous caeca wall. Many surgeons also believe that invagination of the stump is not necessary.

It was not possible to crush the inflamed and fragile appendix. Caecal wall was closed with absorbable suture after dividing the diseased appendix.

METHODS

We did a retrospective study of perforated and gangrenous appendix in the patients who came and got operated in our hospital during the last five years. Twenty nine patients were operated laparoscopically and fifty two cases were operated with open approach. Pre-operative diagnosis was established by clinical examination, blood investigations and radiological findings and was confirmed intra-operatively. The parameters studied were age of the patients, sex, episode number, duration of pain before presentation in hospital, operative time, conversion rate, wound infection, post-operative intra-abdominal abscess formation, stay in hospital and expenditure on surgery for disposables and antibiotics.

All patients received preoperative antibiotics a third generation cephalosporin, IV fluids, analgesics. Laparoscopic appendectomy was performed using three port methods. Pneumoperitoneum was created with Veress needle in subumbilical region and a 10 mm port was inserted for telescope. A 10 mm port was placed in supra pubic region under vision for dissection. A 5mm port was placed in left iliac region. Dissection was done with Maryland forceps and with the help of cautery. Appendix was transfixed doubly with a vicryl 3-0, on needle suture ligation to avoid slippage. This trans fixation was performed in all cases whether abscess or gangrene. Appendix was removed in a specimen bag. Thorough peritoneal lavage was done with hot normal saline and Betadine solution because all these cases were the infected. Peritoneal drains were kept to clean out any left lavage fluid.

Antibiotics were given intravenously for three days and orally for five days' post operatively. Oral intake allowed gradually and all the patients were fully oral on fourth or fifth postoperative day. All the patients were mobilized on the third or fourth postoperative day. Patients were discharged on seventh post-operative day after removal of stitches. Complications of the procedure were noted during hospital stay. Patients were followed weekly in first month, fortnightly for two months and monthly for six months. Total follow up was planned for ninth months. Some of the patients did not complete the full follow up period and were absent after few visits.

RESULTS

Analysis of variables like age, sex, operative time, amount of analgesics used, hospital stay and expenditure

on surgery was done. Complications noted were wound infection, intra-abdominal abscess formation and post-operative ileus. The other parameters studied were episode number, duration of pain before presentation in hospital and conversion rate.

Age

Out of eighty-one complicated cases of acute appendicitis most of the patients were young and had good physical health.

Sex

There was slight dominance of female over male patients.

Episode number

The sequence number of clinical episode of appendicitis in our series was noted as first and second. With more episodes the appendix becomes fibrosed and less vulnerable to infection and inflammation.

Duration of pain and other symptoms

Pain was present for four to five days before coming to hospital. Pulse, temperature, respiratory rate, mild abdominal distension and guarding were present in almost all cases and were related to duration of pain. Late reporting to hospital was due late referral and financial constraints.

All these above factors were common in both groups.

Table 1: Open vs. laparoscopic surgery.

	Average operative time	Conversion rate	Oral feed started post operatively (average)	Average hospital stay
Open surgery	67.5 minutes	N/A	Post-operative day: 5	8 days
Laparoscopic surgery	104 minutes	6/29 = 20%	Post-operative day: 2	5 days

Operative time

- Open Surgery: 67.5 (52-83) min
- Laparoscopic surgery: 104 (81-127) min

Conversion rate

- Open Group: N/A
- Laparoscopy surgery: 6/29 ≈20%

Return to oral feeds

- Open group: ≈5th day
- Laparoscopy group: ≈ 2nd day

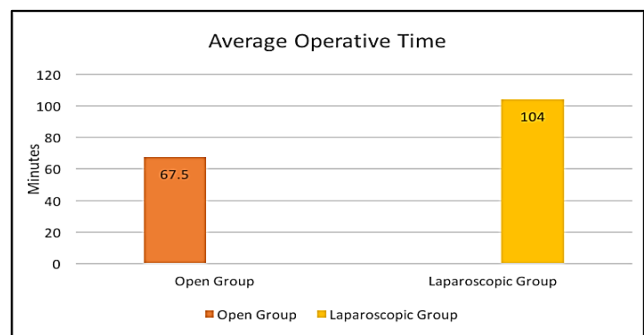


Figure 1: Average operative time in open and laparoscopic surgery.

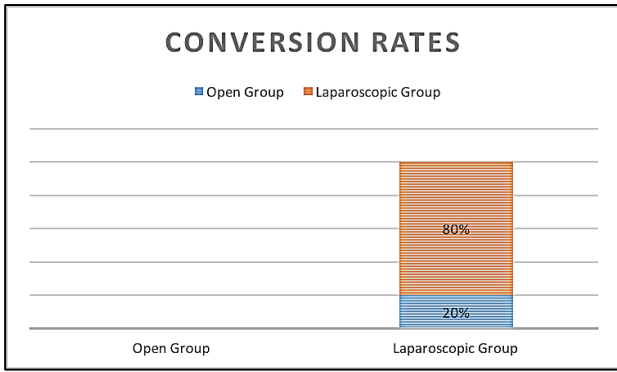


Figure 2: Conversion rates from one form of surgery to the other.

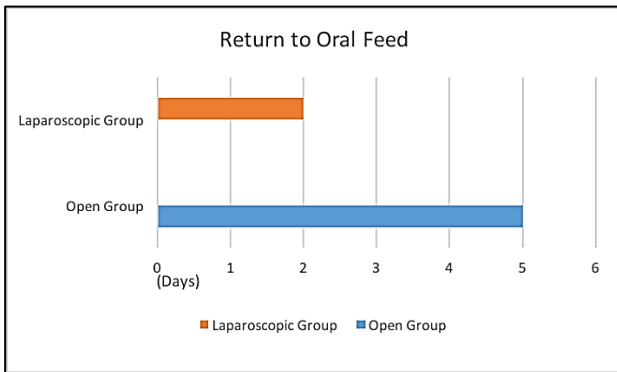


Figure 3: Average number of days to return to oral feed post-surgery.

Hospital stay and discharge

- Open group: $\approx 8^{\text{th}}$ day
- Laparoscopy group: $\approx 5^{\text{th}}$ day

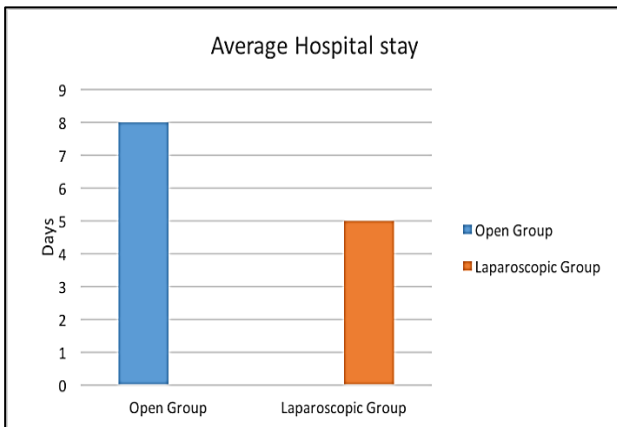


Figure 4: Average hospital stay in each group.

Analgesics used

In open group we have to use analgesics more frequently. The analgesics used were diclofenac sodium and tramadol. No other strong opioids were needed.

Post-operative complications

- Wound infection
- Open group: 23/52 $\approx 44\%$
- Laparoscopy group: 6/23 (6 cases were converted). $\approx 26\%$

Intra-abdominal abscess

- Open group: 2/52=3.8%
- Laparoscopy group: 2/23=8.6%

Pulmonary complications

- Among 81 patients 7 had pulmonary symptoms due to previous respiratory diseases e.g. asthmatic bronchitis, healed pulmonary tuberculosis, 5 in open and 2 in laparoscopy group. Except these patients none developed pulmonary complications due to active physiotherapy and early ambulation.
- *Open category:* Nil
- *Laparoscopy group:* Nil

Prolonged ileus and obstruction

- The incidence of prolonged ileus was more in laparoscopy group most likely due to pneumoperitoneum.
- Open group: 1/52=3.8%
- Laparoscopy group: 2/23=8.6%

No other complications occurred in this series.

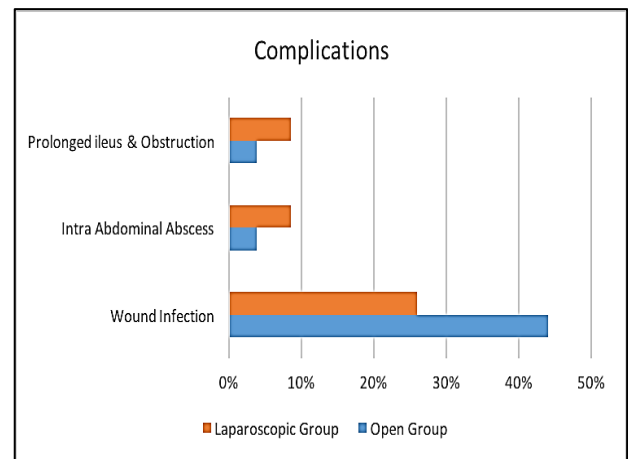


Figure 5: Complications.

Expenditure on operation

- Overall cost of open surgery was minimally higher.
- The operative cost in both the groups was almost same. There was not much difference. This was because ours is a teaching hospital not a commercial establishment. No other extra money was charged in the name of laparoscopy.

DISCUSSION

Our study is not based on a large sample size but we can find some trend. Operative time was a little more in laparoscopic appendectomy. It was about thirty minutes more. Conversion to open operation was definitely high though there were other advantages of laparoscopic surgery. The cost of both the procedures in our hospital was almost same. Stay in the hospital, beginning of oral feeds, wound infection, intra-abdominal abscess; pulmonary complications were less in laparoscopy group. A study by Yau K et al, where a similar comparative study in 1,133 patients was done showed 42 patients with complicated appendicitis.¹³ The mean hospital stay was 5 days in the Laparoscopic group which was the same in our study whereas the study had an average hospital stay of 6 days as opposed to 8 days in our open surgery group. Another study by Pokala N in which a total of 104 patients were studied, 43 underwent laparoscopic and 61 underwent open surgeries.¹⁴ There was a slight predominance in number of females as was seen in our study. The conversion rate in the study was 18.6% which was quite similar and around 20% in our study. Overall complications rate was higher in Laparoscopic group than in open group. Another study by Garg CP which studied a total of 110 patients, 61 of whom underwent open appendectomy and the rest 49 underwent Laparoscopic appendectomy.¹⁵ Operative time was noted to be higher in laparoscopic surgery as was in our study, also it was noted that laparoscopic surgery was associated with less analgesic use, shorter hospital stay. Thus it can be noted that laparoscopic surgery for complicated appendicitis is safe and feasible. It has less postoperative pain, lower infectious complications and short hospital stay when compared with patients who had an open surgery.

Funding: No funding sources

Conflict of interest: None declared

Ethical approval: The study was approved by the institutional ethics committee

REFERENCES

- Williams N, O'Connell PR. A short practice of surgery: Bailey and Love, 26th edition. United States of America: CRC Press; 2013:1210.
- Bhat SR. SRB'S manual of surgery. 4th edition. New Delhi: Jaypee brothers; 2013:1007-1016.
- Beldi G, Vorburger SA, Bruegger LE, Kocker T, Inderbitzin D, Candinas D. Analysis of stapling versus endoloops in appendiceal stump closure. Br J Surg. 2006;93:1390-3.
- Sahm M, Kube R, Schmidt S, Ritter C, Pross M, Lippert H. Current analysis of endoloops in appendiceal stump closure. Surg Endosc. 2011;25:124-9.
- Ohno Y, Furui J, Kanematsu T. treatment strategy when using intraoperative peritoneal lavage for perforated appendicitis in children: a preliminary report. Pediatr Surg Int. 2004;20:534-7.
- Agresta F, Ansoloni L, Baiocchi GL, Bergamini C, Campanile FC, Carlucci M, et al. Laparoscopic approach to acute abdomen from the Consensus Development Conference of the Societa Italiana di Chirurgia Endoscopica e nuove tecnologie (SICE), Associazione Chirurghi Ospedalieri Italiani (ACOI), Sositeta, Italiana di Chirurgia (SIC), Sositeta, Italiana di Chirurgia d'Urgenza e del Trauma (SICUT), Sositeta, Italiana di Chirurgia nell'Ospedality Privata (SICOP) and the European Association for Endoscopic Surgery (EAES). Surg Endosc. 2012;26:2134-64.
- Moore CB, Smith RS, Herbertson R, Toves C. Does use of intraoperative irrigation with open or laparoscopic appendectomy reduce post-operative intra operative abscess? Am Surg. 2011;77:78-80.
- St Peter SD, Adibe OO, Iqbal CW, Fike FB, Sharp SW, Juang D, et al. Irrigation versus suction alone during laparoscopic appendectomy for perforated appendicitis: a perspective randomized trial. Ann Surg. 2012;256:581-5.
- Schein M. To drain or not to drain? The role of drainage in the contaminated and infected abdomen: an international and personal perspective. World J Surg. 2008;138:314-24.
- Pessaux P, Msika S, Atalla D, Hay JM, Flammant Y. Risk factors for postoperative infectious complication in noncolorectal abdominal surgery : a multivariate analysis based on a prospective multicenter study of 4718 patients. Arch Surg. 2003;138:314-24.
- Sleem R, Fisher S, Gestring M, Cheng J, Sangosanya A, Stassen N, et al. Perforated appendicitis: is early laparoscopic appendectomy appropriate? Surgery. 2009;146:731-7.
- Masoomi H, Mills S, Dolich MO, Ketana N, Carmichael JC, Nuguen NT, et al. Comparison of outcomes of laparoscopic versus open appendectomy in adults; data from the Nationwide Inpatient Sample (NIS), 2006-2008. J Gastrointest Surg. 2011;15:2226-31.
- Yau K, Siu W, Tang C, Yang G, Li M. Laparoscopic versus open appendectomy for complicated appendicitis. J Am College Surg. 2007;205(1):60-5.
- Pokala N, Sadhasivam S, Kiran RP, Parithivel V. Complicated appendicitis-is the laparoscopic approach appropriate? A comparative study with the open approach: outcome in a community hospital setting. Am Surg. 2007;73:737-41.
- Garg C, Vaidya B, Chengalath M. Efficacy of laparoscopy in complicated appendicitis. Intern J Surg. 2009;7(3):250-2.

Cite this article as: Singh DP, Bali S, Utaal MS. Role of laparoscopy in complicated appendectomy. Int Surg J 2016;3:1746-50.