

Original Research Article

Evaluation of outcomes after coverage of exposed tibia with propeller-based perforator flaps

Manas Sasmal¹, Pritam Das², Meheraj Seikh³, Naveen Kumar^{4*}

¹Department of Plastic and Reconstructive Surgery, IPGME and R and SSKM Hospital, Kolkata, West Bengal, India

²Department of Plastic and Reconstructive Surgery, AGMC and GBP Hospital, Agartala, Tripura, India

³Department of Plastic Surgery, R. G. Kar Medical College, Kolkata, West Bengal, India

⁴Department of Plastic Surgery, Kailash Hospital, Greater Noida, Uttar Pradesh, India

Received: 16 May 2022

Revised: 31 May 2022

Accepted: 01 June 2022

*Correspondence:

Dr. Naveen Kumar,

E-mail: drnaveenvmmc@gmail.com

Copyright: © the author(s), publisher and licensee Medip Academy. This is an open-access article distributed under the terms of the Creative Commons Attribution Non-Commercial License, which permits unrestricted non-commercial use, distribution, and reproduction in any medium, provided the original work is properly cited.

ABSTRACT

Background: For small-and medium-sized soft-tissue defects in lower one third of leg without any degloving injury, the perforator propeller flaps are the authors preferred choice. With the study we shall present our experience with the use of three (tibio-peroneal system) perforator-based propeller flaps in the reconstruction of distal leg defects.

Methods: A prospective study was conducted in the department of plastic and reconstructive surgery, over a period of 20 months from 1st January 2017 to 30th September 2018. All patients with small to large sized soft tissue defects affecting lower third of tibia were included in the study. Various findings were recorded and analyzed.

Results: Among the affected areas that required coverage of soft tissues of the leg, in order of frequency, the middle third represented 15 cases (62.5%), and in the distal third 9 cases (37.5%). Flap dimensions ranged from 12 to 156 cm², with an average size of 50 cm². The flap rotation was 180 degrees in 19 cases (79.17%), 140 degrees in 3 cases (12.50%), and 160 degrees in 2 cases (8.33%). The flaps were based on a single perforating vessel of the posterior tibial artery in 12 cases (50%) of the cases; on the anterior tibial artery in 09 cases (37.5%), and in 3 cases (12.5%) the peroneal artery was chosen. Complications were present in 14% of the flaps.

Conclusions: We concluded that the perforator-based propeller flaps are ideal in reconstructing small-medium defects of the middle and distal third of the leg.

Keywords: Defect, Reconstruction, Propeller, Flap, Perforator

INTRODUCTION

Covering a soft-tissue defect over the tibial crest possess a challenge to reconstructive surgeon. Reconstruction of defect in leg has number of anatomical constraints such as paucity of loose tissues in the vicinity; abundance of subcutaneous bone and its prominences results in devitalization of fracture fragment easily because of periosteal stripping; tendinous nature of muscles in this region, which may result in the exposure of the tendons with pedicled flaps which can also lead to unstable scar after skin grafting of donor site); there is also reduced

blood supply here; the circumference of the lower third leg is relatively smaller which may easily compromise lymphatic drainage, and poor wound healing; and lastly, the distal ankle and foot regions are considered as high pressure zones which make these regions as poor donor sites.

The post-traumatic vascular injury in the lower extremities makes the local and regional vessels poor candidates for the microvascular reconstruction, usually a preferred choice for reconstruction in lower third of leg. Due to all these constraints, the armamentarium of the

reconstructive surgeons has narrowed down to very few choices. There are options like conventional or flow-through free flap and free flaps with cross-leg construction or microvascular loops for the coverage of chronic wound, which require the microsurgical expertise. Whereas, for small- and medium-sized soft-tissue defects in lower one third of leg without any degloving injury, the perforator propeller flaps are the authors preferred choice. These are the islanded fasciocutaneous flaps having two unequal blades which can be rotated around single best perforator up to 180° in such a way that large blade and small blade can cover the primary defect and the donor site defect respectively. They have eliminated donor site morbidity. The propeller flaps have robust blood supply. These flaps preserve all the cutaneous nerves, large named subcutaneous veins and source axial vessels. As a result, in this region, the perforator propeller flaps can be raised based on the perforators arising from posterior tibial, anterior tibial and peroneal vessels.

With the study we shall present our experience with the use of three (tibio-peroneal system) perforator-based propeller flaps in the reconstruction of distal leg defects. Perforator-based propeller flap is a reliable option for the coverage of soft tissue defects in leg region when other options are not feasible.

The objectives of the study were to design various flaps based on perforators in the lower limb, to standardize the technique of harvest of perforator/propeller flap, to understand the physiology of blood supply to the flap, to ascertain the usefulness of these flaps in planning reconstructive surgery and to improve the aesthetic and functional outcome and reducing local morbidities.

METHODS

A prospective study was conducted in the department of plastic and reconstructive surgery, over a period of 20 months from 1st January 2017 to 30th September 2018. All patients with small to large sized soft tissue defects affecting lower third of tibia were included in the study. All the details of the patient were recorded; various findings during pre-operative, intra-operative, postoperative and follow up periods were collected and analyzed. The patients were explained about the nature of the defect and the various flap options available. The proposed procedure was explained to the patient in detail including its merits and demerits. Informed and written consent was obtained from the patient. The detailed proforma of the study was submitted before the institution ethical committee and approval obtained.

Patients in the age group of 10-60 years, who were having defect with exposed tibia in lower extremities where primary skin grafting cannot be done and needing reconstruction as one stage procedure, were included for the study. Whereas, patients with peripheral vascular diseases, in cases where advancement, transposition

perforator flap and free style free flap possible, patients with extensive tissue defects that cannot be covered with fascial flaps and patients with Gustillo-Anderson type 3B open fracture tibia were excluded from study.

Preoperative preparation

All patients who needed wound care were admitted and advised limb elevation. Thorough debridement of wound done on day one and appropriate antibiotics were given according to culture and sensitivity, if needed. All comorbidities (including type 2 DM) were treated beforehand. Smokers were planned after a two weeks period of complete abstinence of smoking. A hand-held Doppler ultrasound with 8 to 10 MHz frequency probe is used to mark the dominant perforator.

Preoperative flap planning

The propeller flap is identified as a local island fasciocutaneous flap based on a single dissected perforator. It has a design similar that of a propeller with 2 blades of unequal length with the perforator forming the pivot point so that when the blades are switched, the long arm comfortably fills in the defect. The flap has an ability to rotate any angle up to 180° . A proximally based fasciocutaneous flap is unable to get enough healthy tissue into the defect and it tends to expose either the subcutaneous border of the tibia or the Achilles tendon. The propeller flap avoids these problems. In doing so it simultaneously transfers the secondary defect to an easily graftable area over proximal muscle bellies (Figure 1).

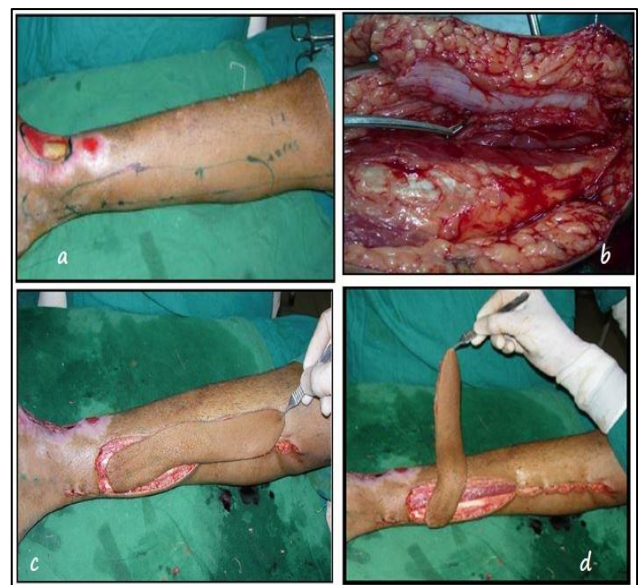

Figure 1 (A-D): A defect in the lower one third of leg, distally based PTAP flap marked with two perforators marked (x) adjacent to the defect with a hand-held Doppler; PTA perforator is shown with peri perforator dissection; PTAP flap islanded on the perforator is shown; PTAP flap rotated 160° in counter clock wise.

When the rotation is needed only up to 90° it may not matter if more than one pedicle is kept, when the flap is needed to rotate 180° it is actually safer to divide all perforators except one.

Operative procedure

All patients were operated under general/ regional anesthesia under the loupe magnification. Patients were positioned according to the defect and flap. A tourniquet was applied. Flap design was drawn, with the perforator as the pivot point of the flap. First, the distance was measured between the perforator and the distal edge of the defect. To this value, 1 cm is added is then added and then it is transposed proximally along the vascular axis, measured from the perforator, to form the proximal limit of the flap. Next, the width of the flap was determined approximately similar to the width of the defect (Figure 1 and 2).

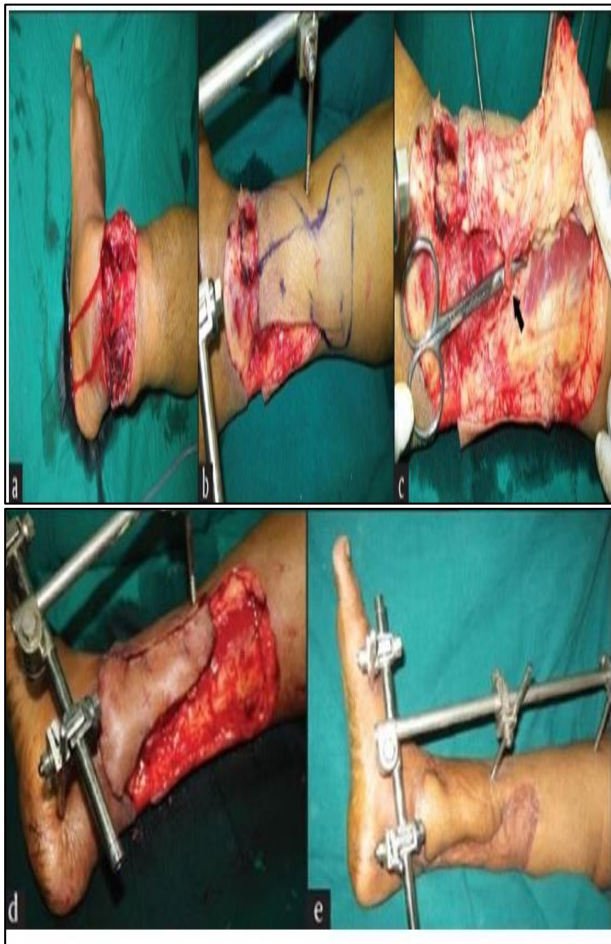


Figure 2 (A-E): A major crush injury of the lower third of the leg, the defect after debridement and the Doppler examination showed good audible signals at X, and a flap marked, the proposed flap elevated on one side and the perforator visualized before the whole flap is raised, the flap raised and rotated through 180 degrees to cover the critical area and a well-settled flap and the healed donor area.

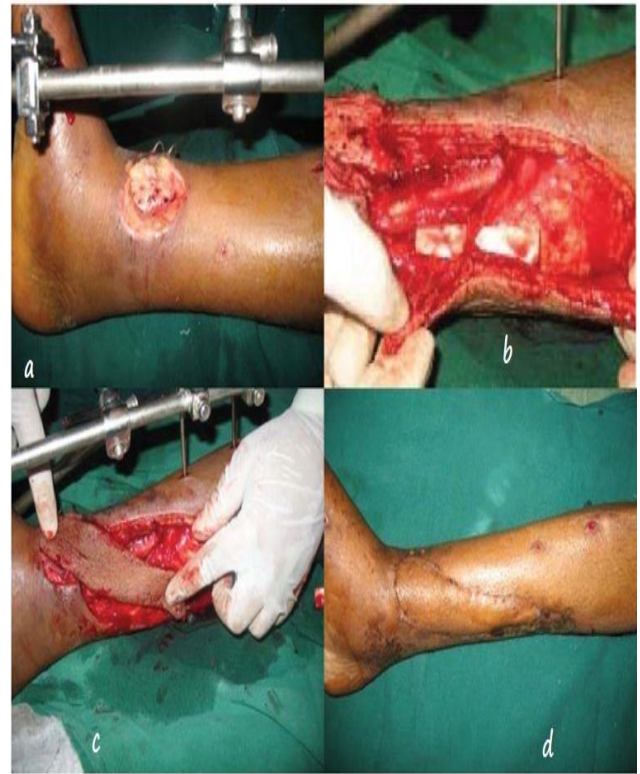

Figure 3 (A-D): PNAP flap for coverage of exposed tibia.

First incision was made at one side of the marked flap retracted to locate the marked perforators. A subfascial approach was made to visualize the pedicle.

With this initial incision, the best perforator was chosen based on its position and size and by micro-clamping to ascertain the flap perfusion.

When the decision was made, the perforator that was finally chosen for the flap and with the best pedicle chosen, the design of the flap was completed and, if necessary, adjusted. We ensured that the proximal edge of the flap should reach the distal margin of the defect comfortably and would not place the perforator under any tension. Particular attention was paid to the fascial strands around the venae comitantes which were divided carefully to avoid extrinsic compression once the flap is rotated into position. Then the flap was completely islanded, it was left in its donor area and the tourniquet was released and hemostasis was secured.

Topical lignocaine was instilled around the perforator. Once the flap perfusion was confirmed, the flap was carefully lifted and pivoted around its pedicle to cover the defect. First the flap was turned clockwise into the defect and was positioned to look for any sign of extrinsic compression of venae comitantes by residual fascial strands. Then we turned the flap counterclockwise and examined the pedicle. The direction of rotation where venae comitantes were safer was selected.

Then the flap was secured in position with the first 2 skin sutures placed on either side of the axis of the pedicle. Then the inset of rest of the flap was done. The donor defect was closed either primarily without excessive tension or with skin graft. Sterile loose dressing was done.

Post operative care

Immobilization of the operated region was done with appropriate splint. Limb was kept elevated. Flap was monitored once in four hours for the first 48 hours and then once daily. Complete sutures were removed by 12th POD. POP immobilization continued for 2 weeks. The patient was allowed to ambulate once the flap and graft settled well. Follow up was done up to 6 months.

RESULTS

Perforator/propeller flaps for reconstruction of soft tissue defects over the lower limb were used in 24 patients (18 males and 6 females). The age of patients was ranged from 19 yrs to 60 yrs. A total of 24 flaps were used for the coverage of defects localized at the middle and distal third of the leg, caused by trauma, with age ranging from 19 to 60 years (mean, 32 years), with an interquartile range of 25 and 42, male sex being the most frequent in 18 cases (75%). Among the patients, 3 had comorbidities of diabetes mellitus and 2 had hypertension.

Among the affected areas that required coverage of soft tissues of the leg, in order of frequency, the middle third represented 15 cases (62.5%), and in the distal third 9 cases (37.5%). Flap dimensions ranged from 12 to 156 cm², with an average size of 50 cm² with interquartile range of 30 and 60 cm.² The flap rotation was 180 degrees in 19 cases (79.17%), 140 degrees in 3 cases (12.50%), and 160 degrees in 2 cases (8.33%).

The flaps were based on a single perforating vessel of the posterior tibial artery in 12 cases (50%) of the cases; on the anterior tibial artery in 09 cases (37.5%), and in 3 cases (12.5%) the peroneal artery was chosen.

Complications were present in 14% of the flaps. These included 3 partial necrosis less than a 15% of the flap, which were all based in the posterior tibial artery, and 1 case with an epidermolysis of the flap based in the anterior tibial artery without a statistical difference with respect to the artery used to base the flap. Female patients presented complications in 42.9% with a tendency toward statistical significance (p=0038) according to sex.

Primary closure of the donor site was performed in 17 cases (70.83) of which 16.7% (4) had complications. The registered complications of partial necrosis and epidermolysis of the flaps were among the group in which the primary closure of the donor site was treated with a partial thickness skin graft, which had a 100% integration.

Table 1: Intra and post operative findings.

Variables	No. of patients, (n=24)	Percentages (%)		
Location of defect				
Middle third	15	62.5		
Lower third	09	37.5		
Degree of rotation				
180°	19	79.17		
140°	03	12.5		
160°	02	08.33		
Origin of perforating vessels				
Posterior tibial artery	12	50		
Anterior tibial artery	09	37.5		
Peroneal artery	03	12.5		
Complications of flap				
Complications of flap	Origin of perforator	Sex of patient	No. of cases	
Epidermolysis	Posterior tibial artery	Female	01	
Partial flap necrosis	Posterior tibial artery	Female	03	
Donor-site closure				
Primary closure	17	70.83		
STSG	07	29.16		

DISCUSSION

Propeller perforator flaps are considered as reliable and useful options for the coverage of mid and distal third defects of the leg, where a flap can be designed based upon perforators in relation to the location and dimension of the defect.

Local flaps are the preferred options for coverage of proximal thirds of the leg, whereas, free flaps are reserved as options for the distal third of the leg and foot, with lack of local tissues to base locoregional flaps.¹⁻³ However, the use of fasciocutaneous local flaps based upon fascial plexus in the 1980s by Pontén and Hallock, introduced newer options for the reconstruction of the defects of the lower extremity.^{4,13} Nakajima et al had subsequently proved that those fascial plexus was supplied by deep fascial perforating vessels arising from the underlying main vessels.⁵

Further research into the application of flaps has resulted into the development of perforator flaps. The perforator flaps have been developed from musculocutaneous and fasciocutaneous flaps when the underlying muscle or fascia are not being utilized in the form of irrigation transporters, which has driven our interest in using these flaps which has an advantage of coverage of the defect allowing primary closure of donor site, in small size defects. The flaps made had an average dimension of 48 cm,² similar to what shown by Morris et al with

perforating vessel of 0.7 cm supply an area of 47 cm² and may even extended further as described by Gir et al of 67.1 sq. cm.⁶⁻⁸

The ability to rotate the propeller perforator flaps up to 180 degrees, which we performed in 79.17% of the cases, makes it extremely versatile to reconstruct defects of the middle and distal third of the leg, as has been reported in other series.^{3,7,9,10}

In our study, we found 4 complications (16.67%), 3 partial necrosis, and a superficial epidermolysis, which is lower than that reported in the meta-analysis performed by Ger et al reporting complications of 25.8%, with partial necrosis being the more common in 12.5%.⁷ The percentage of complications is similar to that of free flaps, 16-38%, and in terms of total necrosis is lower, because in free flaps it is 4-19%, compared with 1.1% in propeller perforating flaps.^{1,11-13}

Another possible described factor that may be associated with partial necrosis of the flaps is the inclusion of scar tissue in the flap design, or excessive tension in the closure of the defect.¹⁴ This is why sometimes recommended the split thickness skin graft for the donor site of the flap, which will always become a more common option as the defect is more distal, due to the lack of displacement of the tissues in the leg, as we did in 29.16 % of the cases.

Although no differences have been found in the relationship of flap complications and sex, in the present study it was found that in the female sex there is a certain association with complications, which may be related to hormonal effect on the venous system, although the sample size of female patients was low.^{5,7,16}

A manual unidirectional acoustic Doppler is a useful tool in using the perforator flaps, in all patients preoperatively as a guide for vessel location.^{17,18} In our study, we had used a handled Doppler with a 8 MHz probe. Khan and Miller used a hand held doppler with 8-10 MHz probes, with sensitivity of 90% with a confidence interval of up to 95%, positive predictive value of 84% with a reliability interval of 74-91%.¹⁸ The transducer is angled approximately 45 degrees to the surface of the skin, and not parallel to the skin which may increase the possibility that the source vessel will be selected instead of a perforator.¹⁸

The flap can be redesigned with trans operative confirmation of the position of the perforators, as we did in 3 occasions when we had modified the original design, extending proximally to achieve adequate coverage.^{14,19,20}

It has been found that the perforator propeller flaps used to preserve the major vascular axes of the limb and underlying structures, thereby obviating the need for a microsurgical anastomosis and at the same time provides the benefit of tissue-like covering. These flaps provide a

consistent and predictable blood supply, comprising of at least 1 perforating vessel with size more than 0.5 mm, which is long enough for the needed transposition, and also help in closure of the donor site in a primary fashion.

The benefits of the propeller perforator flap involve lower rate of donor site morbidity with primary closure in majority of the cases, reduced functional deficit, versatile flap design, and sparing of underlying muscles.

Its limitation includes the requirement of meticulous dissection in order to identify the perforators with likelihood of damage to the vessels, and finally variability in the location and size of the perforating vessels.

Limitations

The study had been conducted with a smaller number of subjects not enough in drawing more concrete result with statistical evidence. The follow up period is also small to comment upon the long-term healing and settlement of various flaps.

CONCLUSIONS

Based on the results obtained in our study, we consider that the perforator-based propeller flaps are ideal in reconstructing small-medium defects of the middle and distal third of the leg with the advantage of being safer options, replacing the defect with tissues similar in texture and thickness, flap can be elevated easily with lower incidence of donor-site morbidity.

Funding: No funding sources

Conflict of interest: None declared

Ethical approval: The study was approved by the Institutional Ethics Committee

REFERENCES

1. Ger R. The technique of muscle transposition in the operative treatment of traumatic and ulcerative lesions of the leg. J Trauma. 1971;11(6):502-10.
2. McCraw JB, Dibbell DG. Experimental definition of independent myocutaneous vascular territories. Plast Reconstr Surg. 1977;60(2):212-20.
3. Manchot C. The cutaneous arteries of the humanbody. New York: Springer-Verlag; 1982: 105-114.
4. Filatov VP. Plastic procedure using a round pedicle. Vestn Oftalmol. 1917;34:149.
5. Cormack G, Lamberty B. The arterial anatomy of skin flaps. Edinburgh (UK): Churchill Livingstone; 1986: 236-43.366-7.
6. Cormack G, Lamberty B. The anatomical basic for fasciocutaneous flaps. Cambridge (MA): Blackwell Scientific Publications. 1992.

7. Koshima I, Soeda S. Inferior epigastric artery skinflaps without rectus abdominis muscle. *Br J Plast Surg.* 1989;42(6):645-8.
8. Hyakusoku H, Yamamoto T, Fumiiri M. The propeller flap method. *Br J Plast Surg.* 1991;44:53-4.
9. Taylor GI, Palmer JH. The vascular territories (angiosomes) of the body: experimental study and clinical applications. *Br J Plast Surg.* 1987;40(2):113-41.
10. Mardini S, Tsai FC, Wei FC. The thigh as a model for freestyle free flaps. *Clin Plast Surg.* 2003;30(3):473-80.
11. Taylor GI, Daniel RK. The free flap: composite tissue transfers by vascular anastomosis. *Aust N Z J Surg.* 1973;43(1):1-3.
12. McCraw JB, Dibbell DG, Carraway JH. Clinical definition of independent myocutaneous vascular territories. *Plast Reconstr Surg.* 1977;60(3):341-52.
13. Bakamjian VY. A two-stage method for pharyngoesophageal reconstruction with a primary pectoral skin flap. *Plast Reconstr Surg.* 1965;36:173-84.
14. Manchot C. Die hautarterien de menschlichenkorpers. Leipzig: FCW Vogel. 1889.
15. Taylor GI, Daniel RK. The free flap: composite tissue transfer by vascular anastomosis. *Aust N Z J Surg.* 1973;43(1):1-3.
16. Wei FC, Jain V, Suominen S. Confusion among perforator flaps: what is a true perforator flap? *Plast Reconstr Surg.* 2001;107(3):874-6.
17. Rhodin J. The ultrastructure of mammalian arterioles and precapillary sphincters. *J Ultrastr Res.* 1967;18:81-223.
18. Rhodin J. Ultrastructure of mammalian venous capillaries, venules and small collecting veins. *J Ultrastr Res.* 1968;15:452-500.
19. Ponten B. The fasciocutaneous flap: its use in soft tissue defects of the lower leg. *Br J Plast Surg.* 1981;34(2):215-20.
20. Salmon M. *Arteres de la peau.* Paris: Masson. 1936.

Cite this article as: Sasmal M, Das P, Seikh M, Kumar N. Evaluation of outcomes after coverage of exposed tibia with propeller-based perforator flaps. *Int Surg J* 2022;9:1309-14.