

## Case Report

# Spontaneous rupture of the urinary bladder: can COVID predispose?

Shrirang V. Kulkarni\*, Alok K. Pandey

Department of GI Surgery and Liver Transplantation, Army Hospital Research and Referral, New Delhi, India

**Received:** 14 April 2022

**Accepted:** 04 May 2022

**\*Correspondence:**

Dr. Shirrang V. Kulkarni,

E-mail: drsvkq@yahoo.com

**Copyright:** © the author(s), publisher and licensee Medip Academy. This is an open-access article distributed under the terms of the Creative Commons Attribution Non-Commercial License, which permits unrestricted non-commercial use, distribution, and reproduction in any medium, provided the original work is properly cited.

### ABSTRACT

The urogenital tract is a rare source of pneumoperitoneum in peritonitis. Spontaneous rupture of the urinary bladder (SRUB) as a cause is rarer. Preceding severe acute respiratory syndrome coronavirus-2 (SARS-CoV-2) infection predisposing to such eventuality is unprecedented. Experience with such a singular case is presented and discussed.

**Keywords:** Spontaneous rupture of urinary bladder, SARS-CoV-2 infection, Pneumoperitoneum

## INTRODUCTION

Gas under the diaphragm on an erect chest radiograph in a patient presenting with peritonitis is invariably due to hollow viscus perforation, but not always. Uro-genital tract may be the unlikely culprit, mostly following trauma, tumor or tuberculosis.<sup>1</sup> Very rarely (<10 cases in literature) spontaneous urinary bladder perforation has precipitated such emergency, which often has, unfortunately, been overlooked due to poor clinical suspicion with adverse outcomes.<sup>2</sup>

We hereby present an unsuspected case of spontaneous rupture of the urinary bladder (SRUB), which was diagnosed per-operatively and managed at our center.

## CASE REPORT

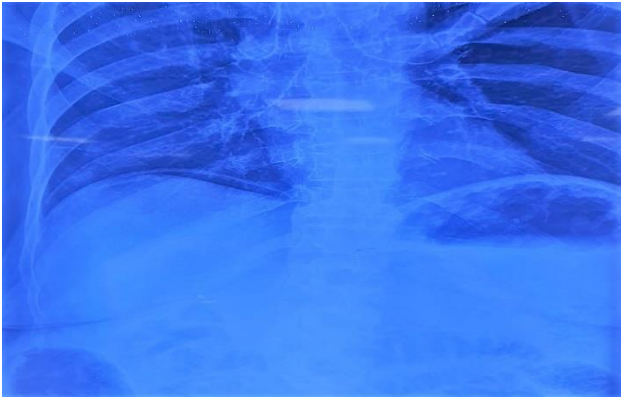
A 72-year-old frail diabetic lady, presented with features of peritonitis of 48 hours duration. There was no preceding history of fever, cough, abdominal symptoms, antacid/steroid medications or trauma.

However, she had recently recovered from severe acute respiratory syndrome coronavirus-2 (SARS-CoV-2) infection and had undergone hysterectomy and cholecystectomy over two decades ago.

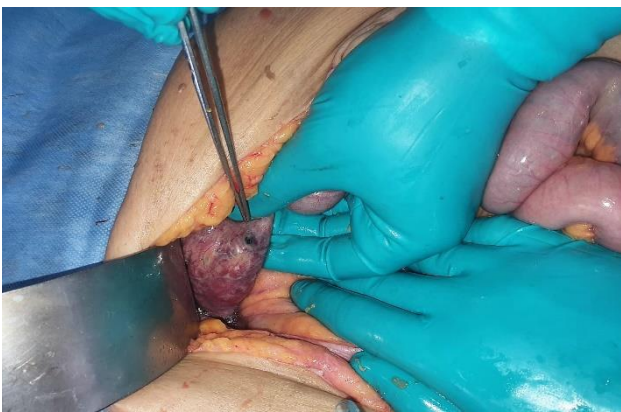Patient was resuscitated for hemodynamic instability with fluids and broad-spectrum antibiotics. Laboratory investigations revealed leukocytosis (21000/cumm) and azotemia (urea 65 mg%, creatinine 3 mg%). Gas under the diaphragm was seen on chest roentgenogram (Figure 1). Based on the above a diagnosis of perforation peritonitis was made and the patient was planned for exploration. However, urinary catheterization drained pus, which was not in sync with the diagnosis.

On exploration, over a liter of foul-smelling purulent exudate was found in the peritoneal cavity, yet no gut perforation was found despite diligent search. However, the urinary bladder was found to be inflamed, unhealthy and thinned out, with a small perforation on its dome (Figure 2). The bladder was repaired after resecting the devitalized portion and abdomen closed over drains after peritoneal toilet.

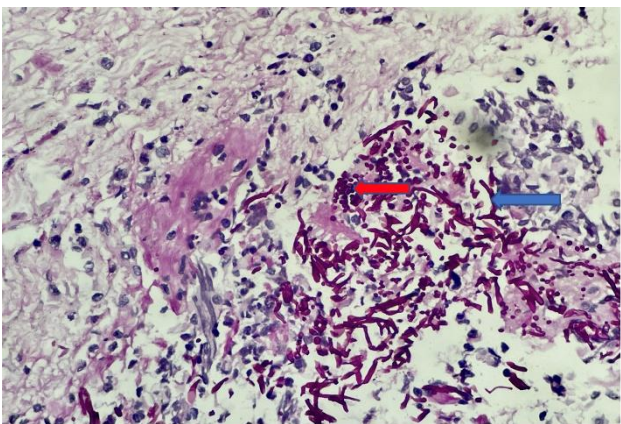
Patient was electively ventilated and intensively treated. Despite the aggressive treatment she succumbed to sepsis on day 6 post surgery. Microbiological cultures from urine, blood as well as the intraperitoneal purulent exudate isolated mixed bacterial growth while histopathology revealed thinned out bladder wall transmurally infiltrated with inflammatory cells and fungal pseudohyphae as well as budding yeast forms of candida species (Figure 3).



**Figure 1: Chest roentgenogram showing gas under diaphragm.**



**Figure 2: Perforation of the urinary bladder.**



**Figure 3: PAS stain demonstrating Candidal pseudohyphae and budding yeast forms.**

## DISCUSSION

Pneumoperitoneum, with features of peritonitis and systemic sepsis, is the sine qua non of gut perforation, mandating exploration. Although spontaneous sealing off is known, the site is usually obvious during surgery. Absent gut source heralds search for alternate sources, the

chief being the bladder and uterus. In our case it had to be the former, consistent with the findings on catheterization. Perforation of any hollow viscus owes to the pressure dynamics in its cavity or the status of its wall or often a combination of both. Age related obstructive lower urinary tract symptoms, which often go overlooked in females, lead to bladder wall weakening, fungal/gram negative (gas producing) bacterial colonization and low-grade cystitis. This coupled with SARS-CoV-2 related cystitis and lowered immunity could have been the trigger for transformation into fulminating cystitis which perforated at its weakest point, the dome, and thence into the peritoneal cavity.<sup>3,4</sup> This would explain the clinical picture and the adverse outcome that gram negative sepsis begets. Imaging is seldom helpful in the absence of a clinical suspicion, as in our case where computed tomography (CT) was not performed, peritonitis being obvious. Even otherwise, sensitivity of CT in diagnosis the condition is <50%.<sup>2</sup>

If diagnosed early, conservative management may be attempted in a stable patient, but never in sepsis where exploration and repair is mandatory, as in our patient. However, sepsis, low immunity and vagaries of age cannot be always fought or won with a knife.

## CONCLUSION

Spontaneous rupture of urinary bladder is a rare cause of pneumoperitoneum and peritonitis. SARS-CoV-2 related inflammation coupled with lower immunity can predispose to fulminant bacterial or fungal cystitis, bladder wall weakening and consequent rupture into the peritoneal cavity with adverse outcome.

*Funding: No funding sources*

*Conflict of interest: None declared*

*Ethical approval: Not required*

## REFERENCES

1. Bacon SK. Rupture of the urinary bladder: clinical analysis of the 147 cases in the past ten years. *J Urol.* 1943;49:432-5.
2. Limon O, Unluer EE, Unay FC. An unusual cause of death: spontaneous urinary bladder perforation. *Am J Emerg Med.* 2012;30:2081-5.
3. Creta M, Sagnelli C, Celentano G, Napolitano L, La Rocca R, Capece M, et al. SARS-CoV-2 infection affects the lower urinary tract and male genital system: A systematic review. *J Med Virol.* 2021;93(5):3133-42.
4. Mardani M, Shahzadi M, Rakhshani N, Rahnavardi M, Rezvani J, Sharifinejad A. Spontaneous perforation of urinary bladder secondary to Candida cystitis: acute abdomen of urologic origin. *Surg Infect (Larchmt).* 2008;9(5):525-7.

**Cite this article as:** Kulkarni SV, Pandey AK. Spontaneous rupture of the urinary bladder: can COVID predispose? *Int Surg J* 2022;9:1287-8.