

Original Research Article

Laparoscopic intraperitoneal onlay mesh repair for ventral hernia: our experience

Vamsi K. Malligurki*, Bhaskaran A.

Department of General Surgery, MVJ Medical College, Bangalore, Karnataka, India

Received: 02 March 2022

Accepted: 17 March 2022

***Correspondence:**

Dr. Vamsi K. Malligurki,

E-mail: dr_vamsikrishna@yahoo.co.in

Copyright: © the author(s), publisher and licensee Medip Academy. This is an open-access article distributed under the terms of the Creative Commons Attribution Non-Commercial License, which permits unrestricted non-commercial use, distribution, and reproduction in any medium, provided the original work is properly cited.

ABSTRACT

Background: Ventral hernia is one of the most common pathologic conditions encountered with an estimated prevalence of one-fourth of individuals being born with it, developing, or acquiring a ventral hernia in their lifetime. Ventral hernias include both primary abdominal wall hernia and incisional hernia. Numerous studies indicate that the laparoscopic approach is safe and effective, and may be superior to open repair with regard to lower rates of recurrence and wound infection, greater patient acceptance, shorter hospital stay and early return to work. Aim of the study was to analyse the outcome, complications, postoperative pain and patient compliance in laparoscopic ventral hernia repair by intraperitoneal onlay mesh (IPOM) technique, using composite mesh.

Methods: This was a prospective study conducted in the department of general surgery, MVJ medical college, Bangalore from December 2020 to August 2021. There were 100 cases operated by experienced surgeons. All patients posted electively for laparoscopic repair of ventral hernia on an intention to treat basis were included in the study. The immediate complications of pain, perioperative bleeding and major visceral injury were noted in all cases. We then followed up each patient prospectively in the postoperative period at 1 month, 3 months and 6 months to assess the incidence of port-site hernia and recurrence.

Results: Of the 100 patients, 63 had an umbilical hernia, 33 had incisional hernias and 4 had an epigastric hernia. The mean age of the patients was 44.7 years. Female to male ratio of 2.25:1. The average defect width was 1.3 cm for umbilical hernias and 2.4 cm for incisional hernias. The mean operating time was 38 min for umbilical hernias and 61 min for incisional hernias. The mean postoperative hospital stay was 4.7 days. The mean duration of return to normal daily activity was 6.4 days. The average duration for which postoperative pain lasted was 4.6 days. No conversion to open laparotomy was required in any of the cases. The only short complication reported was postoperative pain. No case of postoperative ileus/seroma/port site infection/mesh displacement/infection or port site hernia and recurrence was reported over one year of follow up.

Conclusions: IPOM technique is safe, feasible and effective technique for treatment of ventral abdominal wall hernias.

Keywords: Laparoscopic ventral hernia repair, IPOM repair, Abdominal wall hernia, Incisional hernia repair, Umbilical hernia repair

INTRODUCTION

Ventral hernia remains a vexing problem for the surgeon and the public alike. Ventral abdominal wall hernia surgery is a common procedure in the armamentarium of surgeons. Umbilical hernias compromise 10-12% of

abdominal wall hernias.¹ Incisional hernia after previous abdominal surgeries occurs in a varying range, which was reported from 11% to 20%.²⁻⁴ Mesh hernia repair has decreased the long-term rate of recurrence from 63% for primary repair to 32%.⁵ While many open approaches have been developed for the correction of this ventral

wall defect, the main focus currently is on the minimally invasive approach of laparoscopic IPOM repair.

Laparoscopic repair of ventral hernias has the advantage of shorter hospital stay, lower incidence of wound infection, early recovery and recurrence rates less than 5%.⁶⁻⁸ As compared to open repair, laparoscopic repair of umbilical hernias has also shown favourable outcomes.⁹ Since its first description in 1993, laparoscopic repair of ventral hernias is gaining acceptance and becoming more popular by the day worldwide.¹⁰ The standard laparoscopic repair of ventral hernias consisted of bridging the defect from the peritoneal side with a composite mesh, known as the IPOM repair, which is the placement of the mesh in the underlay position through the laparoscopic intraperitoneal approach.

The obvious advantages of this laparoscopic approach include lesser post-operative pain, smaller scar, shorter hospital stay which in turn translates to the early overall recovery of the patient. The laparoscopic IPOM repair offers a novel approach to the repair of umbilical and incisional hernias with promising early results. However, this technique does have complications of its own. These include the general complications of laparoscopic surgery such as those of general anaesthesia, pneumoperitoneum related complications and the complications specific to the surgery which include port site herniation, pain, recurrence, inadvertent vascular as well as visceral injuries.¹¹

Composite meshes consist of two or more distinct components and were developed to improve the side effect profiles of meshes. Many composites mesh is 'biface implants'-meshes with a porous external surface to encourage tissue integration and a smooth microporous internal surface to prevent bowel and omental adhesions when placed in contact with viscera. The external surface generally consists of non-degradable synthetic material, while the visceral surface can be any combination of degradable or nondegradable, synthetic or biological materials, such as polyglactin, collagen, polyglycaprone, cellulose, titanium, omega-3, monocryl, polyvinylidene fluoride and hyaluronate.¹²⁻¹⁴

Aims and objectives

Aim and objectives of the study were to assess the outcome of ventral hernia patients after laparoscopic IPOM repair and to classify and enumerate the various complications of laparoscopic IPOM repair over predefined time limits.

METHODS

This was a prospective study conducted in the department of general surgery, MVJ medical college, Bangalore from December 2020 to August 2021. All patients posted electively for laparoscopic repair of ventral hernia on an intention to treat basis were included in the study.

Patients not willing for laparoscopic surgery, those unfit for general anaesthesia and those with strangulated hernias were excluded from the study.

Preoperatively a thorough history was taken and a general physical examination of the patients was done. An Ultrasound abdomen was done in each of the patients and the size, location and contents of the defect of the ventral hernia were noted. After reviewing the inclusion and exclusion criteria, the patient was then planned for an elective Laparoscopic IPOM repair. Laparoscopic IPOM was done in each patient by experienced laparoscopic surgeons. The timing was noted from the first port site incision till the closure of the last port. The following study was approved by institutional ethical committee with informed consent from participants. A composite mesh was used in all the patients. The immediate complications of pain, perioperative bleeding and major visceral injury were noted in all cases. We then followed up each patient prospectively in the postoperative period at 1 month, 3 months and 6 months to assess the incidence of port-site hernia and recurrence.

Statistical analysis was done using SPSS 20.0 (Statistical package for social sciences) software package for Windows and the $p < 0.05$ considered statistically significant.

Procedure

After valid written consent, the patient was induced under general anaesthesia in the reverse Trendelenburg position. After draping the patient with aseptic precautions, pneumoperitoneum was created by closed technique at the palmer's point. A ten mm port was inserted and used for the camera at this site. After inspecting the abdomen and the site and contents of the defect, two five mm working ports were introduced in the flank's opposite to the side of herniation. The contents in the defect were then reduced carefully by a combination of blunt, sharp and electrocautery dissection. Once the defect was free of the contents, appropriate size composite mesh was introduced from the ten mm (10 mm) port site into the abdomen.

The mesh was prepared by placing 4-6 sutures at the corners and in the centre using prolene 1-0 keeping both the ends of the knot long. The centre and corners of the mesh were lifted transfascially using Aberdeen Needle and tied on the outside thereby placing the knot anterior to the fascia. This led to the hitching up of the mesh to the anterior abdominal wall. The mesh was then fixed by applying tacks. After confirming the hemostasis, the ports were removed under vision and pneumoperitoneum was reversed. Port sites were sutured with port vicryl and skin with ethilon 3-0. Sterile dressing applied. Figure 1-3 showing intraoperative pictures showing hernial contents reduction, hernial defect and the mesh fixation respectively.

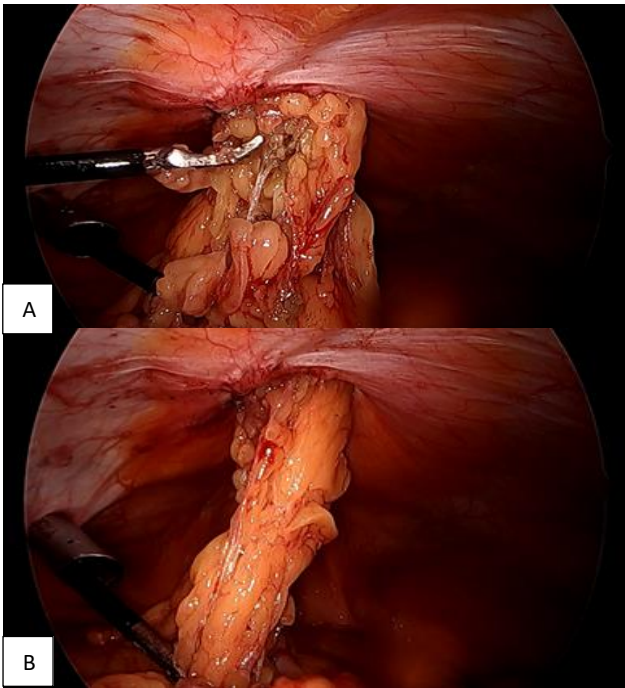


Figure 1 (A and B): Intraoperative picture showing hernial contents reduction.

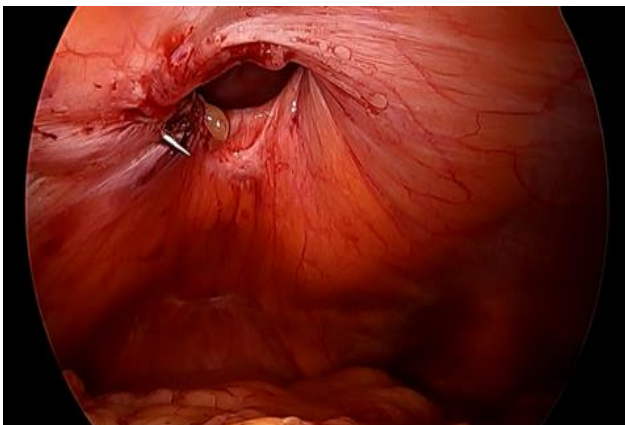


Figure 2: Intraoperative picture showing hernial defect after reducing its contents.

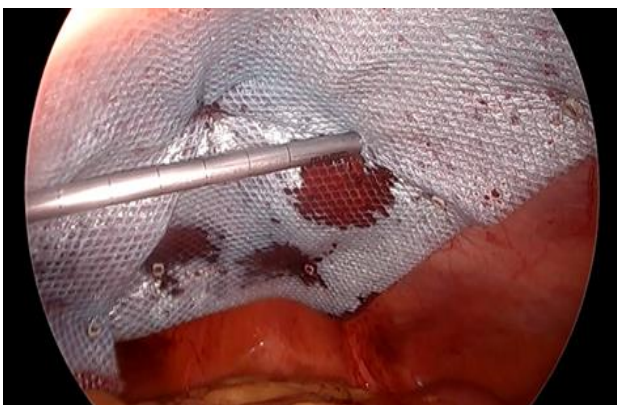

Figure 3: Intraoperative picture showing mesh fixation with tacks using laparoscopy tacker.

RESULTS

Of the 100 patients in our study, 63 had an umbilical hernia, 33 had incisional hernias and 4 had an epigastric hernia. The mean age of the patients in our study was 44.7 years. Female to male ratio of 2.25:1. The average defect width was 1.3 cm for umbilical hernias and 2.4 cm for incisional hernias. The mean operating time was 58 min for umbilical hernias and 78 min for incisional hernias. The mean duration of return to normal daily activity was 6.4 days. Mean post-op hospital stay was 4.7 days. The mean duration of return of bowel activity and enteral feeding was 24.6 hours and 25.6 hours, respectively. The average duration of post-operative pain lasted was 4.6 days. No conversion to open laparotomy was required in any of our cases. No case of postoperative ileus/seroma/port site infection/mesh displacement/infection or port site hernia and recurrence was reported over one year of follow up.

Perioperative parameters

Pain: A total of 46 patients complained of pain on postop day 1 with the need for round the clock analgesia. This number fell to 11 by day 3. At the time of discharge (a maximum interval was being 7 days and a median was 4 days), none of the patients had complaints of pain.

Major intraoperative bleeding: A total of 7 patients were noted to have a bleeding episode in the intraoperative period. But in each of these cases, hemostasis was achieved laparoscopically with electrocautery and conversion to open was not required.

Major visceral injury: None of our cases had an injury to bowel, stomach or solid organs.

Hospital stay and recovery: The median interval of hospital stay was 6 days.

Follow up

None of our patients had chronic pain, recurrence, port site herniation and mesh infection in 1 month, 3 months and 6 months follow up.

DISCUSSION

Laparoscopic IPOM repair was initiated as a minimally invasive technique for performing ventral hernia mesh repair. This technique follows all the sound principles of hernia surgery albeit the morbidity involved in the closure of big ventral defects by open technique. We made this case series in an attempt to assess the feasibility and outcomes of performing laparoscopic IPOM repair in a high-volume referral tertiary care centre such as our institute. We then assessed the incidence of various possible complications that could occur in the perioperative period and remote postoperative period to

gain a realistic perspective of this technique before proposing it as a standard of care.

Pain as a complication was seen in 46% of patients on postoperative day 1 which then decreased to 11 on day 3. The incidence of postoperative pain is reported to be equal in both the Laparoscopic IPOM and open groups. The reason behind this is believed to be due to extensive subcutaneous dissection and adhesiolysis that is required with the minimally invasive approach akin to the open approach albeit with a smaller incision.¹⁵ The length of hospital stay has been reported to be shorter and the time taken to resume daily activity level was lesser for persons undergoing lap IPOM compared to those undergoing open surgery.¹⁶

Most of the RCTs, meta-analysis and comparative studies show a significantly lower rate of short-term postoperative complications with laparoscopic IPOM repair when compared to open surgery.¹⁷ The reduction in complications is mostly due to a reduction in the incidence of wound infection. In our study, none of the patients had wound infection. In a study by Itani and colleagues, the incidence of wound infection and thereby mandating mesh removal was seen in 2.8% and 21.9% in laparoscopic and open hernia repair respectively.¹⁸ In the meta-analysis by Forbes et al the rate of mesh removal secondary to infection was 0.7% in laparoscopic IPOM repair and 3.5% in open surgery.¹⁹ In LeBlanc's 2007 review article the incidence of enterotomy in ventral hernia repair was 1.78%. This complication was associated with an increase in mortality from 0.05% to 2.8%.²⁰

The most important outcome in a hernia repair surgery is recurrence. In our series, the recurrence was nil at 12 months follow up. The introduction of mesh in hernia repair was a major advance in reducing the rate of recurrence.²¹ Burger et al reported a 10-year cumulative rate of recurrence of 63% and 32% for suture and mesh repair respectively.²² A meta-analysis published in 2009 that analysed eight RCTs found no difference in the rate of hernia recurrence between the open and laparoscopic techniques at short term follow up 3.4% and 3.6% in laparoscopic and open techniques respectively.²³ Similar findings were published by Itani and colleagues. In this RCT, the recurrence rate at 2 years follow up was 12.5% in the laparoscopic group and 8.2% in the open group ($p=0.44$).²⁴

CONCLUSIONS

Laparoscopic IPOM is an extremely safe and effective option in the management of ventral hernias. The minimally invasive approach offers a good outcome to the patient without compromising on the results of the ventral hernia repair.

Laparoscopic ventral hernia repair with IPOM technique using composite mesh has good and efficient outcomes in

terms of postoperative complications and pain with satisfactory patient compliance.

ACKNOWLEDGEMENTS

Author would like to thanks to all the staff of the general surgery department, MVJ medical college, Bangalore for their sincere work and cordial cooperation with this project.

Funding: No funding sources

Conflict of interest: None declared

Ethical approval: The study was approved by the Institutional Ethics Committee

REFERENCES

- Misra MC, Bansal VK, Kulkarni MP, Pawar DK. Comparison of laparoscopic and open repair of incisional and primary ventral hernia: results of a prospective randomized study. *Surg Endosc.* 2006;12:1839-45.
- Mudge M, Hughes LE. Incisional hernia: a 10-year prospective study of incidence and attitudes. *Br J Surg.* 1985;72:70-1.
- Lewis RT, Wiegand FM. Natural history of vertical abdominal parietal closure: prolene versus Dexon. *Can J Surg.* 1989;32:196-200.
- Sugerman HJ, Kellum JM Jr, Reines HD, DeMaria EJ, Newsome HH, Lowry JW. Greater risk of incisional hernia with morbidly obese than steroid-dependent patients and low recurrence with prefascial polypropylene mesh. *Am J Surg.* 1996;171:80-4.
- Burger JW, Luijendijk RW, Hop WC, Halm JA, Verdaasdonk EG, Jeekel J. Long-term follow-up of a randomized controlled trial of suture versus mesh repair of incisional hernia. *Ann Surg.* 2004;240(4):578-83.
- Heniford BT, Park A, Ramshaw BJ, Voeller G. Laparoscopic repair of ventral hernias nine years' experience with 850 consecutive Jani. *Mini-invasive Surg.* 2018;2:14.
- Carbajo MA, Martín del Olmo JC, Blanco JJ, Toledano M, De la Cuesta C, Ferreras C et al. Laparoscopic approach to incisional hernia lessons learned from 270 patients over 8 years. *Surg Endosc.* 2003;17:118-22.
- Sauerland S, Walgenbach M, Habermalz B, Seiler CM, Miserez M. Laparoscopic versus open surgical techniques for ventral or incisional hernia repair. *Cochrane Database Syst Rev.* 2011;(3):CD007781.
- McGreevy JM, Goodney PP, Birkmeyer CM, Finlayson SR, Laycock WS, Birkmeyer JD. A prospective study comparing the complication rates between laparoscopic and open ventral hernia repairs. *Surg Endosc.* 2003;17:1778-80.
- LeBlanc KA, Booth WV. Laparoscopic repair of incisional abdominal hernias using expanded polytetrafluoroethylene: preliminary findings. *Surg Laparosc Endosc.* 1993;3:39-41.

11. Cassar K, Munro A. Surgical treatment of incisional hernia. *Br J Surg.* 2002;89:534-45.
12. Burger JW, Luijendijk RW, Hop WC, Halm JA, Verdaasdonk EG, Jeekel J. Longterm follow-up of a randomized controlled trial of suture versus mesh repair of incisional hernia. *Ann Surg.* 2004;240(4):578-83.
13. Vavuz N, Ipek T, Abdullah AS, Kapan M, Eyuboglu E, Erguney S. Laparoscopic repair of ventral and incisional hernias: our experience in 150 patients. *J Laparoendosc Adv surg Techn.* 2005;15:6.
14. Goodney PP, Birkmeyer CM, Birkmeyer JD. Short-term outcomes of laparoscopic and open ventral hernia repair: a meta-analysis. *Arch Surg.* 2002;137:1161-5.
15. Chowbey PK, Sharma A, Kullar R. Laparoscopic ventral hernia repair. *J Laparoendoscopic adv surg techn.* 2000;10(2).
16. Schultz L, Graber J, Piertrafitta J, Hickok D. Laser laparoscopic herniorrhaphy: a clinical trial preliminary result. *J Laparoendosc Surg.* 1990;1(1):41-5.
17. Lichtenstein IL, Shulman AG, Amid PK. Laparoscopic hernioplasty. *Arch Surg.* 1991;126(12):1449.
18. Spaw AT, Ennis BW, Spaw LP. Laparoscopic hernia repair: the anatomic basis. *J Laparoendosc Surg.* 1991;1(5):269-77.
19. Jenkins JT, O'Dwyer PJ. Inguinal hernias. *BMJ.* 2008;336(7638):269-72.
20. Rutkow IM. Demographic and socioeconomic aspects of hernia repair in the United States in 2003. *Surg Clin North Am.* 2003;83(5):1045-51.
21. Kuhry E, Van Veen RN, Langeveld HR, Steyerberg EW, Jeekel J, Bonjer HJ. Open or endoscopic total extraperitoneal inguinal hernia repair? A systematic review. *Surg Endosc.* 2007;21(2):161-6.
22. Neumayer L, Giobbie-Hurder A, Jonasson O, Fitzgibbons R Jr, Dunlop D, Gibbs J et al. Open mesh versus laparoscopic mesh repair of inguinal hernia. *N Engl J Med.* 2004;350(18):1819-27.
23. Eklund A, Montgomery A, Bergkvist L, Rudberg C. Chronic pain 5 years after randomized comparison of laparoscopic and Lichtenstein inguinal hernia repair. *Br J Surg.* 2010;97(4):600-8.
24. Kark AE, Kurzer MN, Belsham PA. Three thousand one hundred seventy-five primary inguinal hernia repairs: advantages of ambulatory open mesh repair using local anaesthesia. *J Am Coll Surg.* 1998;186(4):447-55.
25. Novitsky YW, Czerniach DR, Kercher KW, Kaban GK, Gallagher KA, Kelly JJ et al. Advantages of laparoscopic transabdominal preperitoneal herniorrhaphy in the evaluation and management of inguinal hernias. *Am J Surg.* 2007;193(4):466-70.

Cite this article as: Malligurki VK, Bhaskaran A. Laparoscopic intraperitoneal onlay mesh repair for ventral hernia: our experience. *Int Surg J* 2022;9:819-23.