

Original Research Article

Clinico-pathological study of craniopharyngioma

Mohammed Sikandar¹, G. Venugopal^{1*}, M. Srinivas Reddy²

¹Department of Neurosurgery, M. G. M. Hospital, Kakatiya Medical College, Warangal, Telangana, India

²Department of Neurosurgery, Sri Krishna Hospital, Mahbubnagar, Telangana, India

Received: 26 January 2022

Revised: 21 February 2022

Accepted: 22 February 2022

*Correspondence:

Dr. G. Venugopal,

E-mail: drgvengopal11@gmail.com

Copyright: © the author(s), publisher and licensee Medip Academy. This is an open-access article distributed under the terms of the Creative Commons Attribution Non-Commercial License, which permits unrestricted non-commercial use, distribution, and reproduction in any medium, provided the original work is properly cited.

ABSTRACT

Background: Craniopharyngioma is a tumour of the suprasellar region that histologically has two distinct variants with some differences in clinical behaviour. The papillary type is almost always seen in adults and has a more indolent course. We studied clinical and radiological characteristics, surgical resectability, clinical outcome and recurrence patterns in tertiary care center.

Methods: The present study is a prospective study, comprising of 32 patients of craniopharyngiomas studies over a period of 3 years. All the patients were thoroughly evaluated for the symptoms and signs with particular stress on visual impairment and field defects.

Results: There were 16 male and 16 female patients. The incidence of craniopharyngioma was observed more in the age group of 6-10 years. Fundoscopy examination revealed optic atrophy and papilloedema in (56.25%) cases. Endocrinological dysfunction were present in 31.25% cases. Appearance on computed tomography (CT) scan showed 31.25% as cystic and 68.75% was mixed respectively. Surgical approach to the tumor was through pterional approach in (75%) sub frontal in (18.75%) transphenoidal in 18.75%. There was 2 death, 10 patients were advised postoperative radiotherapy and follow up period was from 6 months to 2 years. There were 6 recurrences out of 32 patients who were under follow-up.

Conclusions: Treatment should focus not only on long term control and survival, but also on the reduction of the disease and related morbidity and preservation of quality of life.

Keywords: Craniopharyngiomas, Hydrocephalus, Endocrinological abnormalities, Pterional approach

INTRODUCTION

Craniopharyngiomas are tumors of disordered embryogenesis. They are unusual group of epithelial tumors arising from embryonic squamous cell rests of incompletely involuted Rathke's pouch. Craniopharyngiomas are benign, extra axial, slow growing tumors that arise from the anterior margin of the sella turcica and predominantly involve the sella and suprasellar space.¹ They do not undergo malignant degeneration, but have a tendency to invade surrounding structures, and the difficulty in curing them can lead to serious morbidity or death. As craniopharyngiomas grow, they can cause

significant neurological complications, including visual loss, pituitary insufficiency, and hypothalamic damage. Further, recurrence, both along local and surgical planes as well as meningeal involvement, has been reported.²⁻⁴ Hence we studied clinical and radiological characteristics, surgical resectability, clinical outcome and recurrence patterns in tertiary care center.

METHODS

The present study is a prospective study, comprising of 32 patients of craniopharyngiomas studies in Osmania General Hospital, Hyderabad at department of neurosurgery over a period from August 2011 to February

2014. All the patients were thoroughly evaluated for the symptoms and signs with particular stress on visual impairment and field defects. Hormonal assays - prolactin (PRL), triiodothyronine (T3), thyroxine (T4), thyroid stimulating hormone (TSH), growth hormone (GH), serum (S.) cortisol were done.

Inclusion criteria

All age groups and genders who are diagnosed of craniopharyngiomas were included in the study.

Exclusion criteria

Patients with allergies, malignancies and infections were excluded from the study.

The patients were contacted using their telephone numbers provided at the time of specimen submission. Verbal consent was obtained via telephonic conversation, and follow-up information was obtained either from the patients' attendants or from the patients themselves.

All fundamental investigations have been completed. Following approval by the ethical committee study was proceeded.

Data was entered in Microsoft excel and analysis was done using statistical package for the social sciences (SPSS) version 20. Descriptive statistical analysis was done. Results on continuous measurements are presented as mean and standard deviation. Results on categorical measurements are presented as percentages.

RESULTS

Age ranged from 5 years to 60 years. There were 24 patients younger than 20 years and 8 adults older than 40 years. The incidence of craniopharyngioma was observed more in the age group of 6-10 years. There were 16 male and 16 female patients. 50% of patients were male and 50% were female in our study.

Table 1: The age and gender incidence of various patients in our study.

Age in years	Number of patients	Percentages
0-5	2	6.25
6-10	16	50
11-15	6	18.75
31-40	4	12.50
41-50	2	6.25
51-60	2	6.25
Gender		
Male	16	50
Female	16	50

Headache was the commonest complaint on admission 81.25%, vomiting 56.28%, visual disturbances 56.25%.

Decreased visual acuity was the commonest clinical sign seen in (56.25%) cases. Fundoscopy examination revealed optic atrophy and papilloedema in (56.25%) cases.

Table 3: Imaging features were as follows in present study.

Location of tumor in CT scan	Number of patients	Percentages
Purely suprasellar	16	50
Suprasellar and intrasellar	14	43.75
Purely intrasellar	2	6.25
Size of tumor on CT/MRI (cm)		
<4	26	81.25
>4	6	8.75
Appearance on CT/MRI		
Cystic	10	31.25
Mixed (cystic and solid)	22	68.75
Calcification	22	68.75

Computed tomography (CT) scan showed purely suprasellar in (50%) both suprasellar and intrasellar (43.75%) and purely intrasellar (6.25%) respectively. Appearance on CT scan showed 31.25% as cystic and 68.75% was mixed respectively. Hydrocephalus was seen in 75% (12) of children and 25% (4) of adults.

Table 4: Endocrine status of the patients.

Endocrine status	Number of patients	Percentages
Hypothyroidism	6	18.75
Hyperprolactinoma	2	6.25
Low GH	2	6.25
Features of DI	4	12.5

Endocrinological dysfunction were present in 31.25% cases out of which hypothyroidism, low growth hormone, hyperprolactinemia and features of diabetes insipidus seen in 18.75%, 12.5%, 6.25%, 6.25%, respectively.

Operative treatment

Bi-ventriculo peritoneal shunt was done in 4 cases and unilateral-ventriculo peritoneal shunt was done in 6 cases.

Table 5: The amount of tumor resected in the study.

Tumor resection	Number of patients	Percentages
Total/near total resection	2	5.88
Subtotal resection	30	88.23
Partial resection	2	5.88

Surgical approach to the tumor was through pterional approach in (75%) sub frontal in (18.75%) transphenoidal in 18.75%.

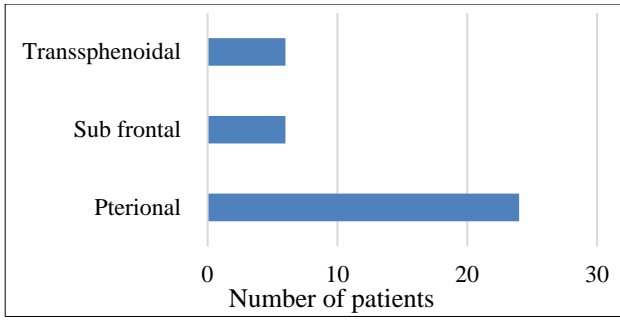


Figure 1: The approaches of tumors was as follows.

Table 6: Surgical complications in present study.

Surgical complications	Number of patients	Percentages
Post-operative convulsions	8	25
Wound infection	2	6.25
Transient diabetes insipidus	17	43.75.
CSF leak	6	18.75
Meningitis	2	6.25
Post-operative limb paresis	2	6.25
Mortality	2	6.25

There was 2 death, 10 patients were advised postoperative radiotherapy and follow up period was from 6 months to 2 years.

Table 7: Results in follow up of patients.

Vision	Number of patients	Percentages
Improvement	2	11.11
Unchanged	16	88.88
Histological pattern		
Adamantinomatous	26	81.25
Papillary	6	8.75
Imaging findings		
Recurrent tumor	6	18.75
No recurrence of tumor	26	81.25

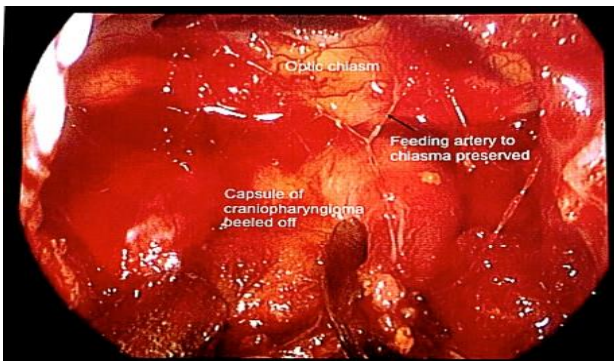


Figure 2: Peroperative picture of craniopharyngioma.

There were 6 recurrences out of 32 patients who were under follow-up.

In 4 patients trans sphenoidal decompression of tumor done, in 2 patients Redo Lt pterional craniotomy and excision of tumor was done.

There was 2 death and 30 patients were advised post-operative radiation.

DISCUSSION

This is a prospective study of 32 cases between August 2011 and February 2014 from a total of 1288 intracranial tumors, 32 craniopharyngiomas were operated, comprising 2.48%. Youngest patient was 5 years and oldest patient was 60 years. Maximum incidence of craniopharyngioma was observed in the age group of 6-10 years. The mean incidence calculated from various studies is 1.44 (1.33–1.56) per million person year for the childhood population and 1.34 (1.24–1.46) per million person per year for the overall population. The highest incidence was reported in the Danish population.⁵ Apart from occurring in a small proportion of pediatric population. The age range and the mean age of patients in our study was less than that observed in literature.

In our study male: female ratio is 1: 1. Craniopharyngiomas generally affects both the sexes equally as in studies of Pant et al and Karavitaki.^{6,7}

Commonest presenting symptoms are headache in 26 patients (81.25%), vomiting in 18 patients (56.25%) and visual disturbances in 18 (56.25%). Decreased visual acuity was the commonest clinical sign seen in 18 patients (56.25%) which are either bilateral or unilateral, one patient was completely blind. Features of optic atrophy (bilateral or unilateral) was the second most clinical sign seen in 18 patients (56.25%). In previous studies most common presenting complaints due to their close proximity to the optic chiasma, hypothalamus, and pituitary gland are headache, loss of vision, and hormonal disturbances.⁸

In our study 50% (16) tumors are purely suprasellar, 43.75% (14) of tumors are both intrasellar and suprasellar and purely intrasellar 1 case (6.25%). On CT the size of the tumor (81.25%) is less than 4cm and remaining (8.75%) are more than 4 cm.

They appear predominantly mixed in 68.75% (22) cases and cystic in 31.25% (10) cases and calcification seen in 22 cases (68.75%). Hydrocephalus was seen in 75% (12) of children and 25% (4) of adults. Endocrinological abnormalities are seen in 14 patients (43.75%). Hypothyroidism, Hyperprolactinemia, low GH and features of diabetes insipidus are seen in 6 (18.75%), 2(6.25%), 2(6.25%) and 12.5% respectively.

Unilateral ventriculoperitoneal shunt was done in 8 patients and biventricular peritoneal shunt was done in 4 out of 16 patients having hydrocephalus because they presented in altered consciousness level to casualty. Biventricular peritoneal shunt was done to relieve mass effect on 6 ventricles. After starting appropriate treatment for hormonal imbalance they were subjected to definite surgery. The surgical approach of tumor is dictated by extension and direction of tumor in our study we approached tumor by pterional approach (24), sub frontal approach (6) and transsphenoidal approach (6) in 24, 6 and 6 patients respectively.

In Fatemi et al study of patients having surgery for a craniopharyngioma (n=14) total/near total removal was achieved in 83% and 80% of patients by the supraorbital route, respectively.⁹ Vision improved in 70% of patients who had surgery by supraorbital route, respectively.

Total resection of tumor was in one case only. Most of the cases were resected subtotally (15%), partially resected in (2) case. Total excision was not possible in most of the cases because of adherence to hypothalamus, adherence to major vessels and perforating vessels. Some experts regarded these epithelial elements penetrating the neural tissue as a true histological invasion and the major obstacle to total surgical removal. Others considered such an apparent Craniopharyngioma invasion as the residual manifestation of the original site of craniopharyngioma growth.⁷

Commonest post-operative complications were transient diabetes insipidus 14 patients (43.75%), convulsion in 8 patients (25%), cerebrospinal fluid (CSF) leak in 6 patients (18.75%), meningitis in 2 patient (6.25%), post-operative

limb paresis in 2 patient (6.25%), wound infections in 2 patient (6.25%). There was 2 death in this series in 1st week of post-operative period due to hypothalamic disturbances.

Postoperative complications were treated conservatively. Commonest histopathological type was adamantinomatous type in 26 (81.25%) followed by papillary type 6 (18.75%). In our series, follow up period is from 6 months to 2 years. During this period 32 patients were evaluated clinically and repeat CT scan brain done to know recurrence/residual tumor our study is in correlation with Tariq et al study.¹¹

There were 6 recurrences out of 32 patients who were under follow-up 2 of them presented in 3rd year of follow up which was cystic. We did transnasal, transsphenoidal approach and decompression of cystic craniopharyngioma. Another case presented in 2nd year of follow up which was cystic and solid. Jennifer et al, reported a high recurrence rate of 62%, which was exclusively observed in patients with subtotal resection.¹² Complete surgical resection of craniopharyngiomas is often a difficult task due to their location and relation to other vital brain structures, resulting in a recurrence rate of 32% within 3 years.¹³ A number of surgical techniques have been developed over the last few decades for surgical excision of craniopharyngiomas, and the outcome has improved, with significant reduction in recurrence rates.¹⁴

Transsphenoidal decompression of recurrent craniopharyngioma was done 3rd case presented in 3rd year of follow-up which was cystic and solid for which we did redo left pterional craniotomy and excision of craniopharyngioma was done all the above cases were advised radiotherapy.

Table 8: The extent of resection in various studies.

Resection	Sung et al ¹⁵	Bartlett et al ¹⁶	Barua et al ¹⁷	Nagpal et al ¹⁸	Our study
Total resection	37	6	10	2	2
Subtotal resection	54	112	48	12	30
Minimal resection	4	0	0	23	2
Cyst aspiration and biopsy	14	36	0	21	0

In our study 2 total resection was done (5.88%) and in other studies accounting for 33% in Sung et al study to 3% in Nagpal et al study.^{15,18} The recurrence rates are more with subtotal resection only when compared with subtotal resection and radiotherapy and total resection. The recurrence rates in our study with subtotal resection is 6 out of 32 (18.75%). However follow up period is short when compared to above studies.

Limitations

Limitations were: it was a retrospective study, study period was less, and sample size was small.

CONCLUSION

Craniopharyngiomas are tumors with benign histology and malignant behaviour as they have a tendency to invade surrounding structures. Clinical behaviour and choice of surgical approach are dictated by the primary location of the tumor and its extension pattern. Tumor adhesion to surrounding neural and vascular structures represents the most common cause of incomplete tumour removal. All the cases of subtotal excision were advised post-operative radiotherapy and one case of total excision was not advised post-operative radiotherapy. Treatment should focus not only on long term control and survival, but also on the reduction of the disease and related morbidity and preservation of quality of life. Lifelong surveillance by

multidisciplinary support team is required for better long term results.

Funding: No funding sources

Conflict of interest: None declared

Ethical approval: The study was approved by the Institutional Ethics Committee

REFERENCES

1. Rutka JT. Craniopharyngioma-editorial note: J Neurosurg. 2002;97(1):1-2.
2. Hindman NM, Hecht EM, Bosniak MA. Follow-up for Bosniak Category 2F Cystic Renal Lesions: Radiology. 2014;272(3):757-66.
3. Schoenfeld A, Pekmezci M, Barnes MJ. The superiority of conservative resection and adjuvant radiation for craniopharyngiomas. J Neurooncol. 2012;108:133-9.
4. Sughrue ME, Yang I, Kane AJ. Endocrinologic, neurologic, and visual morbidity after treatment for craniopharyngioma. J Neurooncol. 2011;101:463-76.
5. Nielsen EH, Feldt-Rasmussen U, Poulsen L, Kristensen LO, Astrup J, Jørgensen JO, et al. Incidence of craniopharyngioma in Denmark (n = 189) and estimated world incidence of craniopharyngioma in children and adults. J Neurooncol. 2011;104:755-63.
6. Pant I, Chaturvedi S. Diagnostic approach to histopathology of central nervous system papillary tumors. Astrocyte. 2014;1:124-31.
7. Karavitaki N, Cudlip S, Adams CB, Wass JA. Craniopharyngiomas. Endocr Rev. 2006;27:371-97.
8. Petito CK, DeGirolami U, Earle KM. Craniopharyngiomas: A clinical and pathological review. Cancer. 1976;37:1944-52.
9. Fatemi N, Dusick JR, de Paiva Neto MA, Malkasian D, Kelly DF. Endonasal versus supraorbital keyhole removal of craniopharyngiomas and tuberculoma sellae meningiomas. Neurosurgery. 2009;64(5):269-84.
10. Dhandapani S, Singh H, Negm HM. Endonasal endoscopic reoperation for residual or recurrent craniopharyngiomas. J Neurosurg. 2017;126:418-30.
11. Tariq MU, Din NU, Ahmad Z, Memon W. Papillary craniopharyngioma: A clinicopathologic study of a rare entity from a major tertiary care center in Pakistan. Neurol India. 2017;65:570-6.
12. Shin JL, Asa SL, Woodhouse LJ, Smyth HS, Ezzat S. Cystic lesions of the pituitary: Clinicopathological features distinguishing craniopharyngioma, Rathke's cleft cyst, and arachnoid cyst. J Clin Endocrinol Metab. 1999;84:3972-82.
13. Yaşargil MG, Curcic M, Kis M, Siegenthaler G, Teddy PJ, Roth P. Total removal of craniopharyngiomas. Approaches and long-term results in 144 patients. J Neurosurg. 1990;73:3-11.
14. Fernandez-Miranda JC, Gardner PA, Snyderman CH, Devaney KO, Stojan P, et al. Craniopharyngioma: A pathologic, clinical, and surgical review. Head Neck. 2012;34:1036-44.
15. Sung JY. An updated Asia Pacific Consensus Recommendations on colorectal cancer screening. Gut. 2014;64:121-32.
16. Bartlett JR. Craniopharyngiomas- a summary of 85 cases. J Neurol Neurosurg Psychiatr. 1971;34:37-41.
17. Barua KK. Treatment of recurrent craniopharyngiomas: Kobe J Med Sci. 2003;49(6):123-32.
18. Nagpal RD. Craniopharyngioma: treatment by conservative surgery and radiotherapy J Postgrad Med. 1992;38(4):175-80.

Cite this article as: Sikandar M, Venugopal G, Reddy MS. Clinico-pathological study of craniopharyngioma. Int Surg J 2022;9:579-83.