

Original Research Article

Reversed osteocutaneous radial forearm island flap for traumatic thumb reconstruction

Akram Hussain Bijli, Sheikh Adil Bashir, Mir Yasir*, Abid Saleem, Altaf Rasool, Mohammad Inam Zaroo, Mir Mohsin, Peerzada Umar Farooq

Department of Plastic and Reconstructive Surgery, SKIMS, Srinagar, Kashmir-190011, India

Received: 19 September 2016

Accepted: 26 September 2016

*Correspondence:

Dr. Mir Yasir,

E-mail: drmiryasir@yahoo.co.in

Copyright: © the author(s), publisher and licensee Medip Academy. This is an open-access article distributed under the terms of the Creative Commons Attribution Non-Commercial License, which permits unrestricted non-commercial use, distribution, and reproduction in any medium, provided the original work is properly cited.

ABSTRACT

Background: Loss of a part or whole of thumb results in severe functional compromise and needs to be rectified. Traumatic thumb loss requires careful evaluation of the problem and the patient as well, sound treatment and excellent surgical technique to secure a favourable outcome. We used reverse radial osteocutaneous flap for reconstruction of thumb defects.

Methods: We witnessed almost similar nature of thumb injuries on the dorsal aspect with bone loss, in four carpenters over a period of one year. Reverse radial osteocutaneous flap was contemplated in all of them with good results.

Results: All the flaps survived completely without donor site complications. We were able to give good functional and aesthetic results. All the patients were satisfied with the procedure and final outcome.

Conclusions: The osteocutaneous variant of reverse radial forearm flap has a special place in reconstruction of thumb. This composite radial forearm osteocutaneous island flap eliminates the staging of procedures and has excellent vascularity.

Keywords: Reverse radial osteocutaneous flap, Traumatic thumb amputation, Thumb defects

INTRODUCTION

The thumb begins to function as it will in adulthood, with the start of grasping and prehensions only at 9 months of age. Thumbs opposition allows the human hand to perform power grip and precious handling.¹⁻⁴ In fact, the thumb itself is responsible for 40% to 50% of the overall function of the hand.⁵ Thus a traumatic event leading to loss of parts or whole of thumb causes severely compromised function if it is not rectified. This has generated significant interest in development of methods of thumb reconstruction.

Techniques used when reconstructing thumb after trauma are skin grafts, local or regional flaps, free tissue transfer and distraction/lengthening.

The treatment of patients with thumb loss requires careful evaluation of the problem and the patient, sound treatment in regard to treatment plan and excellent surgical technique to secure a favourable outcome.

The thumb must be of adequate length with intact sensibility of the palmer skin. Thumb function is also affected by mobility at interphalangeal (IP); metacarpophalangeal (MCP) and carpometacarpal joints.⁶ Finally hand function depends on a thumb that has durable skin coverage and a strong skeletal framework.

METHODS

Study was conducted from May 2013 to April 2014. Four patients underwent a reserved osteocutaneous radial

forearm island flap for a thumb reconstruction in the department of plastic surgery and burns, Sher-I- Kashmir institute of medical sciences, Srinagar, India.

Patients had soft tissue and bone loss involving the dorsum of the thumb and part of the skeleton while the palmar tissue with neurovascular bundle was intact (Figure 1 and Figure 2). All the four patients were young carpenters who suffered this injury with the use of planners. Machine injury was the prime course of defect in all patients and all had isolated thumb defects.

Initial assessment was done in emergency rooms and patients were informed about the procedure, its advantages and drawbacks. After taking the consent, patients were operated within 48 hours of injury. All patients were operated under general anaesthesia with tourniquet control.

Debridement with creation of thumb defect was done first followed by restoration of bone and skin defects using reverse osteocutaneous radial forearm island flap.

Following surgery, the operated hand and forearm was immobilized in a splint for 3 weeks. Immediately after this period, patients were entered into a rehabilitation program.

Follow up patients of the reconstructed thumbs ranged from 4 to 14 months (mean 10 months). During follow up period we recorded the flap progression and its outcome.

Operative technique

Preoperative Allen test to exclude patients with predominating radial blood flow or absent ulnar artery is essential. Operation was done under general anaesthesia with a pneumatic tourniquet fastened on the arm.

The flap was designed from the palmar and radio dorsal aspect of the forearm, beginning several centimeters proximal to the radial styloid. The flap design was marked after preparation of the distal thumb defect. The flap, including radial artery and its venae comitantes, is carefully raised. Care was taken not to damage the cutaneous branches of the radial nerve or the blood supply to the radius just proximal to the styloid process. One or more small branches from the radial artery were identified entering the pronator quadratus muscle and extending down to the periosteum of the radius. These vessels must be protected, often necessitating leaving a small amount of muscle attached to the radius. A bone flap was patterned on the lateral side of the radius and designed to include the perforating branches from the radial artery. The bone was osteotomized with either powered or conventional bone instruments. After ligating the radial vessels proximally, the entire flap was mobilized as a composite unit to the level of anatomical snuff box. The composite bone - skin preparation was then passed to the thumb defect with fixation of bone

secured by longitudinal or obliquely placed pins or by use of small plates. The forearm skin provided coverage of the defect.

RESULTS

All 4 patients were males. The ages ranged from 30 to 45 years (Table 1). All four received trauma while operating powered machines and negligence was the main factor behind the accidents. All patients were operated within 48 hours of injury. All the flaps survived completely without donor site complications. Flap size transferred had mean size of 48.5 cm² (Table 2). The mean length of harvested radius was 3.87 cm (Table 2). All donor sites were skin grafted and healing was uneventful at donor sites. No cases of fracture occurred in any patient during follow up period.

Table 1: Description of patients age/sex.

Sex	Age in years
Male	30
Male	33
Male	45
Male	36

Table 2: Dimensions of flap and length of radius used in each patient.

Size of flap in cm ²	Length of radius in cm
40	3.3
58	4.3
42	3.9
54	4

Hands were immobilized with forearm for 3 weeks and later physiotherapy for active and passive range of motion was started.

Two patients had lost interphalangeal and metacarpophalangeal joints and mobility of their thumb depended on carpometacarpal joint.

Other two patients

- The mean range of motion was 420 (Table 3)
- The mean grip strength was 41.25 kg (Table 3)
- The mean pinch power was 7 kg (Table 3).

There were no complications and all the 4 patients were very much satisfied with the reconstruction of new thumb.

Table 3: Functional outcome after reconstruction.

Range of motion	Grip strength (kg)	Pinch power (kg)
40 ⁰	40	6.5
44 ⁰	42.5	7.5

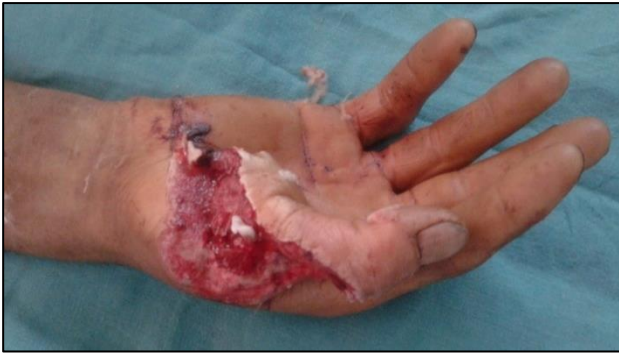

Figure 1: Planner injury with bony defect of thumb.

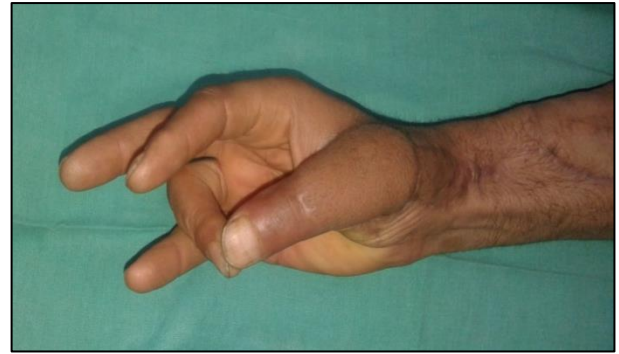


Figure 5: Post-operative picture demonstrating opposition of thumb.

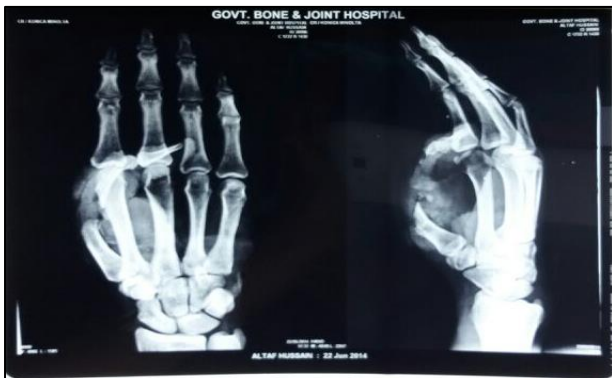

Figure 2: X-ray of same patient loss of proximal phalynx and part of metacarpal.

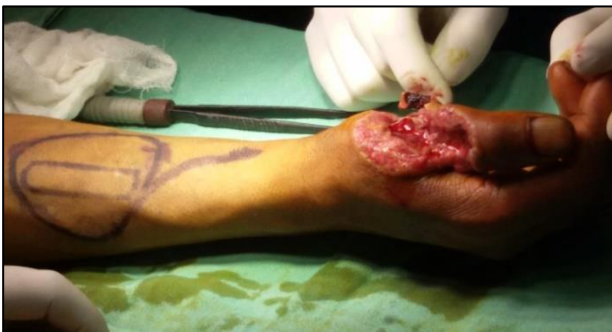

Figure 3: Intraoperative of preoperative marking for the flap.

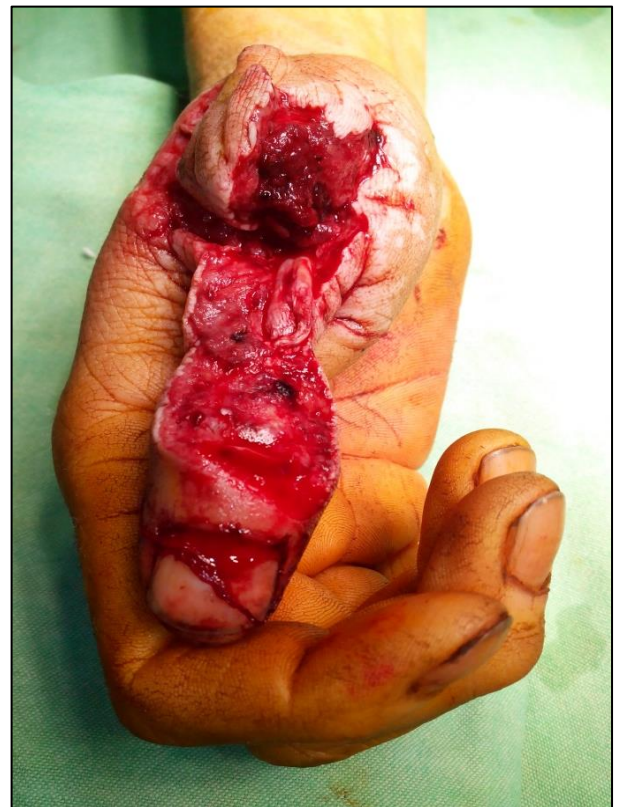

Figure 6: Traumatic defect of thumb.

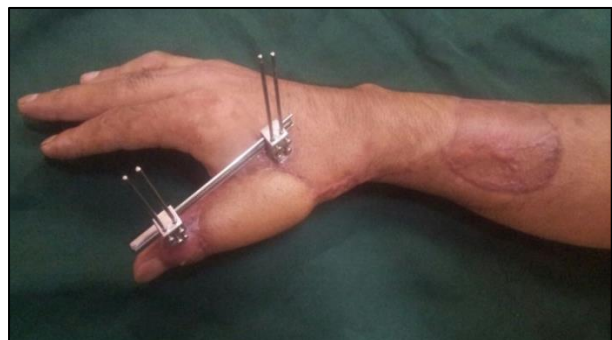

Figure 4: Post-operative picture of the patient with well settled flap and bone held by external fixator.

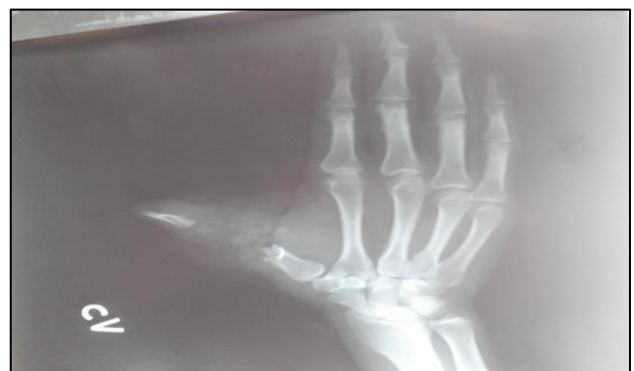


Figure 7: X-Ray loss of proximal phalynx and part of metacarpal.

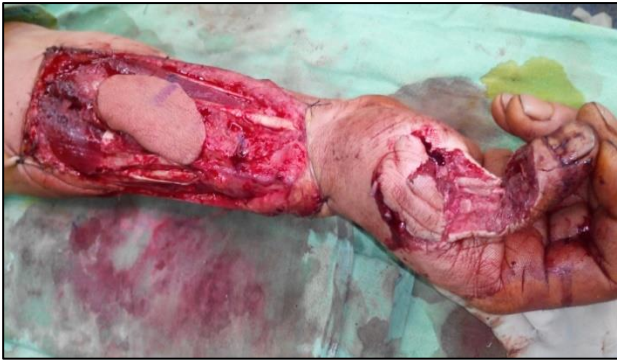

Figure 8: Intraoperative picture of flap dissection.

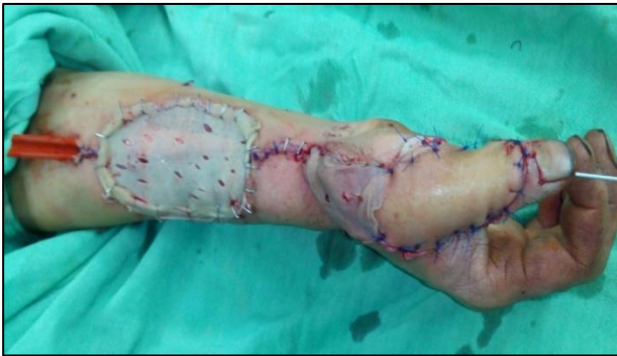

Figure 9: Immediate Post-operative picture of the patient, fixation by K-wire.

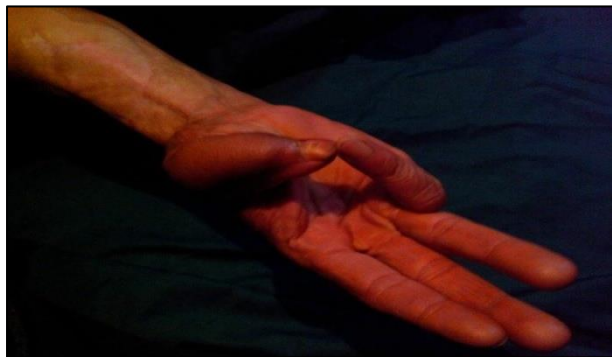

Figure 10: Post-operative picture demonstrating opposition of thumb.

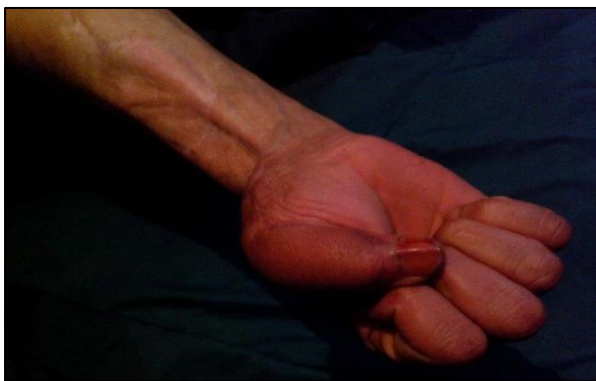

Figure 11: Picture demonstrating power grip.

DISCUSSION

Reconstruction of the thumb should ideally replace like with like, restoring both function and appearance. Thumb Replantation has demonstrated great success in that it restores the actual lost thumb, often yielding excellent functional outcomes.⁷⁻¹⁰ When replantation is not an option, the surgeon must re-create the likeness of the thumb. Reconstructing the ideal thumb function into its basic elements will assist the surgeon in choosing a reconstructive technique to provide an optimal outcome. Two broad categories must be addressed. These are sensations and opposition. Sensation determines freedom from pain and adequate sensibility to interact with or at least, protect itself from the environment. Opposition necessitates length, stability, strength and mobility.¹¹⁻¹⁵

Amputations that deprive the thumb of the distal phalanx or, at most, just proximal to the interphalangeal (IP) joint may not require reconstructions.¹⁶ Loss at or proximal to the shaft of the proximal phalanx will require some sort of reconstruction. The options available like cosmetic prosthesis, web deepening, osteoplastic reconstructions, progressive lengthening, pollicisation and toe transfer are chosen depending upon the components of injury and the expertise available.

The osteoplastic technique originally required multiple surgical stages to fashion a skin tubed flap and then a bone graft. The technique was advanced by the additional step of providing sensibility with an island flap.^{17,18} However, the drawbacks of this method, besides multiple surgical steps are numerous, including absence of bone vascularization, excessive mobility of a soft tissue, frequent trophic disorders, poor appearance and absence of a nail.

Many technical tricks have been proposed to overcome some of these drawbacks. Varga demonstrated an inverse proportion between bone resorption and delay of bone insertion (after the flap transfer) and a direct relationship between bone insertion and island skin flap.¹⁹ These findings favour a “one stage” reconstruction as attempted by Morgan and Stem.²⁰

A better possibility is to transfer a vascularized bone as a part of a compound flap. Many donor sites available that could provide skin and bone either as a pedicled flap or as an island pedicled flap. With a pedicled flap a piece of iliac crest or of clavicle has been used.^{21,22} Among island flaps, the forearm is most popular donor site, the bone fragment being taken from radius or ulna based on the radical artery the posterior interosseous artery.²³⁻²⁵

In our 4 cases we used reversed osteocutaneous radial forearm island flap. The patients had loss of dorsal aspect of skin and soft tissue with part of loss of bone. They were all planner injuries in carpenters and part or whole of bone was lost. The palmer aspect of skin with flexor tendons was intact in all these cases. This made the

reserved osteocutaneous radial forearm island flap an ideal donor site for reconstruction. Vascularized bone with a supple soft tissue cover was provided in a single stage. None of the patients suffered any surgical complications. As our patients had an intact carpometacarpal joint, they gained adequate mobility for opposition of thumb with excellent sensation provided by the native volar tissue. The function of the newly reconstructed thumb was enough to meet the needs of daily activity of the patients.

Skin healing at the donor site has been a problem in about one third of patients with this flap. In our series one patient had delayed wound healing over the donor site. The result was acceptable as the skin grafted area is proximally located and blends well with the surrounding skin.

Two major problems with the donor site are delayed healing of skin graft over tendons and more important functionally and cosmetically, fracture of the radius.

Prevention of fracture was a primary objective while harvesting segment of bone from radius. It was achieved by removing smaller segment of bone, using foot shaped osteotomy and ensuring adequate immobilization for six weeks in all our patients. None of our patients developed fracture.

CONCLUSION

The reverse radial forearm flap is currently utilized to reconstruct defects of hand. The osteocutaneous variant of this flap has a special place in reconstruction of thumb. This composite radial forearm osteocutaneous island flap eliminates the staging of procedures and has excellent vascularity.

All studied patients were underwent a single stage procedure and all flaps survived and healed completely. As the bone segment is vascularized, the technique prevents bone resorption. The patients in our series had good bone union with adequate strength of the thumb for daily routine work.

ACKNOWLEDGEMENTS

Authors would like to thank the theatre and their paramedical staff. Special thanks to all faculty and resident staff.

Funding: No funding sources

Conflict of interest: None declared

Ethical approval: A formal ethical clearance has been sought from the ethical committee of hospital

REFERENCES

1. Edgerton MT, Snyder GB, Webb WL. Surgical treatment of congenital thumb deformities,

- including psychological impact of correction. J Bone Joint Surg Am. 1965;47:1453-74.
2. Flatt AE. The Care of Congenital Hand Anomalies, 2nd ed. St. Louis, Quality Medical Publishing, 1994.
3. Boyes. H. Phylogeny and comparative anatomy. In Bunnell S: Surgery of the Hand. Philadelphia, JB Lippincott, 1970;5.
4. Shin AY, Bishop AT, Berger RA. Microvascular reconstruction of the traumatized thumb. Hand Clin. 1999;5:347-37.
5. May JW. Microvascular great toe to hand transfer for reconstruction of the amputated thumb. In May JW Jr, Littler JW, eds: The Hand. Philadelphia, WB Saunders. McCarthy JG, ed: Plastic Surgery. 1990;8:5153-85.
6. Urbaniak JR. Thumb reconstruction by microsurgery. Instr Course Lect. 1984;33:425-46.
7. Ikeda K, Tomita K, Hashimoto F, Morikawa S. Long-term follow-up of vascularized bone grafts for the reconstruction of tibial nonunion: evaluation with computed tomographic scanning, J Trauma. 1992;32:693-7.
8. Steinmann SP, Bishop AT, Berger RA. Use of the 1,2 intercompartmental supraretinacular artery as a vascularized pedicle bone graft for difficult scaphoid nonunion. J Hand Surg Am. 2002;27:391-401.
9. Sunagawa T, Bishop AT, Muramatsu K. Role of conventional and vascularized bone grafts in scaphoid nonunion with avascular necrosis: a canine experimental study. J Hand Surg Am. 2000;25:849-59.
10. Taylor GI. The current status of free vascularized bone grafts. Clin Plast Surg. 1983;10:185-209.
11. Donski PK, O'Brien BM. Free microvascular epiphyseal transplantation: an experimental study in dogs. Br J Plast Surg. 1980;33:169-78.
12. Fuchs B, Steinmann SP, Bishop AT. Free vascularized corticoperiosteal bone graft for the treatment of persistent nonunion of the clavicle. J Shoulder Elbow Surg. 2005;14:264-8.
13. Jacobson JHI, Suarez EL. Microsurgery in anastomosis of small vessels. Surg Forum. 1960;11:243-5.
14. Nonnenmacher J, Bahm J, Laforest P, Kempf I. Aneurysmal cyst of the proximal radius: resection and free vascularized fibular bone graft. Microsurgery. 1993;14:280-4.
15. Solonen KA. Free vascularized bone graft in the treatment of pseudarthrosis. Int Orthop. 1982;6:9-13.
16. Stock W, Hierner R, Wolf K. Vascularized periosteal transplant: a review of a new therapeutic possibility. Handchir Mikrochir Plast Chir. 1991;23:149-56.
17. Littler JW. The neurovascular pedicle method of digital tranposition for reconstruction of the thumb. Plast Reconstr Surg. 1953;12:303-19.
18. Van Overstraeten, Foucher G. Etude comparative des resections maticarpiennes et des translocations

- après mputations des doigts medians. *Ann Chir Main.* 1995;14:74-83.
19. Varga A. Bewertungskriterien der Ergebnisse und Knochenspan Resorption nach Daumnrekonstruktionen. *Handchirurgie.* 1981;13:10-3.
 20. Morgan JR, Stein F. Method for a rapid and good thumb reconstruction. *Plast Reconstr Surg.* 1972;50:131-3.
 21. Broadbent TR, Woolf RM. Thumb reconstruction with contiguous skin bone pedicle graft. *Plast Reconstr Surg.* 1960;26:494-9.
 22. McGregor IA, Simonetta AC. Reconstruction of the thumb by composite bone-skin flap. *Br J Plast Surg.* 1964;17:37-48.
 23. Biemer F, Stock W. Total thumb reconstruction: one stage reconstruction using an osteocutaneous forearm flap. *Br J Plast Surg.* 1983;36:52-6.
 24. Foucher G, Van Genechten F, Merle M, Michon J. Single stage thumb reconstruction by a composite forearm island flap. *J Hand Surg Br.* 1984;9:245-8.
 25. Masquelet AC, Penteadó CV. LE lambeau interosseux posterieur. *Ann Chir Main.* 1987;6:131-9.
 26. Zancolli EA, Angrigiani C. Colgajo dorsal de antebrazo en isla. *Rev Assoc Argent Ortho Trauma.* 1986;51:161-8.
 27. Guimberteau JC, Goin JL, Panconi B, Schumacher B. The reverse ulnar artery forearm island flap in hand surgery: 54 cases. *Plast Reconstr Surg.* 1988;81:925-32.
 28. Lovie MJ, Duncan GM, Glasson DW. The ulnar artery forearm free flap. *Br J Plast Surg.* 1984;37:486-92.
 29. Hu W, Martin D, Faucher G, Baudet J. Utilisation du lambeau inter-osseux anterior en iliot a contrario en chirurgie de lamain. A propos de 15 cas. *Ann Chir Plast Esthet.* 1994;39:288-300.

Cite this article as: Bijli AH, Bashir SA, Yasir M, Saleem A, Rasool A, Zaroo MI, et al. Reversed osteocutaneous radial forearm island flap for traumatic thumb reconstruction. *Int Surg J* 2016;3:1733-8.