

## Case Report

# Challenges in managing the isolated cervical lymphadenopathy in absence of thyroid nodule

Nikhil Talwar, Gautam Anand\*, Kayenaat Puran Singh Jassi, Rahul Dhamija, Sumit Bhaskar, Akshay Kumar

Department of Surgery, Lady Hardinge Medical College and Dr. R. M. L. Hospital, New Delhi, India

**Received:** 09 February 2022

**Accepted:** 04 March 2022

### \*Correspondence:

Dr. Gautam Anand,

E-mail: [gautam16alok@gmail.com](mailto:gautam16alok@gmail.com)

**Copyright:** © the author(s), publisher and licensee Medip Academy. This is an open-access article distributed under the terms of the Creative Commons Attribution Non-Commercial License, which permits unrestricted non-commercial use, distribution, and reproduction in any medium, provided the original work is properly cited.

## ABSTRACT

Differentiated thyroid cancer make up the vast majority of thyroid cancers with papillary thyroid cancer representing 84% of all thyroid cancer diagnoses. Papillary carcinoma of the thyroid presenting primarily as lateral neck swelling is rare. In the absence of thyroid swelling further evaluation should be done to exclude the primary tumors of scalp and head and neck region. Diagnosis of this condition is made by ultrasound guided FNAC. Surgery is the main treatment modality of choice. Here, we reported a case of an adult female who presented with isolated cervical lymphadenopathy and FNAC revealed metastatic papillary carcinoma of thyroid. Total thyroidectomy with central and posterolateral cervical neck dissection was done, with histology confirming as papillary thyroid carcinoma with local lymphnode metastasis.

**Keywords:** Papillary carcinoma thyroid, Lateral neck swelling, Isolated cervical lymphadenopathy, Lateral aberrant thyroid, Papillary microcarcinoma

## INTRODUCTION

Differentiated thyroid cancer make up the vast majority of thyroid cancers with Papillary thyroid cancer representing 84% of all thyroid cancer diagnoses. Papillary thyroid carcinoma is known to metastasize to cervical lymph nodes and these metastases are cystic in approximately 40% of cases. The classic presentation of papillary thyroid carcinoma is that of an asymptomatic, palpable thyroid nodule, discovered by either patients or physicians during routine examination. These nodules are typically slow growing and painless. The presence of isolated cervical lymphadenopathy in absence of clinically palpable nodule is a rare entity.<sup>1</sup> This situation poses both a diagnostic and therapeutic dilemma. We report a rare case of a papillary carcinoma of thyroid having a cervical mass as an only initial presenting symptom. The aim of this case report is to emphasize papillary thyroid cancer as a differential diagnosis of lateral neck swelling in the absence of thyroid

enlargement and discuss investigations and management for the same.

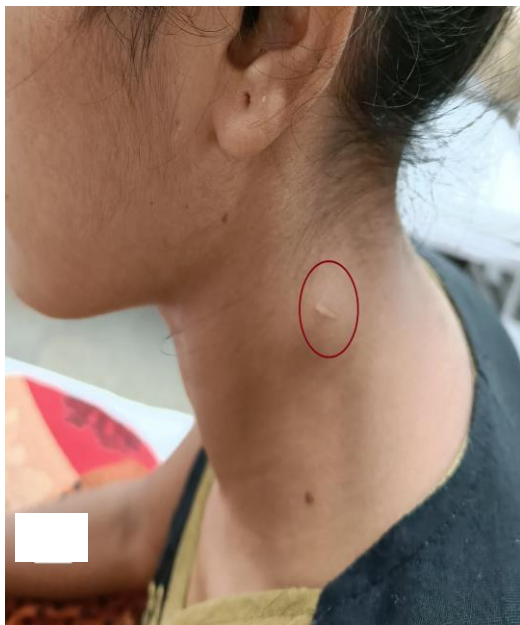## CASE REPORT

A 23-year-old female presented with a painless swelling on the left lateral aspect of the neck since 1 year. The swelling has gradually progressed in the last 3 months. She had no other complaints. General physical examination was essentially normal. Neck examination showed a 2 × 2 cm firm, nontender, mobile lymphnode in the left posterior triangle of the neck, lateral to the left Sternocleidomastoid muscle (Figure 1). Oral examination and thyroid examination was normal. Ultrasonography revealed a solid, nodular, taller than wider hypoechoic lesion in the Left lobe of thyroid with few echogenic foci, measuring 10×8 mm in the upper pole (TIRADS 5). Multiple small necrotic lymph nodes noted in level 2, 3, 4 and 5 with echogenicity same as that of the thyroid lesion. Ultrasound guided FNAC was done which revealed highly cellular

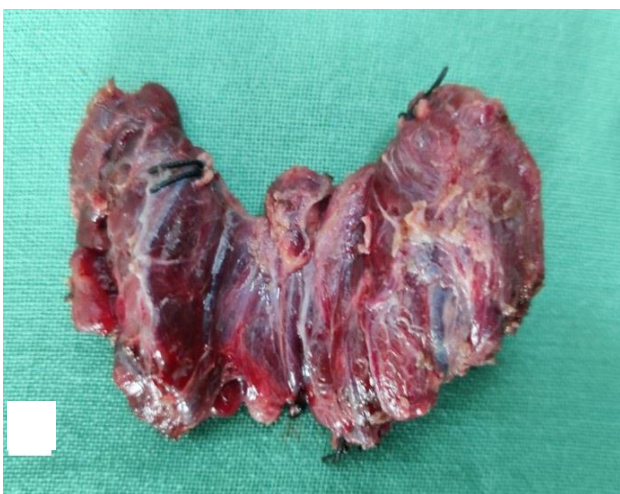smears with presence of follicular epithelial cells arranged in sheets, clusters and macrofollicles, and focally arranged in papilloid fragments.

Category 5 lesion as per Bethesda Reporting system, suspicious for papillary thyroid carcinoma. Patient was counselled regarding the need for surgery and she underwent total thyroidectomy (Figure 2) with central and Posterolateral compartment neck dissection (Figure 3).

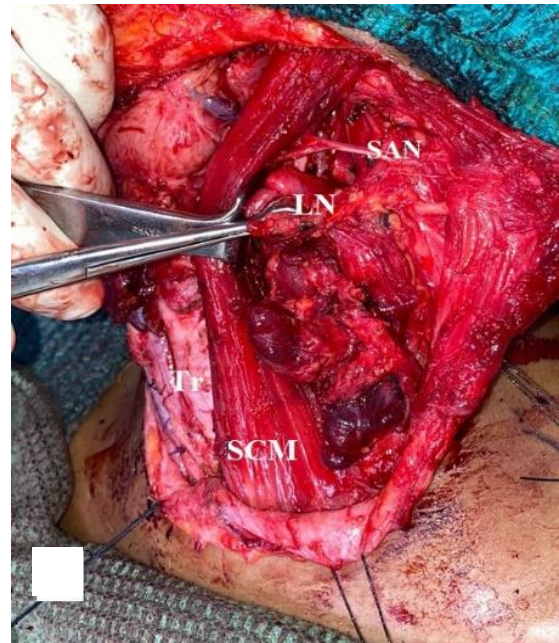
Histopathological examination (Figure 4) showed papillary thyroid carcinoma, pT2N1bMx tumor, with Extrathyroidal extension present, with microscopic strap muscle invasion. Patient is to be followed up with radioiodine uptake scan after 6 weeks with thyroxine supplementation and regular follow up.



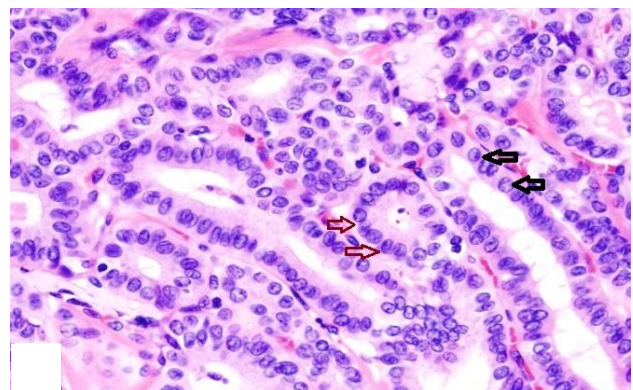
**Figure 1: Isolated enlarged lymphnode of level VI group with no palpable thyroid swelling.**



**Figure 2: Specimen of total thyroidectomy.**



**Figure 3: Intraoperatively left Sternocleidomastoid muscle (SCM) is retracted medially for better Lymphnode (LN) clearance with preservation of Spinal accessory nerve (SAN) while performing central and posterolateral compartment neck dissection.**



**Figure 4: Photomicrograph showing thyroid follicles rich in colloid with large tightly packed cells with nuclear overlapping (red arrow) and with clear nuclei (black arrow).**

## DISCUSSION

Papillary carcinoma of thyroid is the most common form of well-differentiated thyroid cancer. Papillary carcinoma appears as an irregular solid or cystic mass or nodule in a normal thyroid parenchyma. Despite its well-differentiated characteristics, papillary thyroid carcinoma may be overtly or minimally invasive.<sup>2</sup> These tumors may spread easily to other organs. Less common presentations include isolated cervical lymphadenopathy, recurrent laryngeal nerve palsy, parapharyngeal masses, cervical cysts, haemoptysis and pulmonary metastasis, all of which could pose a

diagnostic challenge. Isolated cervical lymphadenopathy have been reported in 11% of the cases in some studies.<sup>3</sup>

The traditional evaluation of thyroid included clinical examination, biochemical examination (thyroid stimulation hormone), imaging and fine needle aspiration cytology. In our case the patient was euthyroid and no palpable thyroid nodule was present. Imaging modality like USG should be done to look for any suspicious nodule especially papillary microcarcinoma. Papillary microcarcinoma is defined as a tumor  $\leq 10$  mm (single focus) in the thyroid gland. However primary lesion could be as small as a few mm in size and can be missed easily preoperatively. USG is also useful for assessing the lateral cervical swelling by differentiating it to be solid or cystic in nature. In presence of cystic swelling, a branchial cyst should be the differential diagnosis. However, several reports suggest the possibility of papillary carcinoma metastasis in the node when cystic.<sup>4</sup> In the presence of metastasis, the cystic mass reveals an internal lining that is thickened and irregular.

The cytological nature of the neck mass and the possibility of metastasis is initially determined by FNAC. FNAC is well-tolerated, minimally invasive, reliable in the hands of an experienced cytologist. It will further not compromise future neck dissection if required as compared to open biopsy. USG guided FNAC is advised in lesions that are nonpalpable, mostly cystic or posteriorly located. Bethesda system for reporting thyroid cytopathology (BSRTC) is used in stratification for malignancy risk of thyroid nodules in patients with indeterminate results on cytology. If FNAC is inconclusive and the possibility of metastasis in the node is strong, a thorough search for other possible primary sites in the oropharynx, larynx, and head and neck region should be carried out.<sup>5</sup>

The recommended treatment of patients with papillary thyroid carcinoma presenting primarily as isolated cervical lymph node metastasis is total thyroidectomy with ipsilateral modified radical neck dissection. After surgery radioiodine therapy is started after 4-6 weeks. This therapy is intended to both detect and destroy any metastasis and residual tissue in the thyroid. Patients are administered hormone replacement levothyroxine for life long. Thyroglobulin levels should be measured initially at 6 to 12 months intervals and more frequently in patients with high-risk tumors.<sup>6</sup>

Chemotherapy with cisplatin or doxorubicin has proven limited efficacy, however, it could be helpful for patients with bone metastases to improve their quality of life.<sup>7</sup>

## CONCLUSION

Papillary carcinoma of the thyroid presenting primarily as lateral neck swelling is rare. In the absence of thyroid swelling further evaluation should be done to exclude the primary tumors of scalp and head and neck region. The nature of these swelling is confirmed by radiological examination and FNAC. If cervical lymphadenopathy is confirmed to be a metastatic thyroid carcinoma then total thyroidectomy along with unilateral or bilateral lymphnode dissection should be carried out. Patient is then followed up with a radionuclide scan in post-op period and lifelong thyroxine in suppressive dose helps in a better outcome.

*Funding: No funding sources*

*Conflict of interest: None declared*

*Ethical approval: Not required*

## REFERENCES

1. Schlumberger M, Leboulleux S. Current practice in patients with differentiated thyroid cancer. *Nat Rev Endocrinol.* 2021;17(3):176-88.
2. Singh A, Butuc R, Lopez R. Metastatic papillary thyroid carcinoma with absence of tumor focus in thyroid gland. *Am J Case Rep.* 2013;14:73-5.
3. Tastekin E, Can N, Ayturk S, Celik M, Ustun F, Guldiken S, et al. clinically undetectable occult thyroid papillary carcinoma presenting with cervical lymph node metastasis. *Acta Endocrinol (Buchar).* 2016;12(1):72-6.
4. Shin JH. Ultrasonographic imaging of papillary thyroid carcinoma variants. *Ultrasonography.* 2017;36(2):103-10.
5. Ranganath R, Dhillion VK, Shaear M, Rooper L, Russell JO, Tufano RP. Unusual locations for differentiated thyroid cancer nodal metastasis. *World J Otorhinolaryngol Head Neck Surg.* 2020;6(3):176-81.
6. Liu J, Liu Y, Lin Y, Liang J. Radioactive Iodine-Refractory Differentiated Thyroid Cancer and Redifferentiation Therapy. *Endocrinol Metab (Seoul).* 2019;34(3):215-5.
7. Mitchell AL, Gandhi A, Scott-Coombes D, Perros P. Management of thyroid cancer: United Kingdom National Multidisciplinary Guidelines. *J Laryngol Otol.* 2016;130(2):150-60.

**Cite this article as:** Talwar N, Anand G, Jassi KPS, Dhamija R, Bhaskar S, et al. Challenges in managing the isolated cervical lymphadenopathy in absence of thyroid nodule. *Int Surg J* 2022;9:914-6.