

## Case Report

# Ludwig's angina to retrosternal abscess: a complication of odontogenic infection

Anant Beedkar, Sarojini P. Jadhav, Vishakha Iyer, Varun Gowda, Sriranjani Iyer\*

Department of General Surgery, Government Medical College, Aurangabad, Maharashtra, India

**Received:** 16 January 2022

**Revised:** 07 February 2022

**Accepted:** 10 February 2022

### \*Correspondence:

Dr. Sriranjani Iyer,

E-mail: [sriranjani1993@gmail.com](mailto:sriranjani1993@gmail.com)

**Copyright:** © the author(s), publisher and licensee Medip Academy. This is an open-access article distributed under the terms of the Creative Commons Attribution Non-Commercial License, which permits unrestricted non-commercial use, distribution, and reproduction in any medium, provided the original work is properly cited.

### ABSTRACT

Ludwig's angina (LA) is a rapidly spreading cellulitis involving sublingual and submaxillary spaces. It arises most frequently from periapical and periodontal infection of the mandibular molars. Two major complications of LA are life-threatening upper airway obstruction and infectious seeding of the mediastinum, which are responsible for a high mortality rate. Other complications of LA include thrombophlebitis of the internal jugular vein, rupture of the carotid artery, metastatic abscesses and necrosis of the tongue. We have encountered two such cases, with a rapid spread of the inflammation resulting in various local and systemic complications. Awareness of such complications and early clinical as well as radiological diagnosis can lead to prompt surgical drainage, proper antibiotic therapy, and better survival chance. Recognised less often today, this rapidly progressive submaxillary cellulitis may still be fatal.

**Keywords:** Ludwig, Retrosternal, Abscess

### INTRODUCTION

Ludwig's angina (LA) is a cellulitis that affects the sublingual and submaxillary areas and spreads quickly.<sup>1</sup> Angina comes from the Latin word *angere*, which means 'to strangle.' The most common cause is periapical and periodontal infection of the mandibular molars, although it can also be caused by submandibular sialadenitis, tonsillitis, compound fractures of the mandible, infected neoplasms, erysipelas, and penetrating wounds in the mouth floor.<sup>2-4</sup> These teeth's dentoalveolar abscesses can break through the comparatively thin cortex beneath the myelohyoid ridge and infect the submaxillary area, which then spreads to the submandibular, sublingual, and submental spaces.<sup>5</sup>

Upper airway obstruction and infectious seeding of the mediastinum are two major complications of LA that are responsible for a high mortality rate before the antibiotic era: more than 50% in LA, and from 50% (with surgical

drainage) to 86 percent (without surgical drainage) in mediastinitis.<sup>6,7</sup> Other LA consequences include internal jugular vein thrombophlebitis, carotid artery rupture, metastatic abscesses, and tongue necrosis.<sup>8-10</sup> We've recently seen two similar cases, with the inflammation spreading quickly and causing a variety of local and systemic problems.

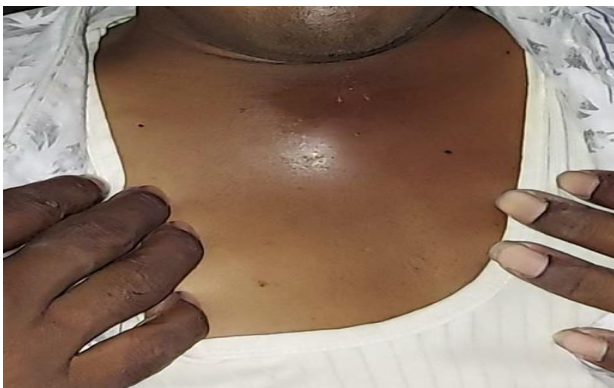### CASE REPORT

#### Case 1

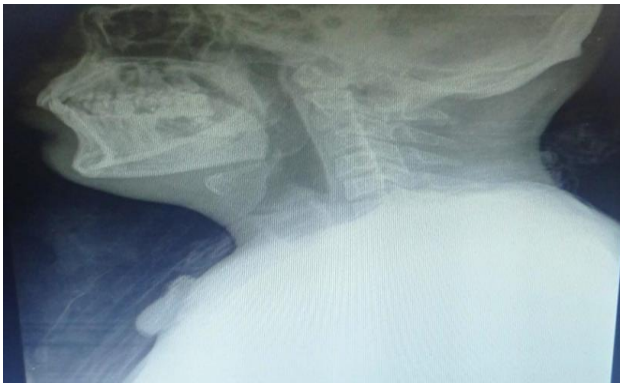A 34 year old male came to surgical outpatient department with chief complaints of difficulty in mouth opening, swelling in anterior aspect of neck since last 10 days and swelling over anterior aspect of chest since 3-4 days. Patient developed toothache 10 days back in right lower 2<sup>nd</sup> molar which later started to produce muco-purulent discharge. Eventually patient developed difficulty in mouth opening and chewing associated with dull aching

pain throughout the day. Patient developed swelling in the anterior aspect of chest since 3-4 days.

On examination patient was febrile, with tachycardia, but normotensive. On inspection patient appeared to be toxic, with fullness in the neck extending over bilateral submandibular, submental region. Tensely cystic swelling over sternum, 3×2 centimetres, roughly oval, single, with ill-defined border, fluctuant, non-transilluminant, non-compressible with an overlying erythema was seen with no sinus or fistula or pulsations. Patient had difficulty in neck extension with only one finger mouth opening. On palpation, local rise of temperature and tenderness was present over both neck and chest. Cervical lymphadenopathy involving bilateral level Ia, Ib, II of size 0.5×0.5 centimetres was evident. Intravenous empirical antibiotics were started.



**Figure 1: Suprasternal swelling with submandibular fullness visible on inspection.**

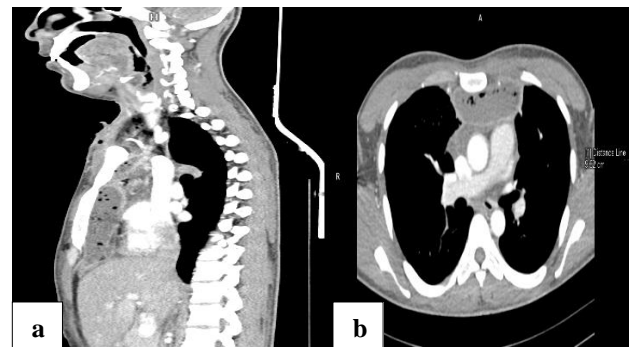


**Figure 2: X- ray suggestive of soft tissue thickening with few airfoci in submental region with loss of cervical lordosis.**

Roentgenogram of neck lateral view was suggestive of soft tissue thickening with few airfoci in submental region with loss of cervical lordosis. Ultrasonography of the neck and contrast enhanced computed tomography of chest and neck revealed peripherally enhancing pockets of collection with multiple air foci within the sublingual region extending along cervical fascia of neck in midline involving strap muscles and extending upto sterno-

clavicular notch. Inferiorly this collection showed a retro sternal extension along endothoracic fascia upto xiphisternum with pockets of collection along left sternocleido mastoid muscle and along subcutaneous plane and in bilateral supraclavicular region suggestive of infective etiology with a possibility of Ludwig's angina. Collection was posteriorly seen to be indenting the mediastinal structures, however no involvement of mediastinum was noted.

Intraoperatively, right lower second molar tooth was extracted and approximately 50 cc pus was drained per orally. Release incision was taken over right half of submandibular region and over suprasternal region. 70-80 cc pus collection was drained from the chest wall incision whereas the submandibular incision drained minimal edematous fluid. Patient was given a course of intravenous antibiotics with daily cleaning and dressing with a gravitational postural drainage advised for the retrosternal collection. Patient was reoperated 2 days later with a subxiphoid vertical incision for the drainage of retrosternal 35-40 cc purulent collection. Patient's post-operative period had an uneventful course and was managed on intravenous antibiotics with regular dressings thereafter. Patient was discharged after 6 days.

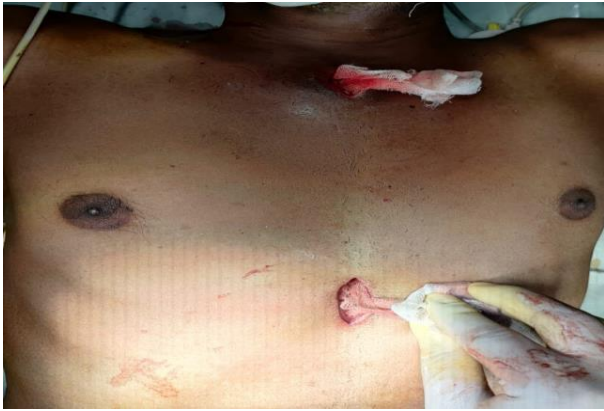

**Figure 3: Retrosternal collection of abscess seen on (a) sagittal section and (b) axial section of CECT thorax along endothoracic fascia upto xiphisternum.**

A 70 year old male came to casualty with complaints of swelling in the submandibular region since 4 days. It was also associated with fever. History of hoarseness of voice present since 4 days. Patient gives a history of tooth extraction 2 years back. Patient is a known hypertensive with chronic obstructive pulmonary disease (COPD) since last 4 years on medications. Patient is a chronic alcoholic, bidi smoker and a tobacco chewer since last 10-15 years.

On examination patient was afebrile with tachycardia and hypotension. Post resuscitation, on inspection, he had a solitary swelling in the anterior part of neck extending between right and left angle of mandible measuring approximately 12×10 centimeter, involving the entire neck. There was erythema over the skin. No evidence of any sinus or fistula. Swelling does not move with deglutition. No evidence of difficulty in swallowing or respiratory distress. On palpation, swelling had local rise

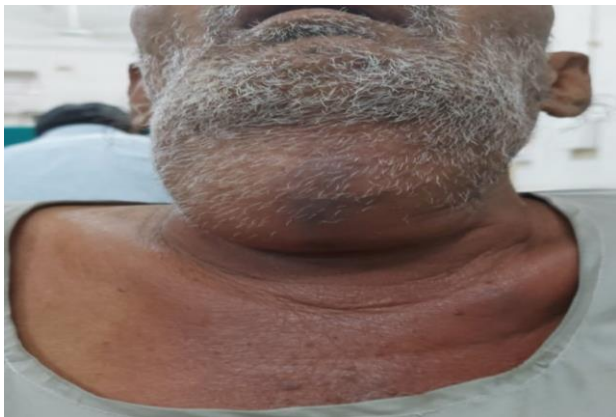of temperature and tenderness with a cystic consistency. Fluctuation was present but it showed no transillumination. Lower border of the swelling was distinct.



**Figure 4: Subxiphoid vertical incision for the drainage of retrosternal 35-40 cc purulent collection with suprasternal vertical incision.**

#### Case 2

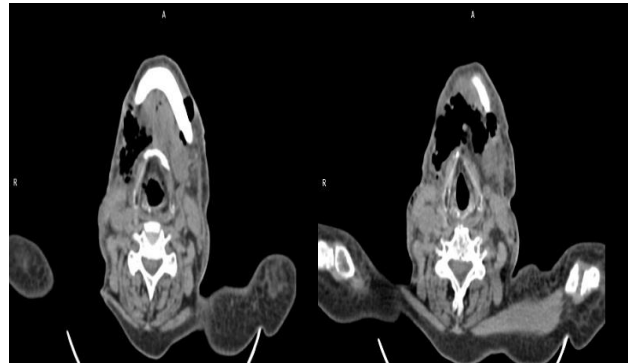
Patient had raised total leukocyte count and deranged kidney function tests. Ultrasonography of neck and computed tomography of neck and chest was suggestive of few pockets of collection with multiple airfoci noted in submandibular region extending to the cervical region. Laterally collection is seen extending along the subcutaneous plane in left supraclavicular region suggestive of infective etiology.



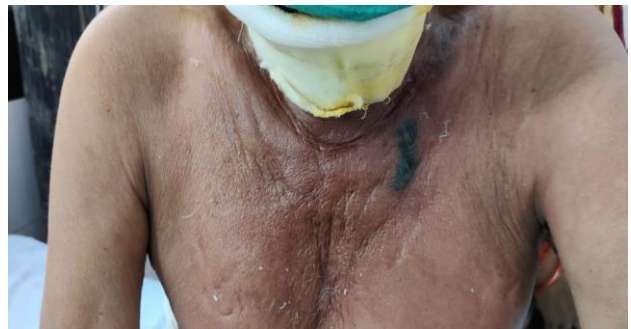**Figure 5: Submandibular swelling with extensive neck extension with erythema over skin over submandibular region and neck.**

After stabilization, incision and drainage of submandibular swelling was done and patient shifted to intensive care. After 2 days the submandibular swelling progressed to anterior aspect of chest with erythema and necrosis of the overlying skin. Patient was posted for debridement of the chest wall swelling and necrotic patch was removed. Patient did not maintain saturation postoperatively on

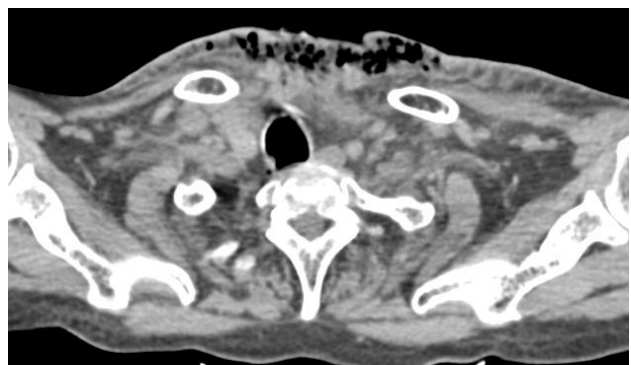
room air, hence after detailed consultation swab was sent for COVID-19 testing. Potassium hydroxide (KOH) mount of the nasal scrapings was positive for mucormycosis. Antifungal treatment was added with a step up of antibiotics. Meanwhile patient progressively went into respiratory distress and COVID-19 reverse transcriptase-polymerase chain reaction (RT-PCR) report came positive. Patient was started on treatment according to guidelines of COVID-19 and mucormycosis but inspite of extensive resuscitative measures, patient succumbed to acute respiratory distress syndrome.



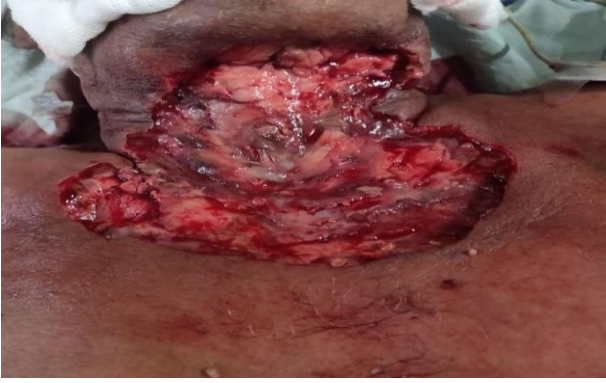**Figure 6: Computed tomography of neck with axial images showing pockets of collection with multiple airfoci noted in submandibular region.**



**Figure 7: Post-operative extension of submandibular swelling to anterior aspect of chest with erythema and necrosis of the overlying skin.**



**Figure 8: Computed tomography imaging of neck and thorax showing multiple air foci over anterior aspect of neck and chest.**



**Figure 9: Post debridement photo of neck and chest with necrotic tissue removed.**

## DISCUSSION

LA is a cellulitis that affects the sublingual and submaxillary areas and spreads quickly. The organisms that cause LA are usually oropharyngeal mucosal commensals.<sup>1,8</sup> Dental infection is the most prevalent cause of LA, followed by nasopharyngeal surgery or trauma, tonsillitis, and, less commonly, submandibular sialadenitis, erysipelas, furuncles, or infected thyroglossal duct cysts.<sup>8,10</sup>

Infections of the maxillary molar teeth have been known to spread to the pterygomandibular area and the infra-temporal space. Ludwig's angina is caused by abscesses from the anterior mandibular teeth that drain above or below the mylohyoid muscle.<sup>11,12</sup> Infections that start in the mouth's floor quickly move to the upper region of the visceral compartment. There is no anatomical barrier preventing progression into the superior mediastinum from here. This can happen in the retro-visceral space between the pre-vertebral fascia and the posterior wall of the pharynx and oesophagus, or around the lateral aspect of the oesophagus and trachea as they lie within the neck, and then along the deep surface of the pre-tracheal fascia in the pre-tracheal space.<sup>7,13,14</sup>

Ludwig's angina is diagnosed through clinical examination. A submandibular enlargement, tongue elevation, and fever are almost invariably present. Dysphagia and trismus appear to be present in other cases. A complete dental examination should be performed as part of the physical examination. Gram's stain and culture must be performed on the specimen. Prior to receiving antibiotics, a blood culture must be obtained.

Traditional X-ray pictures of the neck and chest may reveal gas in the tissue, elevated air-fluid levels, loss of normal cervical lordosis, or mediastinal enlargement, but they may not indicate the infection's spread.<sup>11,15</sup> Widening is the first roentgenographic symptom of invasion of the mediastinum. Septicemia and vascular collapse may develop as the infection advances.<sup>16</sup> Pleural and pericardial effusions, rib osteomyelitis, retropharyngeal,

parapharyngeal, and mediastinal abscesses or air collections were among the CT findings, which were frequently ill-defined and infiltrating the normal cervico-mediastinal structures.<sup>15,17-20</sup> The spread of the illness across several planes must also be considered. This necessitates an understanding of the fascial planes through which the infection spreads and which the surgeon must intercept or drain. Because of these observations, appropriate surgical drainages were possible, which are required when mediastinitis is present.

Antibiotics for Streptococci and anaerobes must be begun immediately. Penicillin and clindamycin are commonly used antibiotics. In immunocompromised patients, coverage for other gram negative organisms should be considered. The condition of one's lungs must be monitored on a regular basis. Early surgical incision and drainage are recommended in the presence of fluctuation, and extraction is recommended in the case of an infected tooth.

## CONCLUSION

Early clinical and radiological detection of such problems can lead to rapid surgical drainage, adequate antibiotic therapy, and a better chance of survival. Knowing the anatomic routes that connect the various fascial planes of the neck can help us forecast how the disease will progress.

The use of CT scans early in the treatment of these individuals tends to improve their prognosis. This fast progressing submaxillary cellulitis, although is less commonly recognised these days, can nonetheless be lethal.

*Funding: No funding sources*

*Conflict of interest: None declared*

*Ethical approval: Not required*

## REFERENCES

1. Patterson HC, Kelly JH, Strome M. Ludwig's angina: an update. *Laryngoscope*. 1982;92:370-7.
2. Rosen EA, Shulman RH, Shaw AS. Ludwig's angina: A complication of bilateral mandibular fracture. *J Oral Surg*. 1972;30:196.
3. Shafer WG, Hine NK, Levy BN. *Textbook of oral pathology*. 4th Edition. Philadelphia and London: Saunders. 1973.
4. Farmer DE, Lawton FE. In *Stones Oral and Dental Diseases*. 5th Edition. Edinburgh and London: Livingstone. 1966.
5. Tschiasny K. Ludwig's angina; a surgical approach based on anatomical and pathological criteria. *Ann Otol Rhinol Laryngol*. 1947;56(4):937-45.
6. Williams AC. Ludwig's angina. *Surg Gynecol Obstet*. 1940;70:140-9.
7. Pearse HE. Mediastinitis following cervical suppurative. *Ann Surg*. 1938;108:588-611.

8. Hall SF. Ludwig's like angina (pseudo-angina Ludovici). *J Otolaryngol.* 1984;13:321-4.
9. Scully RE, Galdabini JJ, McNeely BU. Case records of the Massachusetts General Hospital: case 15-1978. *N Engl J Med.* 1978;298:894-902.
10. Bounds GA. Subphrenic and mediastinal abscess formation: a complication of Ludwig's angina. *Br J Oral Maxillofac Surg.* 1985;23:313-21.
11. Stuteville OH. Spread of infections in the head and neck. *Int Coll Surg.* 1958;29:750.
12. Hora F. Deep neck infections. *Arch Otolaryngol.* 1963;77:129.
13. Moncada R, Warpeha R, Pickleman J, Spak M, Cardoso M, Berkow A, White H. Mediastinitis from odontogenic and deep cervical infection. *Chest.* 1978;73:497.
14. Young JN, Samson PC. Extra pleural empyema thoracis as a direct extension of Ludwig's angina. *J Thoracic Cardiovasc Surg.* 1980;80:25.
15. Barsamian JG, Scheffer RB. Spontaneous pneumothorax: an unusual occurrence in a patient with Ludwig's angina. *J Oral Maxillofac Surg.* 1987;45:161-8.
16. Payne WS, Larson RH: Acute mediastinitis. *Surg Clin North Am.* 1969;49:999.
17. Rubin MM, Cozzi GM. Fatal necrotizing mediastinitis as a complication of an odontogenic infection. *J Oral Maxillofac Surg.* 1987;45:529-33.
18. Snow N, Lucas AE, Grau M, Steiner M. Purulent mediastinal abscess secondary to Ludwig's angina. *Arch Otolaryngol.* 1983;109:53-5.
19. Levine TM, Wurster' CF, Krespi YP. Mediastinitis occurring as a complication of odontogenic infections. *Laryngoscope.* 1986;96:747-50.
20. Estrera AS, Landay MJ, Grisham JM, Sinn DP, Platt MR. Descending necrotizing mediastinitis. *Surg Gynecol Obstet.* 1983;157:542-52.

**Cite this article as:** Beedkar A, Jadhav SP, Iyer V, Gowda V, Iyer S. Ludwig's angina to retrosternal abscess: a complication of odontogenic infection. *Int Surg J* 2022;9:694-8.