

Case Report

Torsion of giant Meckel's diverticulum causing acute small bowel obstruction

M. S. Kalyan Kumar*, Vijayalakshmi V., Sabari Girieasen M., Deepika S., Kannan R.

Department of General Surgery, Rajiv Gandhi Government General hospital, Madras Medical College, Chennai, Tamil Nadu, India

Received: 05 January 2022

Accepted: 29 January 2022

*Correspondence:

Dr. MS Kalyan Kumar,

E-mail: drkalyanms@gmail.com

Copyright: © the author(s), publisher and licensee Medip Academy. This is an open-access article distributed under the terms of the Creative Commons Attribution Non-Commercial License, which permits unrestricted non-commercial use, distribution, and reproduction in any medium, provided the original work is properly cited.

ABSTRACT

Meckel's diverticulum occurs in 2% of the population and is the most common congenital anomaly of the small intestine. It is the only true diverticulum of the small intestine and occurs due to the persistence of a part of the vitello intestinal duct that does not undergo normal obliteration by the fifth to ninth week of gestation. Though the majority are clinically silent, there is a 4-6% lifetime risk of complications. Axial torsion is the rarest complication associated with Meckel's diverticulum and its coexistence with intestinal obstruction is largely unheard of with reported cases being few and far between. Here we discuss one such case of axial torsion of a giant Meckel's diverticulum associated with intestinal obstruction in an adult male.

Keywords: Meckel's diverticulum, Axial torsion, Intestinal obstruction

INTRODUCTION

Omphalomesenteric duct remains have been a source of intrigue ever since Fabricius Hildanus described a diverticulum of the small intestine in 1598. Failure of the omphalomesenteric duct to obliterate results in a broad spectrum of omphalomesenteric duct anomalies such as patent omphalomesenteric duct, omphalomesenteric cysts/bands and Meckel's diverticulum. Meckel's diverticulum remains the most common congenital anomaly of the gastrointestinal tract and is a true diverticulum occurring due to the incomplete degeneration of the intestinal end of the yolk sac.¹ It derives its blood supply from a persistent Vitelline vessel from the superior mesenteric artery or less commonly from the ileocolic artery.²

Meckel's diverticula occur in 1-2% of the population and has a slight male preponderance (2:1). Only 4-6% of individuals with Meckel's are symptomatic out of whom 50% develop symptoms by 3 years of age and 75% by 10

years of age and hence presentation in adults is highly uncommon.¹

It is located on the antimesenteric border of the ileum, 45-60cm proximal to ileocecal valve. It may exist in various forms ranging from a small bump to a long projection attached to the umbilicus by a persistent fibrous cord. The usual manifestation is a wide mouthed diverticulum measuring about 5 cm in length and upto 2 cm in diameter.³

Since the cells lining the vitelline duct are pluripotent, heterotrophic mucosa tends to develop within the Meckel's diverticulum. Ectopic gastric mucosa is the most common (50%) followed by pancreatic mucosa and very rarely, colonic mucosa all of which predispose to symptoms/complications.

Complications of Meckel's diverticulum are: Painless lower gastrointestinal bleeding -most common in children. Bowel obstruction- most common presentation

in adults, due to a variety of causes described below. Diverticulitis. Perforation. Littre's Hernia. Malignancy (0.5-2%). Axial torsion - rarest complication to be reported.

Here we discuss axial torsion of MD and loop forming mechanism of intestinal obstruction coexisting in the same patient, a combination of two complications resulting in an almost unheard of presentation reported only eleven times thus far.^{2,4,5}

CASE REPORT

A 32 years old male presented to the emergency department with complaints of abdominal pain, distension, vomiting for 5 days and obstipation for 3 days.

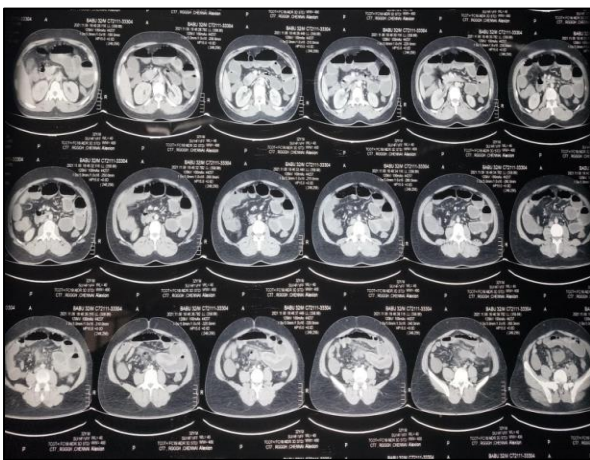


Figure 1: CT abdomen showing small bowel obstruction.

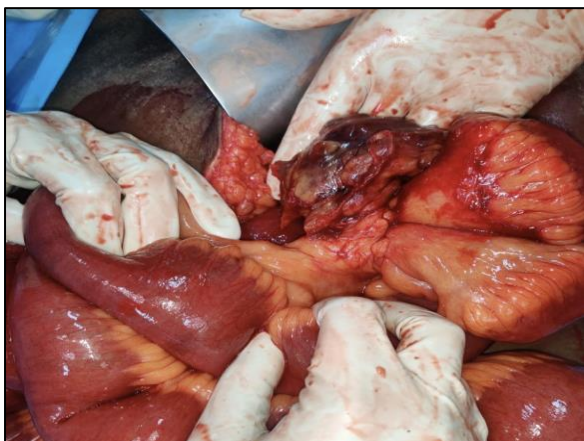

Figure 2: Giant torsed MD attached to ileal mesentery with transition point at mid ileum.

He did not have any previous history of similar episodes, surgery, tuberculosis or medical illness. His vitals were stable and per abdomen examination revealed distension, tenderness in right hypochondrium and absent bowel sounds. Erect X-ray abdomen showed multiple air fluid

levels and CT abdomen confirmed the diagnosis of small bowel obstruction with a transition point at mid ileum (Figure 1). Patient was taken up for emergency laparotomy and a giant (12.5 cm long with a 1.5 cm base) torsed, gangrenous Meckel's diverticulum was found 60cm from ileocaecal junction with its tip adherent to ileal mesentery forming a loop within which distal ileal loops were trapped causing obstruction (Figures 2, 3). The obstruction was relieved and the gangrenous diverticulum was resected along with 5 cm of adjacent small bowel whose ends were anastomosed. Post operative period was uneventful and the patient was discharged successfully on post operative day 12. Histopathology confirmed it to be a MD without any heterotrophic mucosa.

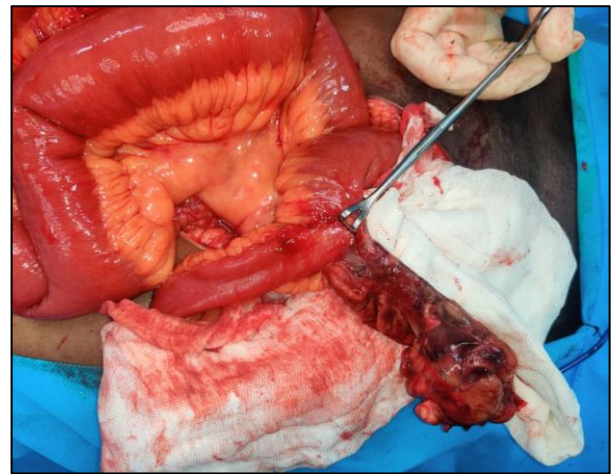


Figure 3: Axial torsion of giant Meckel's diverticulum.

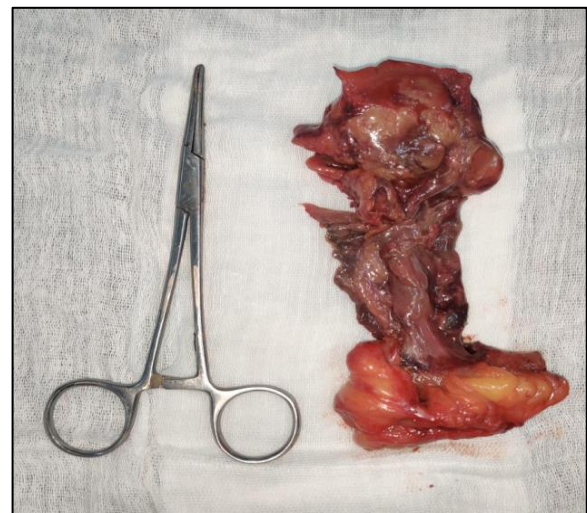

Figure 4: Giant gangrenous Meckel's Diverticulum measuring 12.5 cm.

DISCUSSION

90% of the MD are reported to be between 1-10 cm in length, with the average size being around 3 cm.

Diverticula sized ≥ 5 cm are considered to be giant MD and sizes up to even 100cm have been described.^{6,7} Giant MD are an extraordinary occurrence and are more prone to develop complications out of which axial torsion is the rarest to be described thus far.⁵

Axial torsion of MD occurs when there is: presence of a fibrous attachment between the MD and umbilicus predisposing to torsion and an elongated MD with a narrow base.

Torsion to the extent of development of gangrene is a singularly remarkable phenomenon.

Bowel obstruction is the common presentation in adults and is usually due to intussusception, Volvulus, Littre's hernia or internal hernia due to a loop of intestine trapped beneath an extramesenteric blood vessel (mesodiverticular band) or a band attaching the MD to the umbilicus. Formation of a loop by the end of MD adhering to adjacent mesentery through which bowel loops get ensnared is an uncommon mechanism of obstruction.⁴

In our patient there was no associated umbilical attachment and the axial torsion was a solitary event probably due to: the increased diverticular length and narrow base or herniation of the Ileum through the loop formed by attachment of MD to mesentery may have caused axial torsion of the MD (leading to compromise in its blood supply and subsequent gangrene) or combination of both factors.⁴

The axial torsion of MD can be incomplete/recurrent, resulting in multiple episodes of subacute intestinal obstruction or it can be a complete torsion resulting in gangrene with or without obstruction.

Pre operative diagnosis of a complicated MD is often difficult and is fraught with pitfalls as it maybe clinically indistinguishable from other causes of acute abdominal pain.

Radiological aids include: plain abdomen radiographs: have no real value in detecting MD but can pick up intestinal obstruction by virtue of air fluid levels and dilated bowel loops, contrast study- Enteroclysis (not done in an emergency setting), ultrasound- may demonstrate a blind ending, tubular structure in communication with the small bowel lumen and at a distance away from the caecum, multidetector CT- maybe useful in demonstrating MD and some of its associated complications, scintigraphy- ^{99m}Tc -pertechnetate scan is useful in cases with heterotrophic gastric mucosa in MD causing bleeding, especially in children, digital subtraction angiography- can image persistent vitelointestinal artery which can be embolised if associated with bleeding.⁸

The MD as a cause for intestinal obstruction is rarely diagnosed by preoperative imaging and is usually only

discovered during surgery and rare complications such as axial torsion are virtually impossible to identify beforehand and are almost always an on table diagnoses.⁸ Thus, surgical intervention should not be delayed to obtain additional imaging to support suspected diagnosis in a patient in the emergency room with acute abdomen.

Diagnostic laparoscopy may be considered in cases with doubtful diagnoses.

The surgical management of a complicated/symptomatic MD is quite straightforward and includes diverticulectomy or segmental resection of the ileum containing the diverticulum and relieving associated obstruction if any.

Treatment of incidentally discovered MD on the other hand is a whole other discussion shrouded in controversy and a decision for surgical resection is to be made on a personalised basis considering the patient's age and the possibility of development of future complications (including malignancy). Further prospective trials are needed to clear this dissension.³

CONCLUSION

Presence of a large Meckel's diverticulum with a relatively narrow base or attachment of its distal end to the umbilicus or ileal mesentery can predispose to axial torsion, gangrene and intestinal obstruction thus leading to significant morbidity and mortality. Since preoperative imaging is rarely ever beneficial in such patients, surgical exploration (open or laparoscopic) is always warranted in cases of acute intestinal obstruction. The diagnosis of a complicated Meckel's diverticulum must always be contemplated in a young male with intestinal obstruction and no previous history of surgery.

Funding: No funding sources

Conflict of interest: None declared

Ethical approval: Not required

REFERENCES

1. Yeo CJ. Shackelford's surgery of the alimentary tract, E-book (8th ed.). Elsevier. 2017.
2. Murruste M, Rajaste G, Kase K. Torsion of Meckel's diverticulum as a cause of small bowel obstruction: A case report. World J Gastrointest Surg. 2014;6(10):204-7.
3. Townsend JCM, Beauchamp RD, Evers BM, Mattox KL. Sabiston textbook of surgery (21st ed.). Elsevier - Health Sciences Division. 2021.
4. Cartanese C, Petitti T, Marinelli E, Pignatelli A, Martignetti D, Zuccarino M, Ferrozzi L. Intestinal obstruction caused by torted gangrenous Meckel's diverticulum encircling terminal ileum. World J Gastrointest Surg. 2011;3(7):106-9.
5. Sharma RK, Jain VK, Kamboj S, Murari K. Gangrenous Meckel's diverticulum causing acute

intestinal obstruction in an adult. *ANZ J Surg.* 2008;78(11):1046-7.

6. Akbulut S, Yagmur Y. Giant Meckel's diverticulum: An exceptional cause of intestinal obstruction. *World J Gastrointest Surg.* 2014;6(3):47-50.
7. Tisdall FF. An unusual Meckel's diverticulum as a cause of intestinal hemorrhage. *Am J Dis Children.* 1928;36(6):1218-23.
8. Kotha VK, Khandelwal A, Saboo SS, Shanbhogue AK, Virmani V, Marginean EC et al. Radiologist's

perspective for the Meckel's diverticulum and its complications. *Br J Radiol.* 2014;87(1037):20130743.

Cite this article as: Kumar MSK, Vijayalakshmi V, Girieasen SM, Deepika S, Kannan R. Torsion of giant meckel's diverticulum causing acute small bowel obstruction. *Int Surg J* 2022;9:718-21.