

## Case Report

# Granulomatous fat necrosis of breast a diagnostic dilemma: a rare case report

Aswin Mukesh, Murugan A.\*, Rajan K. V.

Department of General Surgery, Mahatma Gandhi Medical College and Research Institute, Pillaiyarkuppam, Pondicherry, India

**Received:** 28 December 2021

**Accepted:** 29 January 2022

### \*Correspondence:

Dr. Murugan A.,

E-mail: [dr.murugan18@gmail.com](mailto:dr.murugan18@gmail.com)

**Copyright:** © the author(s), publisher and licensee Medip Academy. This is an open-access article distributed under the terms of the Creative Commons Attribution Non-Commercial License, which permits unrestricted non-commercial use, distribution, and reproduction in any medium, provided the original work is properly cited.

## ABSTRACT

Fat necrosis in breast is a rare benign condition, which can mimic carcinoma and Tuberculosis (TB) of breast in both clinical and radiological assessment. Histopathology in such cases may distinguish granulomatous lesion from carcinoma, however granulomas are identified in both fat necrosis and tuberculosis which is difficult to differentiate. Fat necrosis in breast is often not associated with axillary lymph nodes, which can differentiate fat necrosis from tuberculosis and breast carcinoma. But high index of suspicion is always required. We hereby report a case of a 40-year old female, who presented with lump in the right breast which lead to diagnostic dilemma.

**Keywords:** Tuberculous mastitis, Breast, Carcinoma breast, Tuberculosis, Breast lump

## INTRODUCTION

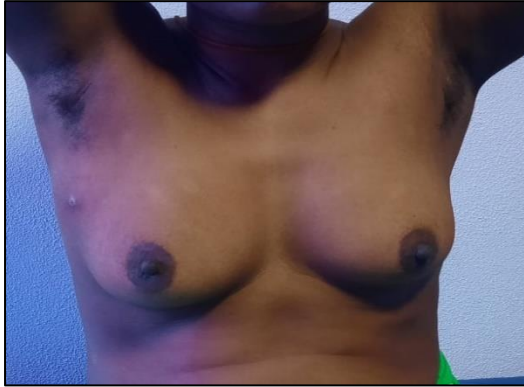Tuberculous mastitis is a rare form of extrapulmonary tuberculosis accounting for <0.1% of breast lesion in western countries and 3-4% in tuberculosis endemic areas, such as India and Africa.<sup>1</sup> Sir Astley Cooper, first reported the case of tuberculous mastitis in 1829.<sup>2</sup> Granulomatous fat necrosis is another benign non suppurative inflammatory process of adipose tissue, which most commonly occurs as a result of trauma (20-70%), radiotherapy, anticoagulation (warfarin) therapy, duct ectasia and breast infection.<sup>3</sup> The incidence of fat necrosis of the breast is reported to be 0.6% accounting to 2.75% of the overall breast lesions.<sup>3,4</sup> Clinical presentation of patients in both the conditions, would be similar with asymptomatic incidental lump in the breast or with dull aching pain in the breast. It can be challenging to differentiate TB mastitis and granulomatous fat necrosis, both by clinical and radiological assessment, as they can present with hard lump and have a variable appearance with irregular

masses on ultrasound and Magnetic resonance imaging (MRI).<sup>3,4</sup> We report a case of breast lump diagnosed to be Tuberculous mastitis which was initially diagnosed as granulomatous fat necrosis.

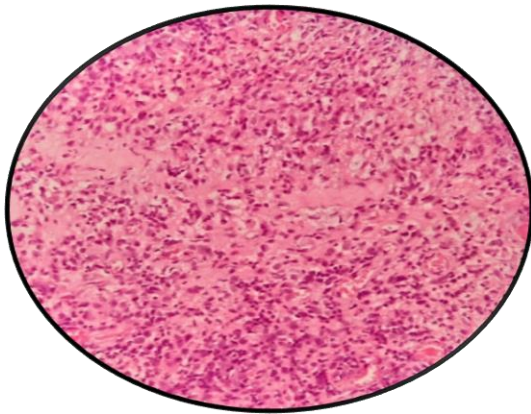
## CASE REPORT

A 40-year old female presented with complaints of incidentally noticed progressing lump in the right breast for 2 months. Associated with dull aching pain over the lump for 30 days with history of loss of appetite and loss of weight. No history of nipple discharge or retraction and no similar complaints in the opposite breast. Examination of right breast revealed a hard lump of 3×2 cm over the upper outer quadrant with ill-defined margins, nodular surface not fixed to underlying muscle. There were no palpable ipsilateral or contralateral axillary lymph nodes. Proceeded with Ultrasound of breast, which revealed Breast imaging reporting and data system (BIRADS) score of IV; possibility of carcinoma breast. Core needle biopsy of the lump was done and

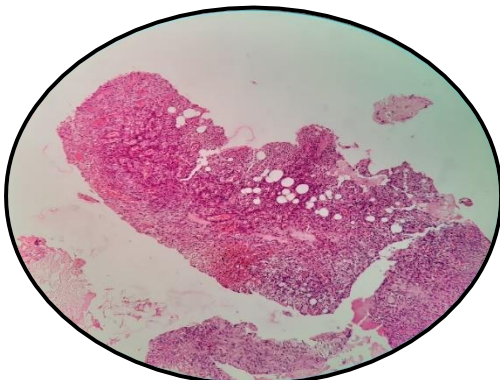
histopathological investigation showed fibro collagenous tissue with dense inflammatory infiltrate, granulomatous lesion suggestive of fat necrosis (Figure 2).



**Figure 1: Discharging sinus at trucut site over breast lump.**



**Figure 2: Histopathological picture showing fibro collagenous tissue with dense inflammatory infiltrate composed of histiocytes, lymphocytes and plasma cells, suggesting granulomatous lesion.**



**Figure 3: FNAC of lymph node showing, polymorphous population of lymphoid cells composed predominantly of small mature lymphocytes admixed with few plasma cells, well formed granuloma in a necrotic background suggestive of tuberculosis.**

X-ray chest, complete blood count and erythrocyte sedimentation rate (ESR) were normal. Since there was a diagnostic dilemma in tuberculosis/ fat necrosis, patient was planned for excision biopsy of the lump and was lost for follow up. Later patient presented with lump fixed to the skin with discharging sinus at the trucut biopsy site with ipsilateral matted lymph nodes in the central group of the axilla (Figure 1) which was not evident during examination on previous visit. Fine Needle Aspiration Cytology (FNAC) of axillary lymph node was done, which showed features of necrotizing granulomatous lesion suggestive of tuberculosis (Figure 3). Hence, the patient was started on Category I Antitubercular treatment (ATT) for 6 months and she responded well at 4 months of follow up with decrease in lump and disappearance of axillary lymph node.

## DISCUSSION

Tuberculosis of the breast is a very rare benign disease, with age of the patients ranging between 20 and 40 years.<sup>5</sup> Which corresponds to the age of our patient. Primary tuberculosis is very rare in most of the cases, wherein spread occurs through direct inoculation of bacilli through abrasion in the nipple. Like skeletal muscles and spleen, breast tissue provides an unfavorable environment for the tubercle bacilli, which explains the lower incidence of Tuberculosis in the breast.<sup>6</sup> Secondary tuberculosis of breast is more common than primary and few theories have been postulated for understanding the mode of spread. Among which, most commonly spread occurs via lymphatics by retrograde extension from the axillary node, followed by contiguous spread from ribs, pleural space or rectus sheath from an intra-abdominal source or by hematogenous spread.<sup>2,7</sup>

Three distinct types of breast tuberculosis have been described namely, nodular, sclerosing and disseminated. The most common type is the nodular variety which presents as lump and abscess formation. Sclerosing type presents as a hard lump with extensive fibrosis. Disseminated/ diffuse type presents with multiple abscess and discharging sinuses.<sup>4,5,7</sup> Most common presentation of patients are with breast lump in the central or upper outer quadrant. Breast lump with multiple sinuses or ulcers are other form of clinical presentation, with matted lymph nodes in the ipsilateral axilla.<sup>6,8,9</sup> Our patient had breast lump with discharging sinus at biopsy site and an evident axillary lymph node only during the follow up, which aided in the diagnosis of Tuberculosis.

Radiological studies like mammogram and USG may mislead in diagnosis and differentiating tuberculosis of breast, granulomatous fat necrosis and carcinoma of breast, as seen in our case, where in USG was suggestive of carcinoma of breast. Rather USG would aid in locating suspicious area for guiding FNAC. Gold standard for the diagnosis of tuberculosis of breast is by Mycobacterial culture or by Ziehl Nielson (ZN) stain, but it is often negative due to the paucibacillary nature of tuberculosis

in the breast.<sup>2,8,9</sup> Tuberculous bacilli are isolated only in 25% of case and Acid Fast Bacilli (AFB) are isolated only in 12% of the patients.<sup>2</sup> It has been reported that, overall positivity rate for AFB in nipple discharge, FNAC and tissue samples was only 12.0%–22.7%. Given the high rate of AFB-negative stains in breast tissue and the overlap of clinical presentation, direct amplification tests may serve as a valuable tool for diagnosis of breast tuberculosis. Nucleic acid amplification tests like PCR (Polymerase chain reaction) though are rapid and specific, but reported to be carrying a low sensitivity rate of 50%.<sup>8,10</sup>

FNAC is the most preferred initial investigation of choice for any breast lump or enlarged lymph node. Evidence of caseating granulomas in FNAC of breast tissue and involved lymph node is sufficient to diagnose Tuberculous mastitis. It was found that approximately 73% of Tuberculous mastitis can be diagnosed by FNAC alone.<sup>2</sup> In our case initial biopsy obtained from the breast lesion demonstrated only granulomas with absence of caseation, which lead to the diagnostic dilemma of granulomatous mastitis for which the treatment is different from TB mastitis. The treatment of granulomatous mastitis will require combination of both surgery and steroid therapy. Whereas steroid therapy may flare up tuberculosis if it was misdiagnosed.<sup>2</sup> In our case report, patient later on presented with axillary lymph node enlargement, FNAC of which revealed caseating granuloma suggestive of Tuberculosis.

Histologically, breast tuberculosis is a form of granulomatous inflammation. Granulomatous fat necrosis and Tuberculous mastitis may show similar findings in histopathological examination, like epithelioid cells, giant cells and Langerhans cells, absence of necrosis or presence of Acid-fast Bacilli differentiates from granulomatous mastitis.<sup>10</sup> However, failure to demonstrate necrosis on FNAC does not exclude tuberculosis. Other disease like sarcoidosis, granulomatous mastitis, fungal infections such as actinomycosis, plasma cell mastitis, and traumatic fat necrosis may show a tuberculoid type tissue reaction indistinguishable from tuberculosis.<sup>10,11</sup>

Treatment of breast tuberculosis with standard anti tubercular regimen for 6 months provides excellent results. Two months of intensive phase with isoniazid, rifampicin, pyrazinamide and ethambutol and four months of continuation phase with isoniazid and rifampicin.<sup>8,9</sup> The main management principle of TB mastitis is to start Anti tubercular treatment and to avoid mastectomy. Surgical intervention is reserved for draining cold abscesses and excision of the lump if there is poor response to anti-tubercular therapy with residual lump. Simple mastectomy is indicated only in patients with persistent and diffuse disease. Modified radical mastectomy is rarely indicated for patients with co-existent malignancy.<sup>4,6,12</sup> Our patient was started on Anti

tubercular treatment with better response at 4 months of follow up.

## CONCLUSION

Granulomatous mastitis can mimic both tuberculosis and carcinoma. However histopathological diagnosis is required for prompt diagnosis and treatment. Hence a high index of suspicion for TB mastitis should be considered in granulomatous fat necrosis, especially in our country.

*Funding: No funding sources*

*Conflict of interest: None declared*

*Ethical approval: Not required*

## REFERENCES

1. Kumar R, Laxman S, Parandekar P. Breast lump: A rare presentation of tuberculosis. *Int J App Basic Med Res.* 2018;8(3):187.
2. Baharoon S. Tuberculosis of the breast. *Ann Thorac Med.* 2008;3(3):110.
3. Kerridge WD, Kryvenko ON, Thompson A, Shah BA. Fat Necrosis of the Breast: A Pictorial Review of the Mammographic, Ultrasound, CT, and MRI Findings with Histopathologic Correlation. *Radiology Research and Practice.* 2015;2015:1-8.
4. Illman JE, Terra SB, Clapp AJ, Hunt KN, Fazzio RT, Shah SS, et al. Granulomatous diseases of the breast and axilla: radiological findings with pathological correlation. *Insights Imaging.* 2018;9(1):59-71.
5. Mirsaeidi SM, Masjedi MR, Mansouri SD, Velayati AA. Tuberculosis of the breast: report of 4 clinical cases and literature review. *East Mediterr Health J.* 2007;13(3):670-6.
6. Khandelwal R, Jain I. Breast tuberculosis mimicking a malignancy: a rare case report with review of literature. *Breast Dis.* 2013;34(2):53-5.
7. Thimmappa D, Mallikarjuna MN, Vijayakumar A. Breast Tuberculosis. *Indian J Surg.* 2015;77(Suppl 3):1378-84.
8. Sriram K, Moffatt D, Stapledon R. Tuberculosis infection of the breast mistaken for granulomatous mastitis: a case report. *Cases J.* 2008;1:273.
9. Marinopoulos S, Laurantou D, Gatzionis T, Dimitrakakis C, Papaspyrou I, Antsaklis A. Breast tuberculosis: Diagnosis, management and treatment. *International Journal of Surgery Case Reports.* 2012;3(11):548-50.
10. Baykan AH, Sayiner HS, Inan I, Aydin E, Erturk SM. Primary breast tuberculosis: imaging findings of a rare disease. *Insights Imaging.* 2021;12(1):19.
11. Khurram M, Tariq M, Shahid P. Breast cancer with associated granulomatous axillary lymphadenitis: a diagnostic and clinical dilemma in regions with high prevalence of tuberculosis. *Pathol Res Pract.* 2007;203(10):699-704.

12. Teo THP, Ho GH, Chaturverdi A, Khoo BKJ. Tuberculosis of the chest wall: unusual presentation as a breast lump. *Singapore Med J.* 2009;50(3):e97-99.

**Cite this article as:** Mukesh A, Murugan A, Rajan KV. Granulomatous fat necrosis of breast a diagnostic dilemma: a rare case report. *Int Surg J* 2022;9:711-4.