

## Case Series

# A rare presentation of ruptured amoebic liver abscess with caecal perforation - a case series

V. Kopperunde, Vimala G.\*, Sai Vyshnavi Y., Kannan R.

Department of General Surgery, Madras Medical College, RGGGH, Chennai, Tamil Nadu, India

**Received:** 06 December 2021

**Accepted:** 31 December 2021

### \*Correspondence:

Dr. Vimala G.,

E-mail: vimalachandrasekaran72@gmail.com

**Copyright:** © the author(s), publisher and licensee Medip Academy. This is an open-access article distributed under the terms of the Creative Commons Attribution Non-Commercial License, which permits unrestricted non-commercial use, distribution, and reproduction in any medium, provided the original work is properly cited.

## ABSTRACT

A rare complication of simultaneous rupture of liver abscess with caecal perforation occurs mainly in malnourished patients and carries a high mortality rate. In invasive amoebiasis, the trophozoites penetrate the intestinal mucosal layer causing amoebic colitis which is carried along the portal circulation to produce liver abscess that is more prone to rupture in cases of immunocompromised status. Here we report 4 cases of ruptured liver abscess associated with caecal gangrene which were operated at our institute. All 4 patients were male who were chronic alcoholics and presented with ruptured amoebic liver abscess and simultaneous perforation of caecum that was identified on exploratory laparotomy. The different approaches to surgical management of these patients is discussed, wherein early identification and timely intervention remain as mainstay of treatment in all cases.

**Keywords:** Ruptured liver abscess, Caecal gangrene, Perforation, Colitis, Immunocompromised

## INTRODUCTION

Amoebiasis with its subset disease spectrum is a common parasitic infection distributed among all socioeconomic groups of patients and regions producing diarrhoea, colitis and amoebic liver abscess predominantly in tropical countries.

Around 80% are asymptomatic and the remaining 20% land up in fulminant colitis with colonic perforation and rupture of liver abscess into the peritoneal, pleural or pericardial cavities. Rupture of amoebic liver abscess is an important cause of morbidity and mortality with incidence between 6-9%.<sup>1,2</sup>

Perforation of the colon from amoebiasis is very infrequent.<sup>3,4</sup> Ruptured liver abscess with gangrene and perforation of cecum is a rare condition presenting as acute abdomen with high mortality especially in patients who are malnourished.

## CASE SERIES

### Case 1

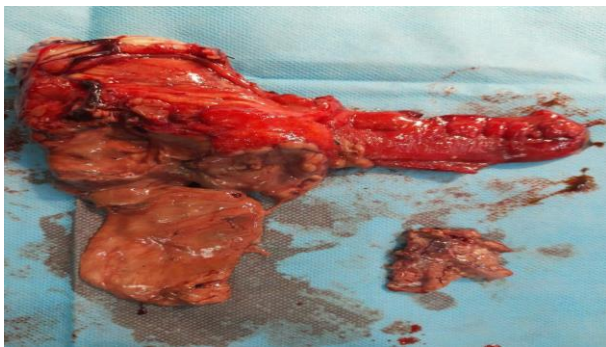
A 66 year old male patient with no known comorbidities came to the emergency department with complaints of abdominal pain for 5 days and abdominal distension for 3 days. Patient gave a history of intermittent fever and altered bowel habits 1 week ago. Patient is a chronic alcoholic for the past 35 years.

On examination, the patient was dehydrated, tachypneic blood pressure (BP) 100/60 mmHg, pulse rate (PR): 116/min. Abdominal examination revealed a distended abdomen, with tenderness and guarding in the right iliac fossa and right hypochondrium.

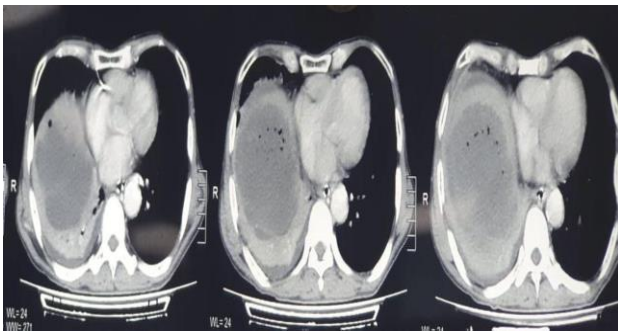
Ultrasound abdomen revealed a well-defined hypoechoic lesion of size 8×7 cm in segment 7 of the liver. 2×3 cm lesion in segment 8 of liver.

Contrast enhanced computed tomography (CECT) abdomen with intravenous contrast showed multiple well defined hypodense lesions with peripheral rim enhancement in segment 7, 8 of size 11.8×9.2 cm with multiple air pockets. Evidence of large subdiaphragmatic collection extending into the right paracolic gutter, subhepatic, right iliac fossa with large air pockets (Figure 2). Possibility of right lobe liver abscess with rupture was considered.

Patient was taken up for emergency laparotomy in view of peritonitis which revealed 400 ml of pyoperitoneum with omentum found adherent to the caecum. Caecum was found to be sloughed out, gangrenous and perforated. Proceeded with limited resection of caecum, ascending colon with distal ileum (Figure 1) with distal ileostomy and proximal ascending colostomy.



**Figure 1: Specimen showing resected caecum, ascending colon and terminal ileum.**



**Figure 2: CT image showing liver abscess in segment 7, 8 of size 11.8×9.2 cm with multiple air pockets and subdiaphragmatic collection.**

Patient was positive for amoebic serology which was taken in the immediate postoperative period. Patient was started on an oral diet on day 2 and pig tail drainage of the residual liver abscess was done on post-operative day (POD) 10 due to complaints of persistent abdominal pain. Patient was discharged on POD 20.

**Case 2**

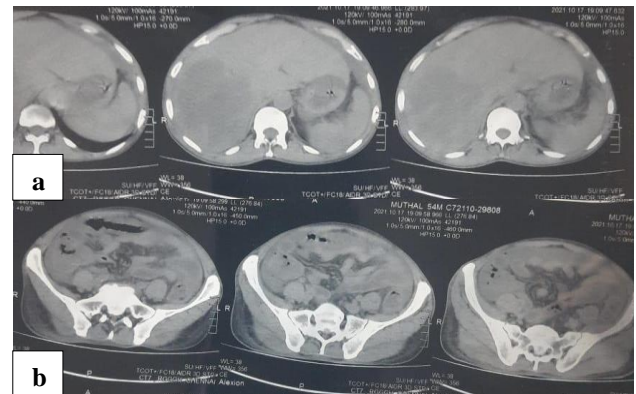
A 65 year old male with no known comorbidities presented to the emergency department with complaints of

abdominal pain and distension for 6 days. He gave a history of passing loose stools with blood and mucus for the past 20 days. Patient is a chronic alcoholic for the past 25 years.

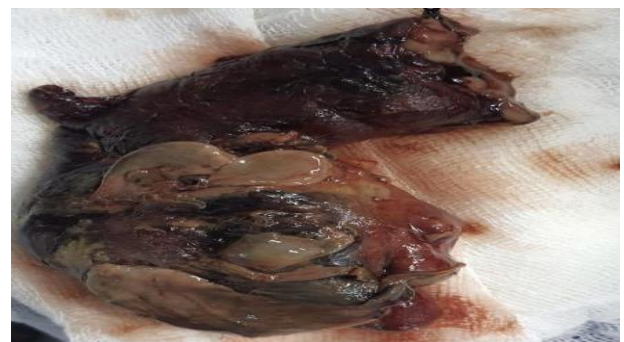
On examination the patient was dehydrated, pale, tachypneic with hypotension and tachycardia. Patient was resuscitated with IV fluids, oxygen and IV antibiotics, blood and blood products.

Ultrasonography of the abdomen revealed hypoechoic lesions in segment 6, 7 and 8 of the right lobe of liver with free fluid present in the pelvis. CECT of abdomen revealed ruptured liver abscess with abscess cavity in the segment 6, 7 and 8 of size 11.8×9.5×13 cm with peripheral enhancement and multiple central air pockets (Figure 3a and 3b). Evidence of right subdiaphragmatic collection with air pockets of size 2.6×6.1 cm, with free fluid abdomen. Possibility of ruptured liver abscess with subdiaphragmatic collection and moderate ascites.

Patient was taken up for emergency laparotomy which revealed a ruptured abscess in segment 7 of liver with cecal gangrene and perforation of size 5×4 cm (Figure 4). Peritoneal lavage, drainage of abscess with limited resection of caecum and ascending colon was done along with end ileostomy and transverse colon mucous fistula.



**Figure 3: CT abdomen showing (a) segment 6, 7 and 8 of size 11.8×9.5×13 cm; and (b) air pockets in right paracolic gutter with free fluid.**



**Figure 4: Resected specimen showing gangrenous caecum with perforation and ascending colon.**

Histopathological examination of the specimen revealed haemorrhagic enterocolitis of infectious origin, with chronic appendicitis and periappendicitis. Amoebic serology done in the immediate postoperative period turned out to be positive. Patient succumbed 36 hours after surgery due to sepsis.

### Case 3

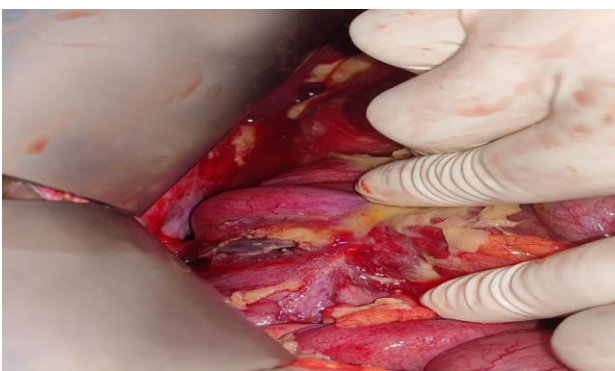A 70 year old male patient with no known comorbidities came to the emergency department with complaints of abdominal pain for the past 1 month, more over the right lower abdomen that aggravated in the past 1 week. Patient also gives complaints of obstipation for 3 days and vomiting for 3 days that was bilious, non-projectile and aggravated on food intake. History of intermittent fever for the past 1 month. Patient gives a positive history of diarrhoea in the past 1 month.

Patient is a chronic alcoholic for the past 30 years. On examination, the patient was conscious, oriented, a febrile, BP: 110/70 mmHg and tachycardia. Abdomen examination findings include a distended abdomen, with diffuse guarding and rigidity on the right iliac fossa and right hypochondrium. Bowel sounds -absent. Per rectal examination was unremarkable.

Ultrasound abdomen showed multiple liver abscess in the segment 5 and 6 and one in segment 8 with free fluid abdomen.

CECT abdomen showed moderate ascites with ruptured liver abscess from segment 6 of size 7.8×6.9 with collection in the right paracolic gutter and ascending colon thickening.

Patient was taken up for an emergency laparotomy in view of peritonitis. Around 300 ml of purulent fluid aspirated. A large discharging abscess in the anterior segment of the liver - right lobe in segment 5 and 6 and one in segment 8.



**Figure 5: Caecal perforation of size 1×1.5 cm.**

Laparotomy of large bowel showed caecal perforation of size 1×1.5 cm and thickening of the ascending colon (Figure 5). Thorough wash of the peritoneal cavity and abscess cavity was given. Primary closure of the caecal

perforation was done and proximal loop ileostomy was created. Bleeding from the abscess cavity continued despite transfusion of blood and blood products. Liver was then packed with 5 gauze pads and the abdomen closed in layers. Patient expired in the intensive care unit (ICU) postoperatively due to sepsis. Amoebic serology in the immediate postoperative period was positive.

### Case 4

A 55 year old male came to the emergency department with complaints of diffuse abdominal pain for 4 days that typically started around the umbilicus and then involved the entire abdomen. Patient gives history of vomiting - multiple episodes per day for 4 days, that was non projectile and bilious. No other history of fever, constipation or obstipation. No history of passing blood in stools.

Patient gives a past history of liver abscess that was drained by a percutaneous method 3 months back.

Patient is a chronic smoker and chronic alcoholic for the past 30 years.

On examination patient was conscious, oriented, emaciated, poorly built and nourished, dehydrated, BP: 100/70 mmHg, PR: 123/min, per abdomen examination - distended abdomen, diffuse tenderness and guarding over the right hypochondrium, epigastric, right iliac, periumbilical regions, bowel sounds – absent, and per rectal examination: tone normal with fecal staining.

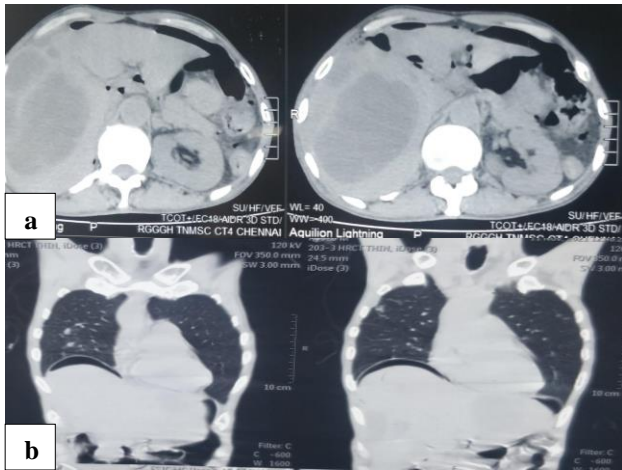
Lab investigations revealed severe anemia and coagulopathy.

Patient was resuscitated with IV fluids, blood and blood products.

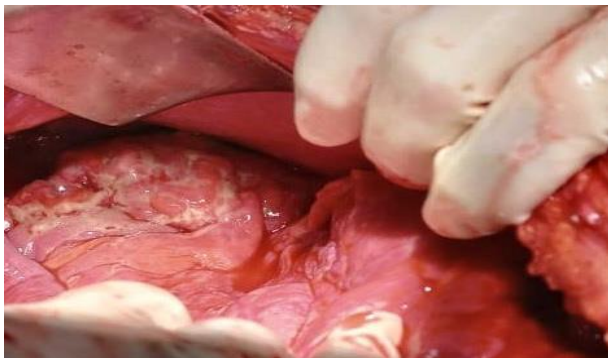CECT of abdomen was done which revealed multiple well defined loculated hypodense lesions involving the segment 5, 6, 7 and 8 of right lobe and segment 2, 3 of left lobe largest measuring 9.7×8.9 cm in segment 7, 8. Pneumoperitoneum noted with free fluid in abdomen and pelvis (Figure 6a and 6b).

After optimizing the patient hemodynamically, the patient was taken up for emergency laparotomy. About 500 ml of purulent fluid aspirated. Ruptured abscess cavity found in right lobe of liver in segment 8. A perforation of size 0.5×0.5 cm found in the anterior wall of caecum (Figure 7). Proceeded with primary closure of caecal perforation and fashioning of proximal loop ileostomy. Patient was diagnosed with pulmonary tuberculosis and started on ATT postoperatively. Patient was started on an oral diet on POD 2 and discharged on POD 10 after inserting percutaneous drainage for the residual liver abscess.

Patient tested positive for amoebic serology.



**Figure 6: CT abdomen showing (a) hypodense lesions in segment 5, 6, 7 and 8 of right lobe (9.7x8.9 cm); and (b) pneumoperitoneum and free fluid.**



**Figure 7: Intraoperative image showing a caecal perforation of size 0.5x0.5 cm.**

## DISCUSSION

*Entamoeba histolytica* is primarily an intra-luminal living organism of the large bowel. The transmission of intestinal amoebiasis is via the oro faecal route after consumption of an amoebic cyst. The cysts travel to the large intestine where they release the trophozoites that invade the bowel wall. The lesions are primarily located in the large intestine though some may be seen in the terminal ileum. Initial lesions are more commonly localized in those fields where the colonic flow is slow, likely the caecum and rectosigmoid.

The initial lesion may be the size of a pinhead, but with rise in mucosal edema central ulceration results. Ulceration is mainly localized to mucosal epithelium and lamina propria. But when the ulcers progress to the muscularis propria they extend laterally along the axis of the intestine undermining the overlying mucosa.

The communication of these laterally spreading ulcers with the intestinal lumen through a narrow mucosal defect creates the so-called "flask-like" ulcers. These adjacent ulcers may coalesce, leading to larger mucosal defects.

Sometimes In advanced cases, ulcers progress beyond the muscularis propria and penetration results in a perforation of the intestinal wall. These perforations commonly occur in the caecum.<sup>5</sup>

Amoebic liver abscess is the commonest extra-intestinal complications of amoebiasis. The onset of hepatic symptoms may be gradual or rapid. Liver abscesses are most commonly located in the right lobe and may be single or multiple. An early abscess initially presents with a minor area of parenchymal necrosis with greyish-brown cut surface. As the area of necrosis increases in size, the central portion of the abscess liquifies and thereby a cavitation results. The content of the cavity is usually sterile, non-pyogenic, viscid and has been given the characteristic name of "anchovy paste".

The incidence of intraperitoneal rupture of amoebic liver abscess is between 6-9 percent. They may also rupture into the pleural, pericardial cavities.

Both of the above complications occurring simultaneously is very rare and there are literature supports that have reported cases of ruptured/unruptured liver abscess with caecal perforation with a very mortality rate. Mukherjee et al documented a single case of amoebic bowel perforation who died 48 hours post-surgery.<sup>6</sup> Eggleston et al studied 26 cases of perforations of the bowel, out of them 6 cases had un-ruptured liver abscess, and all 6 patients died of postoperative sepsis shortly.<sup>7,8</sup>

In our series of 4 cases, 3 of them had a history of altered bowel habits with abdominal pain and intermittent fever for 1 month prior to admission. 1 patient was a known case of liver abscess diagnosed 3 months back. All patients had tested positive for amoebic serology in the immediate postoperative period.

There was an element of immunosuppression in all 4 patients. They had a history of chronic alcohol consumption and one patient was on anti tuberculous therapy for pulmonary tuberculosis.

### *Surgical intervention*

Early surgical intervention remains the mainstay of treatment in all cases of ruptured liver abscess with peritonitis. All 4 patients were subjected to emergency exploratory laparotomy in view of peritonitis. 2 patients had caecal gangrene and associated perforation for which resection of caecum, ascending colon and terminal ileum had to be done with end ileostomy and mucous fistula. 2 patients had their caecal perforation closed primarily and a proximal defunctioning loop ileostomy was fashioned. 2 patients expired in the immediate postoperative period after 36 hours due to sepsis which depicts the high mortality rate of the condition.

Talukder et al suggested that unless there is compelling reason for resection of the colon as in frank gangrene,

resection must be avoided.<sup>9</sup> In unavoidable cases defunctioning ileocolostomy is preferable to primary anastomosis.

## CONCLUSION

Perforation of caecum is an uncommon condition that poses a diagnostic dilemma. Simultaneous presentation of ruptured amoebic liver abscess with bowel perforation is an extremely rare entity and carries a very poor prognosis with a very high mortality rate especially in patients who are immunosuppressed and are chronic consumers of alcohol. Treatment is aimed at early identification of complications of liver abscess and having a high degree of suspicion and subsequent appropriate timely intervention.

*Funding: No funding sources*

*Conflict of interest: None declared*

*Ethical approval: Not required*

## REFERENCES

1. World Health Organization. Amoebiasis. Wkly Epidemiol Rec. 1997;72:97-100.
2. Majeed SK, Ghazanfar A, Ashraf J. Caecal amoeboma simulating malignant neoplasia, ileocaecal tuberculosis and Crohns disease. J Coll Physicians Surg Pak. 2013;13:116-7.
3. DeBakey ME, Oschner A. Hepatic amoebiasis – a 20 year experience and analysis of 263 cases. Int Abstr Surg. 1951;92:209-31.
4. Kean BH, Gilmore HR, Van Stone WW. Fatal amoebiasis-report of 148 fatal cases from Armed Forces Inst.of Pathology. Ann Int Med. 1956;44:831-8.
5. Rives JD, Heibner WC, Powe UJL. The surgical complications of amoebiasis of the colon. Surg Clin North Am. 1955;35:1421-6.
6. Radke RA. Ameboma of the intestine; An analysis of the disease as presented in 78 collected and 41 previously unreported cases. Ann Int Med. 1965;43:1048-66.
7. Mukerjee S, Nigam M. Amoebic perforation of the colon. Amer Proctol. 1975;26(2):57-64.
8. Eggleston FC, Verghese M, Handa AK. Amoebic perforation of the bowel: experience with 26 cases. Brit Surg. 1978;65:748-51.
9. Talukder BC. Surgical complications of amoebiasis and their diagnostic problems. Ind Med Assoc. 1978;70(8):187-9.

**Cite this article as:** Kopperundevi V, Vimala G, Vyshnavi SY, Kannan R. A rare presentation of ruptured amoebic liver abscess with caecal perforation - a case series. Int Surg J 2022;9:454-8.