

## Original Research Article

# Long segment “Hanging-snout” end ileostomy a safe “Surgical disaster mitigating” technique for an “Un-brookeable” end ileum: a study of 23 cases over 12 years

M. S. Ray<sup>1</sup>, Sarvpreet Singh Malhi<sup>1\*</sup>, Jayum Asopa<sup>1</sup>, Harpreet Kaur<sup>1</sup>,  
Manvinder Singh Grewal<sup>1</sup>, Naresh Modi<sup>1</sup>, Digpal Thakore<sup>1</sup>, Rashmi Ray<sup>2</sup>

Department of General Surgery, SGT University, Gurugram, Haryana, India  
Department Obstetrics and Gynaecology, SGT University, Gurugram, Haryana, India

**Received:** 23 November 2021

**Revised:** 07 December 2021

**Accepted:** 08 December 2021

### \*Correspondence:

Dr. Sarvpreet Singh Malhi,  
E-mail: sarvmalhi@gmail.com

**Copyright:** © the author(s), publisher and licensee Medip Academy. This is an open-access article distributed under the terms of the Creative Commons Attribution Non-Commercial License, which permits unrestricted non-commercial use, distribution, and reproduction in any medium, provided the original work is properly cited.

## ABSTRACT

**Background:** In 1952, Professor Bryan Brooke described his technique for everting an ileostomy in order to minimise skin excoriation<sup>1</sup>. Pouting, mucosa-everting Brooke’s ileostomy have been accepted as the best technique for stoma formation in almost all cases, save a few difficult situations – such as edematous friable bowel with bulky short mesentery! In such cases formation of standard Brooke’s ‘Pouting’ ileostomy is not only difficult, but an impossible and a dangerous surgical exercise! In these situations where the bowel is “Un-Brookeable” due to aforementioned causes. Over a period of 12 years we could devise a formula – “Ray’s Criteria” to decide at operation, if a given ileum in a particular patient, is safely “Brookeable” (i.e. evertable into a neat Brooke, spouting ileostomy) or is “Un-Brookeable”.

**Methods:** 23 patients were included in this study over 12 years, who due to the peculiarity of their body morphology (obesity or thick abdominal fat), edematous friable bowel with bulky mesentery, the ileum could not be drawn outside the abdomen and everted as Brooke’s ileostomy. The “Brookeability” of the exteriorized ileum was decided based on satisfying two issues of Ray’s criteria.

**Results:** By using “Ray’s criteria”, we could segregate patients safely as “Brookeable” and “Un-Brookeable”. Those deemed “Un-Brookeable” underwent “Long segment Hanging snout” end ileostomy, which is the theme of our study.

**Conclusions:** We are emphatic in stating that by using “Ray’s criteria” we could accurately segregate cases into “Brookeable” and “Un-Brookeable” ileum.

**Keywords:** Brooking, Restoration of bowel continuity, Un-Brookeable, Ray’s criteria

## INTRODUCTION

*“Hell hath seen no furry like a gut scorned !”*

An ileostomy is a pouted bud like stoma of an exteriorized terminal ileum, which is sited at a pre-selected suitable area of the abdomen and suture anchored to the skin, often temporarily and at times permanently (In Greek ‘stoma’ means ‘mouth’). This

ileostomy acts like an “Artificial Anus” on the abdomen, to divert intestinal fecal stream into a skin- attached receptacle. Creation of an ileostomy is a life-saving surgical procedure for egress of “liquid feces”, the by-product of food digestion, which is charged with highly corrosive gut juices and is teeming with deadly gut bacteria. The gut juices and bacteria when confined to the hermetically sealed walls of the bowel, render a ‘saintly service’ to us. They are our “Rakshak” (Sanskrit

Protector), but their breakout from a breached gut into the organ spaces of the body, transforms these “Rakshaks” into “Bhakshak” (Sanskrit Destroyer/Devourer), unleashing bacterial toxins, causing sepsis, multi-organ failure and death. It’s a situation where we have to save us from ourselves!

With the advent of laparotomy in nineteenth century, surgeon soon realized that in certain difficult surgical situation, it was not always safe to repair or restore the continuity of the bowel by anastomosis, and allow the intestinal content ( the liquid feces) to follow its natural course through such a segment of gut, to anus. In such cases fecal diversion by an “Enterostomy”, often as Brooke’s everting end ileostomy is a life saving surgical effort!

But to create a Brooke’s everting end ileostomy in an obese patient with abundant abdominal fat and having loaded “sick – bowel” is not only a futile effort but a dangerous surgical venture, with high morbidity and mortality. Our study attempted to answer such a situation by “Long segment Hanging Snout end ileostomy”. (In German –snout is projecting nose or trunk).<sup>1</sup>

### Objectives

In Emergency setup, we are faced with edematous, friable, very “sick bowel”. Hence if brooking is done than it can lead to complications such as: Ileal serositis which can lead to annular stenosis or tearing through the ileum, which can be nightmare for surgeon, Hence we are conducting this study to anticipate that in which patients the Brooking can be performed easily with less complications.

### METHODS

The study was a pilot prospective study was conducted of 23 patients by the lead author of this article, between January 2007 to December 2020.

All 23 cases over 12 years had undergone emergency laparotomy for trauma (gun-shot wound abdomen or crush injury torso) or natural diseases (as abdominal tuberculosis, adhesions obstruction). All our cases because of soiled, friable, edematous bowel had undergone “covering stoma” by long segment hanging snout end ileostomy with “Bogotised” closure of abdomen (Bogota bag closure of abdomen).

Sample size was calculated by using snowball sampling method. As there was paucity of patients requiring Ileostomy in our hospital. Hence all the patients coming in between January 2007 to December 2020 were included in study.

The Ethical approval was taken from the SGT University, Ethical committee.

### Statistical method

No statistical analysis was done in this study, as it is a pilot prospective study.

### Inclusion criteria

Our study included those cases whose body morphology and condition of the bowel were not deemed fit to undergo a safe and a neat eversion of the terminal ileum as Brooke’s end ileostomy. We termed them as “Un-Brookeable” end ileum. The un-brookeability of end ileum were decided by the following: (a) patient specific condition such as obese patient, abdominal obesity (belly fat), “Hostile” (scarred) abdomen due to disease, surgery or trauma, (b) Bowel specific condition such as edematous bowel (due to disease, obstruction, dessication, over hydration, “Third spacing” due to sepsis, hypoproteinemia, N<sub>2</sub>O (Nitrous Oxide) – anaesthetic gas and surgical “Manhandling”), bowel ischemia, short fatty mesentery, (c) Ray’s “Brookeability” ariteria such as criteria I (criteria of ileal length), in this the length of exteriorized ileum more than 7 cm, criteria II (Ray’s Equation of Brookeability):

$$Id > [ 2 (Bwt) + 2 (Mt) ]cm + Pk$$

where, Id = Internal diameter of the ileum, Bwt = Bowel wall thickness, Mt = Mesenteric thickness of end ileum, Pk = ‘Potential Konstant’ (constant) of 0.5 cm potential space is to be ensured in the internal calibre of the brooked ileum to neutralize post operative stomal edema and obstruction. Note: Vernier’s Calliper and Stainless steel scales were used to measure dimension.

### Exclusion criteria

All Brookeable ileum where excluded from this study.

### Steps of surgery

Pre-operatively the proposed site of Ileostomy in the “Triangle of Stomata” was marked with indelible ink. Laparotomy and ileostomy consented patients take up supine, under ET-GA (endotracheal general anaesthesia), parts painted, draped and abdomen entered by midline umbilicus skirting incision of adequate length.<sup>2</sup>


Exploration done. Primary lesions identified, condition of the bowel noted and Brookeability or un-Brookeability of the terminal ileum decided, based on the above mentioned Ray’s criteria. Primary lesion removed or bypassed, Hemostatsis achieved, peritoneal toilet done and 32F abdominal drains placed at suitable sites and secured by “Roman – Sandal” pattern of drain fixation.

Marked stoma site skin was pinched up with Allis’ forceps and neat disc of skin removed with cutting current of electrocautery. Subcutaneous fat removed.

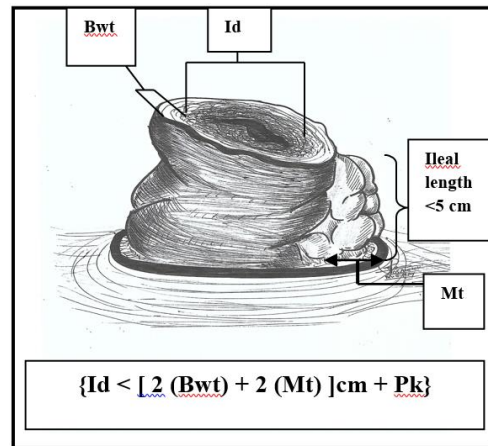
Anterior rectus sheath terphined and rectus abdominis muscle breached by cruciate incision using coagulation current of electrocautery. It was ensured that the terphined stoma site should snugly fit the two fingers of the operating surgeon. Too narrow an opening would cause “pinch-off” obstruction of the ileostomy by rectus muscle and too large would invite parastomal hernia.

Next using Babcock’s forceps the prepared end of ileum with intact mesentery was gently delivered out through the terphined opening of the abdominal wall, as long segment “Hanging-snout” end Ileostomy and this was anchored to the skin on the 04 corners of “Compass-point” using 02/0 – Vicryl suture on round body. Here care was taken to avoid sero-muscular bite which is notorious in causing fistulation of ileostomy, hence serosa bites were preferred. We strictly avoided taking any suture through mesentery fearing troublesome bleeding, hematoma formation and subsequent threat of ischemia of the ileostomy.

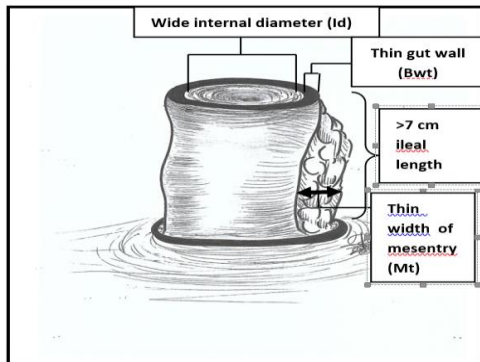
In all our 23 cases, we strictly resorted to “Bogotized” closure of abdomen, in view of edematous loaded bowel with doubtful bowel vascularity. A formal closure of abdomen in this setting would have invariably invited IAH3 (Intra-Abdominal Hypertension) leading to ACS (Abdominal Compartment Syndrome) – an ominous harbinger of the fatal outcome! On table, stoma bag were attached to the ileostomy and patient managed accordingly in the post-op period.<sup>3</sup>




**Figure 3: Construction of Brooke's everting end ileostomy in progress.**




**Figure 4: Un-Brookeable end ileum drawn out through the trephined opening on the abdominal wall.**



**Figure 1: Brookeable terminal ileum.**



**Figure 2: Ileal mucosa everting triangulization sutures on the end ileum.**



**Figure 5: Triangle of stomata on either side of abdomen is made up of spino-umbilical line as base of the triangle and mid-point of costal margin as the apex.**

In most cases, with the resolution of bowel edema over 03-05 post-op days, the patient was taken up for formal closure of abdomen, leaving ileostomy in situ. RBC were achieved uneventfully in 19 cases within 04 to 06 weeks' time.



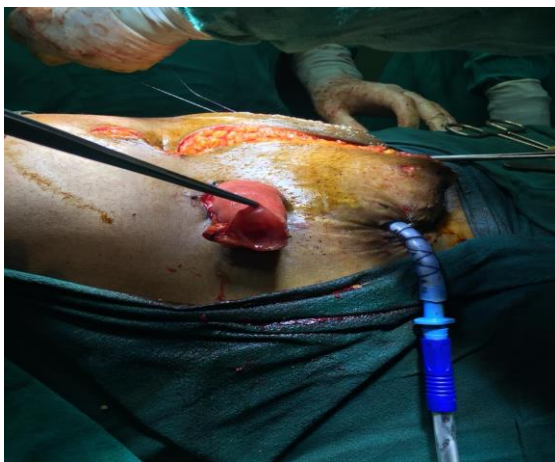## RESULTS

Out of 23 of our cases, 19 were males, aged between 25 to 40 and 4 were females between 40-45 years age.

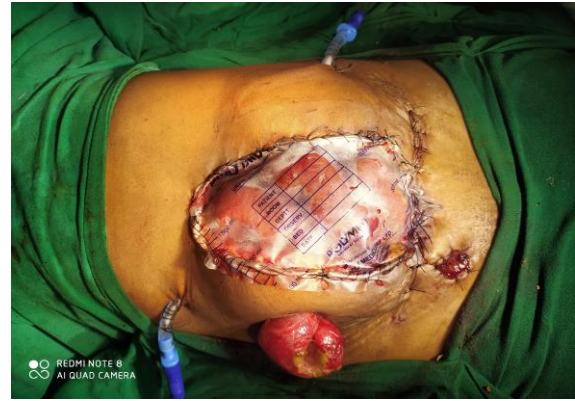In the beginning of our study we unknowingly made some basic mistakes! We were unaware of the problem that we might face if the “Hanging – snout” ileostomy is left out for long (more than 4 weeks) without undergoing RBC

In these cases the mouth of the “Hanging–snout” ileostomy suffered ileoserositis leading to ileal stenosis and SAIO.<sup>4</sup> This caused total cessation of oral feeds – a very serious issue in an already nutritionally crippled patient. All attempts to digitally dilate the stenosis with lubricated finger or hydrostatic balloon dilation with 22F Foley’s catheter bulb, failed to tackle the issue. Often the nature resolved the issue by creating a “Blow-out” EAF in the exteriorized ileum. This no doubt relieved the obstruction but the corrosive intestinal effluent caused extensive peri-stomal skin erosion resulting in stoma bag failure! A very depressing situation for the patient and a nightmare for the stoma care staff!

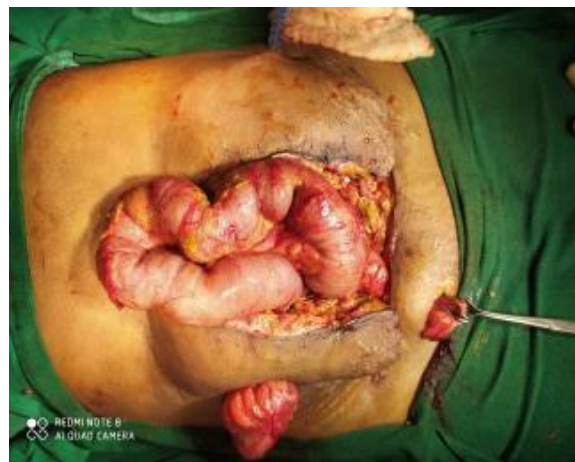An interesting observation we made in 03 of our cases where “Blow-out” EAF next to the peristomal skin did not undergo stenosis and closure, rather it remained patent, spewing gut content. In 02 of the cases the “Blow-out” EAF far removed from the skin edge strangely developed a “prolapsing lateral limb” that remained patent for long. Out of 16 cases, 10 of them underwent an uneventful RBC within 04 weeks. This was the best solution so far. The remaining 06 cases in whom RBC was anticipatedly delayed beyond 06 weeks for various reasons, we tried to neutralize the ileal stomal stenosis, (albeit with limited success) by adventurous methods such as interlocking suturing of stoma with 03/0 Vicryl and suturing a corrugated PVC tube.



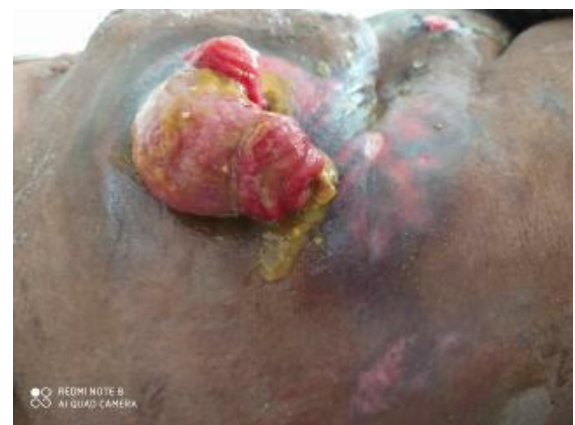**Figure 6: Hanging snout Ileostomy.**



**Figure 7: Bogotised closure of abdomen with Hanging snout ileostomy (Bogota closure of abdomen).**



**Figure 8: Long time obstructed, loaded, edematous and friable sick bowel.**



**Figure 9: Ileal serositis causing end ileal stenosis and subsequently “Blow-out” entero-atmospheric fistula (EAF).**

## DISCUSSION

The success or failure of an enterostomy in any segment of GIT, is totally governed by 03 facts: the gut juices, the gut bacteria and the surgical techniques.

A judiciously created enterostomy can be much needed blessing to a sick patient and a botched up one can be a never ending nightmare and at times can be fatal!

To create a good enterostomy one needs to have a “Birds-eye-view” of the peculiarities of the GIT (Gastro Intestinal Tract) to avoid unmitigable surgical disasters.

It is amazing to note that alternate segment of GIT are fixed and mobile. All those fixed segments are either retromediastinal (Esophagus) or retroperitoneal. (Duodenum, right and left colon and rectum). They all are devoid of serosa, instead have adventitia (loose connective tissue) They all have mesentery and can be mobilized out of the abdomen to create an enterostomy (e.g. Kocherization of duodenum, Mattox’s right and left manoeuvre for colon). Because of their fixity they all can be injured easily. Whereas all mobile segments are intraperitoneal and are encased in serosa. Because of their mobility they easily get away from harm’s away! The fixed segment perhaps acts like the “Sprinter’s starting blocks” to launch a fresh wave of peristalsis in the following mobile segment of the GIT.

From the mouth to anus GIT is a differentially, 04 layered, biochemically and microbially charged muscular tube. The mid portion of the GIT (Stomach, duodenum, and small intestine) is flooded with large volume of deadly corrosive gut juices—Hydro-chloric acid in stomach and alkaline juices like bile and pancreatic juices in the duodenum and succus entericus in the small gut. Any flushed enterostomy made in these segment of GIT will have high output of corrosive effluent with erosion and dissolution of peristomal skin. It will be associated with massive fluid electrolyte and nutritional depletion. This is a perfect recipe for a disaster! For this reason ileostomy and jejunostomy should be made raised above the skin surface and not flushed with it, so that corrosive effluent can be safely collected, away from the skin, in an attached receptacle. Whereas a flushed enterostomy elsewhere is totally harmless e.g. esophagostomy and colostomy.

The gut flora (enterobacteria) or gut bacteria such as *Lactobacillus*, *Escherichia coli*, *Enterobacter cloacae* and *fecalis* reside mostly in the small intestine and colon, and they form the part of microbiome or microbiota of the gut.<sup>5</sup> The masticated and juice marinated food gruel from the stomach are acted upon by the gut juices and flora to ferment and digest the complex food soup into simplified soup - “The Liquid feces”- which is rich in nutrients, minerals, vitamins, fibres, water, intestinal juices, a huge load of gut bacteria and gases. Infact the gut behaves like a “Long fermenting bowel”. The ileocaecal valve perhaps, acts like a “Traffic breaking mechanism” that holds this liquid feces in the terminal ileum long enough for the gut to absorb the nutrients, minerals, and fluids, and at the same time the deadly corrosive gut juices are neutralized before it is released into the caecum and right colon, where after absorption of

fluids, well formed ‘skin – friendly feces’ are expelled per rectally. This is the reason that feces passed per rectally or through flushed colostomy do not cause erosive burn of the peri-anal and peri-stomal skin respectively. But in severe diarrhea there is intestinal hurry, when the corrosive juices in the liquid feces do not get enough “standing time” in the small gut, to be neutralized and this causes severe peri-anal and pericostomy skin burn.

The intestinal gases are mostly the by-products of fermentative digestion of food in the gut (and a small volume is from aerophagy). Perhaps because of their large volume to weight ratio (as compared with solids and liquids) the gas distends the gut rapidly, there by triggering wave of peristalsis for propulsion of fecal waste out of GIT through the anus.<sup>6</sup> The gas too, bearing the signature smell of the gut content, escapes per rectally, audible or silently, as flatus or commonly called as fart. Total daily volume ranged from 476 to 1491 ml (median 705 ml) which is often due to variable quality and quantity of gut flora intestinal juices, type of food intake and status of digestion.<sup>7</sup> Breach in bowel continuity due to disease, trauma, or breakdown of anastomosis due to surgical misadventure, suddenly allows the intestinal gases to spew out with the liquid feces of the gut carrying the good, the bad, the ugly and the deadly bacteria into the organ spaces of peritoneum and tissue planes, triggering severe sepsis with fatal outcome. Inadvertently the escaping gas “Whistle-blows” the presence of the gut breach, seen as gas under diaphragm in X-ray chest film. One can say “What you eat is on your mind, what’s on your mind is on your face and what’s on your face, you wear on your body!”

Surgeons should be wary of a long obstructed, loaded, friable and an edematous “sick-bowel”. They often have compromised vascularity, low metabolism and very poor tolerance for any injury and insult. They easily suffer breakdown of any repair or anastomosis done on them, leading to sepsis and disaster! So paraphrasing an old saying we can say “Hell hath seen no furry like a gut scorned!”. The usual causes of bowel edema are local sepsis and obstruction causing third – spacing of fluid in the bowel walls, over hydration, desiccation, hypoxia due to bowel asphyxiation caused by IAH (Intra Abdominal Hypertension) and ACS (Abdominal Compartment Syndrome), surgical “Manhandling” during operative procedure, hypoproteinemia and Nitrous oxide (N<sub>2</sub>O – Anaesthetic gases). Other factors that cause sick-bowel are “FRIENDS” (F=foreign body, R=radiation, I=infection like tuberculosis, E=epithelised tract of entero cutaneous fistula /E.C.F., N=neoplastic disease, D=distal obstruction and S=surrounding sepsis).<sup>8,9</sup> It can be said that “With FRIENDS like these, you don’t need enemies!” It is wise to have these edematous “Sick-bowel” (so also all operated colon) treated gently, respectfully rested with exclusion by proximal fecal stream diversion by enterostomy. This will help them decompress rest and recover uneventfully.

Bowel injuries of the past in war or accident before the advent of laparotomy (1809), whether missed, unattended or neglected, had been unfailingly fatal!<sup>10</sup> Wounded Viking warriors were given strong onion soup and a while later, if the abdominal wound smelled of onion than that meant serious bowel injury and death was inevitable!<sup>11</sup> This was a crude yet a simple innovative technique of yore to diagnosis bowel injury – which were unfortunately fatal then!

The First successful laparotomy in pre-anaesthesia period was performed in 1809 by Ephraim McDowell in Danville, Kentucky – USA to remove an ovarian tumor.<sup>12</sup> On 13 July 1881, George Emory Goodfellow of Tombstone, Arizona, U.S.A., did the first successful laparotomy for gun shot wound abdomen, under chloroform anaesthesia.<sup>12</sup> But the management of breakdown of bowel repair or anastomosis dogged surgeons across the two World Wars, till the mid of twentieth century.

In 1879, Wilhelm Baum a German surgeon from Danzig, created the world's first ileostomy for bowel malignancy.<sup>13</sup> Karel Maydl of Czechoslovakia reported in 1883 a successful recovery of a double barrel ileostomy.<sup>14</sup> In 1889 Finney (U.S.A.) created a 'Flushed-loop ileostomy' and John Young Brown (U.S.A.) created a "catheter-sewn- flushed-ileostomy" at the end of midline wound.<sup>14</sup> Both the patients had a miserable end!

First "pinch-closed" long protruding ileostomy was created by Partseh in 1883 and Lawenstein in 1894, so that the corrosive liquid feces could drain into a collecting receptacle without damaging the surrounding skin. But the problem with this novel idea was pre-mature stenosis of end ileal stoma due to ileoserositis. This was variously managed unsuccessfully by digital dilatation, stretching or skin grafting. In early 1950s a serendipitous discovery was made at the Cleveland clinic USA by George Crile Jr. and Rupert Beach Turnbull Jr. when they neutralized the stomal obstruction by eversion of ileal mucosa onto the abdominal skin.<sup>15</sup> Around the same time in 1953 Bryan Nicholas Brooke of Birmingham, England, created and popularized the famous pouting Brooke's end ileostomy.<sup>16</sup> It once for all solved the problem of ileal stenosis which invited intestinal obstruction "blow-out" IAF, peri-stomal skin erosion and the resultant stomal bag failure! In all fairness, the mucosa everted end ileostomy should be called as "Crile-Turnbull-Brooke's Ileostomy" But what would you do in situations where an eversion of mucosa of the ileum to create a neat pouting Brooke's ileostomy is not only dangerous but outright impossible!

Over a period of 12 years we tried to study the management of 23 cases of "Un-Brookeable" end ileum. We used "Ray's Criteria" designed by the lead author of this study (details given under inclusion criteria) to separate out "Brookeable" end ileum from the "Un-Brookeable" ones. All our 23 un-brookeable ileum were

managed by long segment hanging snout end ileostomy and Bogotized closure of abdomen (i.e. Bogota bag closure of abdomen), to give rest to the "sick-bowel" and to preemptively neutralize the ill effect of IAH and ACS.

In the initial phase of our study, we learnt that a hanging –snout ileostomy beyond 04 to 06 weeks suffer end ileum ileoserositis causing stenosis, intestinal obstruction and often resolved by "Blow-out" EAF of exteriorized ileum. Various methods were attempted with limited success to counter this problem with digital and balloon dilatation, end ileal interlock suturing and suturing corrugated PVC tube to ileal stoma. The best remedy to prevent ileal stenosis is to undertake RBC within 04 weeks.

A chance suggestion by the lead author's wife (one of the co-author of this study), that on resolution of bowel edema within 03 to 05 days the "Bogotised" abdomen undergoes formal closure, that's when the edemaless Brookeable hanging snout ileostomy can undergo mucosa everting Brooke's ileostomy to neutralize ilealserositis and the resultant ileal stenosis (a point for future study).

Our method of managing "Un-Brookeable" ileum by long segment hanging snout end ileostomy has given us the confidence – a sort of parachute, to bail out a surgeon, from a difficult laparotomy in emergency hour, requiring "fecal stream diversion" by ileostomy. The best remedy to prevent ileal stenosis is to undertake RBC (Restoration of Bowel Continuity) within 04 weeks.<sup>16</sup>

### **Study limitation**

As single operating chief surgeon conducted the study, the number of patient who underwent Ileostomy were limited. It's the observation done by single surgeon during his lifetime experiences while serving Indian army and now in SGT Hospital

### **CONCLUSION**

Enterostomy created at different segment of GIT have different behavioural characteristic, which is dictated by the secretory and microbial dynamics of that segment. For this reason "Flushed esophagostomy and colostomy" are benign and well tolerated by the patient, where as a "Flushed- jejunostomy and ileostomy" is a devastating procedure to say the least. They are best tolerated by raised, pouting mucosa everting Brooke's jejunostomy and ileostomy.

In certain surgical situations, as in obese and belly fattened patients with edematous, friable and sick small gut with short mesentery, it is impossible and dangerous to create an ideal Brooke's enterostomy. In our experience they should be treated by hanging snout end enterostomy and Bogotised closure of abdomen. And to counter the dreadful ileal serositis of end ileum, causing end ileal stenosis, attempt should be made to convert the

“Hanging-snout” into a Brooke’s end enterostomy at the earliest or achieve RBC within 04 weeks of it creation.

*Funding: No funding sources*

*Conflict of interest: None declared*

*Ethical approval: The study was approved by the Institutional Ethics Committee*

## REFERENCES

1. Brooke BN. The management of an ileostomy, including its complications. *Lancet*. 1952;2:102–4.
2. Cheetham M, Schein M, Rogers PN, Leppäniemi A, Rosin D, Jonathan E. Efron Schein’s Common Sense Emergency Abdominal Surgery. Fourth edition. U.K: tfm Publishing Limited; 2016
3. Kirkpatrick AW, Roberts DJ, De Waele J, Jaeschke R, Malbrain MLNG, et al. Intra-abdominal hypertension and the abdominal compartment syndrome: updated consensus definitions and clinical practice guidelines from the World Society of the Abdominal Compartment Syndrome. *Intensive Care Medicine*. 2013;39(7):1190–206.
4. Shabbir J, Britton DC. Stoma complications: a literature overview. *Colorectal Dis*. 2010;12(10):958–64.
5. Guarner F, Malagelada J. "Gut flora in health and disease". *The Lancet*. 2003;361(9356):512–9.
6. Azpiroz F. Intestinal gas dynamics: mechanisms and clinical relevance. *Gut*. 2005;54(7):893-5.
7. Tomlin J, Lewis C, Read NW. Investigation of normal flatus production in healthy volunteers. *Gut*. 1991;32(6):665-9.
8. Matikainen M, Santavirta J, Hiltunen KM. Ileoanal anastomosis without covering ileostomy. *Dis Colon Rectum*. 1990;33(5):384-8.
9. Cameron, John L. *Current Surgical Therapy*. 8th ed. Philadelphia: Elsevier Mosby, 2004.
10. Ellis, H. The First Successful Elective Laparotomy. *Journal of Perioperative Practice*. 2015;25(10):207-8.
11. Westphalen, N. ‘Warfare, Ships and Medicine: Prehistoric Origins’, *Journal of Military and Veteran’s Health*. 2020;28(1):16-28.
12. Quebbeman, Frances Elizabeth. "Medicine In Territorial Arizona" . University of Arizona; 1996. Archived from the original on 10 December 2013. Retrieved 7 December 2013
13. Kaidar-Person O, Person B, Wexner SD. Complications of construction and closure of temporary loop ileostomy. *J Am Coll Surg*. 2005;201:759-73.
14. Doughty, Dorothy. History of Ostomy Surgery. *Journal of wound, ostomy, and continence nursing: official publication of The Wound, Ostomy and Continence Nurses Society / WOCN*. 2008;35:34-8.
15. Turnbull RB, Weakley FL. St Louis: Mosby; 1967. Atlas of intestinal stomas; pp. 32–9
16. Slaney G. Bryan nicholas brooke. *BMJ (Clinical research ed.)*. 1998;317(7171):1529.

**Cite this article as:** Ray MS, Malhi SS, Asopa J, Kaur H, Grewal MS, et al. Long segment “Hanging-snout” end ileostomy a safe “Surgical disaster mitigating” technique for an “Un-brookeable” end ileum: a study of 23 cases over 12 years. *Int Surg J* 2022;9:59-65.