

Original Research Article

Assessment of sentinel lymph node detection by radioisotope scan and methylene blue alone in operable oral cavity cancer to assess its accuracy for metastasis

Arpit Jain^{1*}, Surabhi Srivastava², Anuj Gupta³, Naresh Ledwani¹,
Shikha Tiwari¹, Seema Mutha⁴

¹Department of Surgical Oncology, ²Department of Pathology, ³Department of Medical Oncology, ⁴Department of Radiation Oncology, Bhagwan Mahaveer Cancer Hospital and Research Center, Jaipur, Rajasthan, India

Received: 21 November 2021

Revised: 22 December 2021

Accepted: 24 December 2021

*Correspondence:

Dr. Arpit Jain,

E-mail: draj211989@gmail.com

Copyright: © the author(s), publisher and licensee Medip Academy. This is an open-access article distributed under the terms of the Creative Commons Attribution Non-Commercial License, which permits unrestricted non-commercial use, distribution, and reproduction in any medium, provided the original work is properly cited.

ABSTRACT

Background: Squamous cell carcinoma (SCC) is the most common malignancy affecting the oral cavity. It typically metastasizes into the regional cervical lymph nodes before spreading to distant organs.

Methods: A prospective study on sentinel lymph node biopsy (SLNB) in early oral cancers using methylene blue dye and sentinel node localisation using pre-operative lymphoscintigraphy and intraoperative gamma probe in early oral cavity cancer.

Results: Present study had a male to female ratio of 1.9:1, with (65.5%) male and (34.5%) female patients. Present study had a side distribution of disease more on left side with 138 patients (62.7%) and ratio of left to right was approximately 1.7:1. In present study most predominating gross morphological pattern of growth was ulcerative (35%) followed by ulcero-infiltrative (25%). Buccal mucosa was the most common sub-site of origin of carcinoma in oral cavity, followed by tongue, with 83 (37.7%) and 64 (29.1%) patients. Identification rate of methylene blue dye was 91.7% (100 out of 109 patient). Identification rate of radionuclide tracer was 94.6% (105 out of 111 patient). In methylene blue dye group out of 103 metastatic sentinel lymph nodes, 9 metastatic sentinel lymph nodes were detected on IHC.

Conclusions: With the above results it can be concluded the SLNB study is liable in detection of actual positive node and can avoid unnecessary neck dissections in patients with SCC with negative sentinel lymph node, as having very low risk of occult lymphatic metastases in the remaining lymphatic drainage.

Keywords: Lymphatic metastases, SCC, Methylene blue dye, Sentinel lymph nodes

INTRODUCTION

Squamous cell carcinoma (SCC) is the most common malignancy affecting the oral cavity. It typically metastasizes into the regional cervical lymph nodes before spreading to distant organs. Early detection and diagnosis are vital and can lead to adequate treatment and a better prognosis. The effective management of patients

with oral cavity cancer requires accurate staging of the disease. Many studies have confirmed that presence of lymph node metastasis decreases the 5-year survival rates by approximately 50% in comparison to those without nodal metastases.^{1,2} Treatment for node positive disease is well standardized but considerable variations still exist in managing patients with clinically negative nodes in the neck. Almost 20% of patients clinically node negative in the neck is harbouring occult metastases which are not

detected by clinical or radiological examination.^{3,4} Identifying subclinical cervical metastases holds the key to manage these subsets of cases. Currently available imaging techniques such as ultrasonography, computed tomography, magnetic resonance imaging and positron emission tomography lack the sensitivity and specificity necessary to guide treatment decisions in these group of patients, this can lead to high chances of loco-regional and distant failure. As per studies in early oral cavity carcinoma the chances of cervical nodal metastasis are 20-30%, even then in all these cases neck dissection is performed.^{5,6} Management of neck has come a long way to radical neck dissection to modified neck dissections and to selective neck dissections. It has largely been possible due to our growing knowledge of anatomical distribution of lymph nodes as per particular sub-site of head neck cancer. This has led to significant morbidity remains even with the selective procedure, including adhesive capsulitis of the shoulder (which can occur even after only transient weakness of the trapezius muscle), lip movement asymmetry, and contour changes in the neck. This has been documented in multiple quality of life studies and functional assessments.⁷⁻¹⁰ In current study we are doing sentinel lymph node detection in clinically as well as radiologically benign nodal neck by methylene blue dye and radionuclide scanning alone.

Objective

Objectives so the study were to identify the sentinel lymph node by methylene blue dye and radio isotope scan in oral cavity SCC and to study the pattern of lymph node metastasis in neck.

METHODS

Study site

Department of surgical oncology, Bhagwan Mahaveer cancer hospital and research centre, Jaipur, Rajasthan

Study population

Total 220 patients of early oral cavity carcinoma with clinico-radiologically node negative (benign) neck

Study period

The study conducted from August 2016 to April 2018.

Study design

The study design was of prospective, randomized, cross-sectional, comparative study.

Ethical approval

The ethical approval was taken from institutional ethics committee.

Sample size

Sample size was calculated at 80% study power and alpha error is 0.05 assuming 77% sensitivity of methylene blue dye in identifying nodal metastasis and 100% sensitivity of radionuclide isotope as found in the study of a prospective study on SLNB in early oral cancers using methylene blue dye and sentinel node localisation using pre-operative lymphoscintigraphy and intraoperative gamma probe in early oral cavity cancer

Following above assumption 104 cases in each group were required as sample size with continuing correction which is further enhanced and rounded off to 120 cases in each group expecting 10% dropouts/attrition as final sample size for present study. As only 10 patients were lost after enrolment so total 220 was taken for study.

Statistical analysis

Data was entered in excel sheet to prepare master chart and was subjected for statistical analysis. P<0.05 was taken as significant.

Methodology used

All the eligible patients fulfilling the inclusion criteria were approached and their detailed clinical history, thorough clinical examination, chest X-ray and USG neck was done. Patient was divided randomly in two groups by computer generating numbers. One group was studied by radioisotope scan and another by 1% methylene blue dye. Informed consent was taken by every patient. For radionuclide study group technique of SLNB-The technique SLNB involved preoperative lymphoscintigraphy, intraoperative lymphatic mapping using hand held gamma probe (Gamma probe system SG-04 crystal probe-automatic-crystal wireless probe). Technique of SLNB detection by methylene blue-methylene blue dye (1%) (human safer) used to identify SLN. Consent taken and allergy sensitivity test was done for all patients of this arm. If no evidence of allergy, then 0.5 to 1 ml was injected into submucosa around periphery of primary tumor before excision. The stained lymph nodes were dissected out within 20-30 min.

RESULTS

The most common age group in present study was of the patients between 41-50 years (36.8%), with median age group for males and females was 45 years. Age group <40 years comprised 28.2% of patients and patient older than 50 years comprised 35% of population (Table 1).

Present study had a male to female ratio of 1.9:1, with (65.5%) male and (34.5%) female patients (Table 2).

Present study had a side distribution of disease more on left side with 138 patients (62.7%) and ratio of left to right was approximately 1.7:1 (Table 3).

In present study most predominating gross morphological pattern of growth was ulcerative (35%) followed by ulcero-infiltrative (25%). Least common morphological pattern of growth was prolifero-infiltrative (1.8%) (Figure 1).

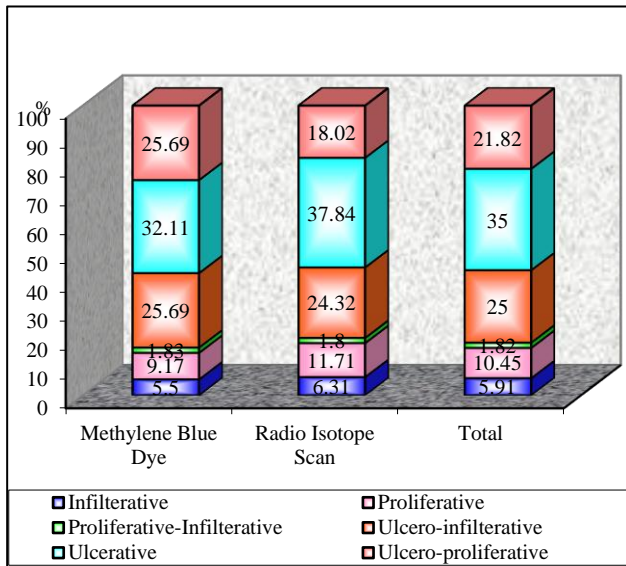


Figure 1: Distribution of morphological patterns of growth.

Buccal mucosa was the most common sub-site of origin of carcinoma in oral cavity, followed by tongue, with 83 (37.7%) and (64 (29.1%) patients, respectively. It was followed by carcinoma in lower alveolus (16.4%), retromolar trigone (10.9%), floor of mouth (5.0%), upper alveolus respectively. Patients having pathological positive nodes was highest at lower alveolus (61.1%) followed by tongue (50%) carcinoma. Buccal mucosa, though the most common sub-site of origin of carcinoma in oral cavity cancers, pathological positive lymph nodes were found only in 39.8% of these patients (Figure 2).

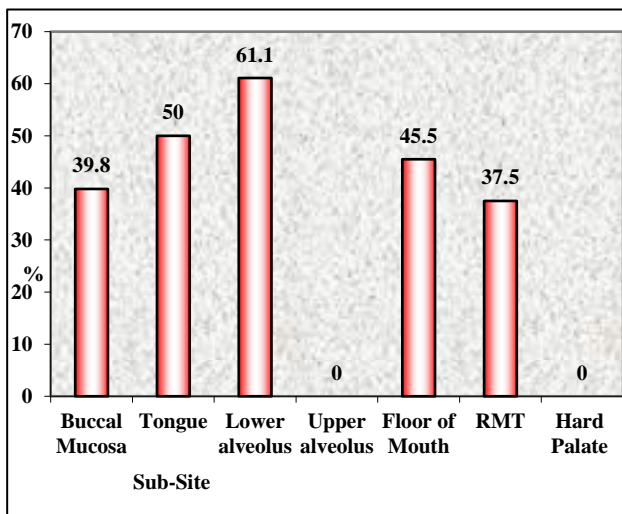


Figure 2: Distribution of subsites and rate of cervical node metastasis.

Patterned lymph node metastases were seen in 96.5% (168/174 who underwent MND) of the patients, with initial metastases to level IA/IB/IIA followed by level III and subsequent metastases to level IV. Lymph nodes at level IB were seen as the most common site of nodal metastases in oral cavity SCC. It was involved in 91 (41.2%) cases followed by level IIA which showed metastases in 76 cases (34.5%). Metastases to level IA was seen in 21 (9.5%) cases. Metastases to level IIB was seen only in 7 (3.2%) cases and none of having isolated metastases. Metastases to level III was seen in 22 (10%) cases and no isolated metastases found at level III. Metastases to level IV was seen in 6 (2.7%) cases, only one having patterned and five cases having aberrant/skip metastases without level III metastases (2.3%). None of patient was found having lymph node metastases at level V (Figure 3).

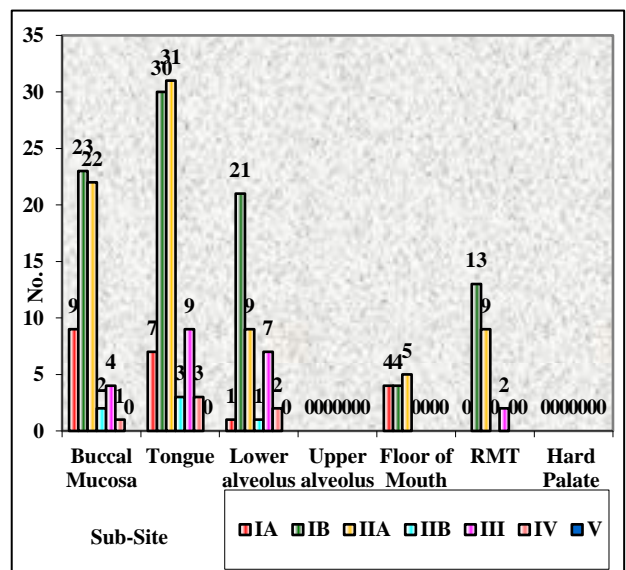


Figure 3: Pattern of cervical lymph node metastasis.

Level IB was the most common site of metastases, being involved in 23 (27.7%) patients of buccal mucosa cancer. All the patients had a systematic pattern of lymph node metastases except one. Single patient had skip metastases at level IV without level III metastases (Table 4).

Level IIA and IB was almost the most common site of metastases, being involved in 31 (48.4%) and 30 (46.9%) patients of tongue cancer. Three patients (4.7%) had nodal metastases to level IIB. All the patients had a systematic pattern of lymph node metastases except three patients who had level IV metastases. Those all three patients had aberrant metastases to level IV without involvement of level III (Table 5).

Level IIA involvement was seen in 5 patients (45.5%) with carcinoma at floor of mouth, and level IA and IB was involved in 4 patient (36.4%) in each. None of the patients with carcinoma floor of mouth had involvement of level III or beyond (Table 6).

In 109 patients of methylene blue dye group, total 2247 lymph nodes were resected. Out of 109, in 100 patients sentinel lymph nodes were identified (n=169 sentinel lymph nodes). So, the identification rate of getting sentinel lymph nodes 91.7% by blue dye. In 111 patients of radionuclide dye group, total 2313 lymph nodes were resected. Out of 111, in 105 patients sentinel lymph nodes were identified (n=179 sentinel lymph nodes). So the identification rate of getting sentinel lymph nodes 94.6% by radionuclide method. Among 169 identified sentinel lymph nodes by methylene blue dye, 103 were found to be positive (metastatic) on pathological examination (including IHC) so the identification rate of metastatic sentinel lymph nodes among total identified sentinel lymph nodes was 60.9% (positive predictive value). Among 179 identified sentinel lymph nodes by radionuclide, 87 were found to be positive on pathological examination (including IHC) so the identification rate of positive sentinel lymph nodes among total identified sentinel lymph nodes was 48.6% (positive predictive value). Total 113 lymph nodes were found positive pathologically among total dissected lymph nodes in elective neck dissection done in methylene blue group of patients. So, the overall detection rate of blue dye to find metastatic sentinel lymph nodes among actual pathological positive lymph nodes was 91.2% (103/113) (sensitivity). Total 91 lymph nodes were found positive pathologically among total dissected lymph nodes in radionuclide group of patients. So, the overall detection rate of radionuclide to find metastatic sentinel lymph nodes among actual pathological positive lymph nodes was 95.6% (87/91) (sensitivity). Detection rate of occult metastasis in blue dye was 91.2% and by radionuclide dye was 95.6% (Table 7).

In majority of patients time interval kept less than 20 minutes. Detection rate of getting metastatic positive SLN among total pathological positive lymph nodes of elective neck dissection was found decreased after 20 minutes of injection, although the results were not statistically significant but may because of dye crosses the actual positive node and show the false blue node seen at further level causing decreased detection rate of true positive SLN (Table 8).

Identification rate of methylene blue dye was 91.7% (100 out of 109 patient). In 6 patient methylene blue dye failed to identify the sentinel lymph node. Identification rate of radionuclide tracer was 94.6% (105 out of 111 patient). In 6 patient radionuclide tracers failed to identify the sentinel lymph node. In methylene blue dye group out of 103 metastatic sentinel lymph nodes, 9 metastatic sentinel lymph nodes were detected on IHC. If IHC was not used than only 94 lymph nodes would have been diagnosed as metastatic. So, the sensitivity and positive predictive value of methylene blue dye to detect metastatic disease decreases in sentinel lymph node decreases (83.2 and 55.6%) in the absence of IHC by about 8% and 5% respectively. And the difference for positive predictive value was statistically significant. In radionuclide group out of 87 metastatic sentinel lymph nodes, 7 metastatic sentinel lymph nodes were detected on IHC. If IHC was not used than only 80 lymph nodes would have been diagnosed as metastatic. So, the Sensitivity and Positive predictive value of radionuclide tracer to detect metastatic disease decreases in sentinel lymph node decreases (87.9 and 44.7%) in the absence of IHC by about 9% and 4% respectively and the difference for positive predictive value was statistically significant (Table 9 and 10).

Table 1: Age wise distribution of patient.

Age (years)	Groups				Total	
	Methylene blue dye		Radio isotope scan		N	%
	N	%	N	%		
≤30	8	7.34	14	12.61	22	10.00
31-40	20	18.35	20	18.02	40	18.18
41-50	40	36.70	41	36.94	81	36.82
51-60	26	23.85	23	20.72	49	22.27
61-70	13	11.93	8	7.21	21	9.55
>70	2	1.83	5	4.50	7	3.18
Total	109	100.00	111	100.00	220	100.00

Chi-square=4.291 with 5 degrees of freedom, p=0.587.

Table 2: Sex wise distribution of patient.

Sex	Group				Total	
	Methylene blue dye		Radio isotope scan		N	%
	N	%	N	%		
Male	70	64.22	74	66.67	144	65.45
Female	39	35.78	37	33.33	76	34.55
Total	109	100.00	111	100.00	220	100.00

Chi-square=0.057 with 1 degree of freedom, p=0.811.

Table 3: Distribution of side of disease.

Sides	Group				Total	
	Methylene blue dye		Radio isotope scan		N	%
	N	%	N	%		
Left	69	63.30	69	62.16	138	62.73
Right	40	36.70	42	37.84	82	37.27
Total	109	100.00	111	100.00	220	100.00

Chi-square=0.001 with 1 degree of freedom, p=0.972.

Table 4: Pattern of cervical lymph node metastasis (carcinoma buccal mucosa).

Level of LN	No. of patients with pathologically positive LN	Percentages (%)
IA	9	10.8
IB	23	27.7
IIA	22	26.5
IIB	2	2.4
III	4	4.8
IV	1	1.2
V	0	0

Table 5: Pattern of cervical lymph node metastasis (carcinoma tongue).

Level of LN	No. of patients with pathologically positive LN	Percentages (%)
IA	7	10.9
IB	30	46.9
IIA	31	48.4
IIB	3	4.7
III	9	14.1
IV	3	4.7
V	0	0

Table 6: Pattern of cervical lymph node metastasis (Carcinoma floor of mouth).

Level of LN	No. of patients with pathologically positive LN	Percentages (%)
IA	4	36.4
IB	4	36.4
IIA	5	45.5
IIB	0	0
III	0	0
IV	0	0
V	0	0

Table 7: Detection of occult metastasis.

Status of neck	Total no. of LN removed	Total no. of SLN identified	Total no. of SLN positive	Total no. of pathological positive LN missed	Total no. of SLN positive on IHC	Total no. of LN positive
MB	2247	169	103	10	9	113
RN	2313	179	87	4	7	91
Total	4560	348	190	14	16	204

Table 8: Distribution of patients with time duration of methylene blue dye injection and node retrieval.

Time duration (min)	No. of patients	No. of patients in SLNB identified	Total no. of LN removed	Total no. of SLNB identified	Total no. of positive SLNB	Total no. of positive LN
≤20	90	63	1853	143	87	93
>20	19	11	394	26	16	20
Total	109	74	2247	169	103	113

Table 9: Detection of sentinel lymph node and role of IHC.

Methods	No. of SLNB identified	Total no. of SLNB positive	No. of SLNB positive on IHC	No. of LN positive
MB	169	103	9	113
RN	177	87	7	91
Total	346	190	16	204

Chi-square=0.011 with 1 degree of freedom, p=0.917.

Table 10: Methylene blue dye.

Variables	Methylene blue dye (%)		P value
	Without IHC	With IHC	
Sensitivity	83.2	91.2	0.112
Specificity	96.5	96.9	0.493
PPV	55.6	60.9	0.378
NPV	99.1	99.5	0.136
False positive	3.51	3.09	0.493
False negative	16.81	8.85	0.112
Accuracy	95.82	96.61	0.184

DISCUSSION

This study was conducted in 220 patients with primary SCC of oral cavity. All patients underwent resection of primary carcinoma with neck dissection and reconstruction as required. Resections and neck dissections were done as per existing protocols, supported by the available literature. All patients were staged clinico-radiologically according to AJCC 7th edition. 174 patient underwent modified neck dissection with clearance of level I-V, while 46 patients underwent supra-omohyoid neck dissection.

Age and sex distribution

Male to female ratio in present study was 1.9:1, with 144 (65.5%) males and 76 (34.5%) females. The most common age group suffering from SCC of oral cavity in present study was between 41 to 50 years (81 patients, 36.8%). Age group from 30 to 60 years comprised about 77% of the population. Youngest patient in our study group was of 22 years of age and the oldest was of 78 years of age. The median age for both the males and females was 45 years. Mean age was slightly higher for females (45.5 years) compared to 47.3 years for males.

In a study by Jatin et al on, “The pattern of cervical lymph node metastases from squamous carcinoma of the oral cavity,” age range was from 17 to 95 years with a mean age of 60 years. The male population comprised 71% of the total population.¹¹

In a study by Woolgar et al on, “Histological distribution of cervical lymph node metastases from intraoral/oropharyngeal SCC” male population was 65% of the total with a mean age of 58 years for males compared to 63 years for females, which showed a statistically significant lower age for males.¹²

A study by Masahiro et al on, “Lymph node metastases in squamous cell carcinoma of the oral cavity correlation between histological features and prevalence of metastases”, mean age was 60 years with an age range from 31 to 83 years.¹³

In comparison to other study groups, our patients had a mean age 10 to 15 years younger, with slightly lower male to female ratio, although male population was slightly more in our study group. The reason may be early exposure to tobacco, which is more prevalent in male population but the prevalence of tobacco exposure in female population is also increasing.

Distribution of side of origin of carcinoma in oral cavity squamous cell carcinoma

Among the 220 cases of oral cavity squamous cell carcinoma, we found 138 cases (62.7%) were involving the left side of the oral cavity, 82 cases (37.3%) were involving the right side, and ratio of left to right was approximately 1.7:1.

Selvamani et al also found the same results in their study of “Prevalence of oral squamous cell carcinoma of tongue in and around Davangere, Karnataka, India: A retrospective study over 13 years”. They found left side to right side ratio 1.2:1.¹⁴

The reason can be because of more use of chewable form of tobacco and keeping them into left side of gingivobuccal sulcus causing more exposure and exposure for longer duration of mucosa on left side oral cavity.

Distribution of morphological pattern of growth

In our study among all the cases of oral cavity squamous cell carcinoma, most common morphological pattern of growth was ulcerative (35%) followed by ulcero-infiltrative (25%). Least common morphological pattern of growth was proliferative-infiltrative (1.8 %).

In the study of Phookan et al 58.90% of the patients were found to have ulcerative type of growth pattern followed by proliferative type (15.07%), ulcero-proliferative type (19.18%) and infiltrative type (6.85%).¹⁵

In another study of Mathur et al for “Correlation of clinical patterns of oral cavity squamous cell carcinoma with age, site, sex and habits” also found the most common clinical morphological pattern of growth was ulcerative (54 patients, 52.9%) followed by ulceration with infiltrative pattern then papillary with infiltration pattern.¹⁷

Distribution of subsite of origin of carcinoma in oral cavity squamous cell carcinoma

In present study population, most common sub-site of squamous cell carcinoma in oral cavity was buccal mucosa, accounting for 83 patients (37.7%) of the patients (involving tumours reaching GBS). It was followed by carcinoma of tongue (64 patients, 29.1%), lower alveolus (36 patients, 16.4%), retromolar trigone (24 patients, 10.9%), floor of mouth (11 patients, 5.0%), upper alveolus (2 patient, 0.9%), palate (0 patients) respectively. In a study by Jatin et al most common sub-site of origin of primary carcinoma in oral cavity was oral tongue (36%) followed by floor of mouth (33%) gums (21%) and retromolar trigone (5%) respectively.¹¹

In a study of “The prevalence of squamous cell carcinoma in different sites of oral cavity at our rural

health care centre in Loni, Maharashtra-a retrospective 10-year study” by Tandon et al found the buccal mucosa (31.4%) was the most common site of oral cavity cancers.¹⁷ In another study of Phookan et al “Clinico-pathological study of oral cancer-a review of 73 cases” also found the buccal mucosa (35.6%) was the most common site of oral cavity cancers.¹⁵

In a study done by Masahiro et al a study of 60 patients of oral cavity carcinoma, 23 (38.35%) patients had tongue carcinoma, followed by lower alveolus (15 patients), floor of mouth (12 patients) and upper alveolus (6 patients).¹³ Only one patient suffered from buccal mucosa carcinoma. In another study done by Woolgar et al on “The topography of cervical lymph node metastases revisited: the histological findings in 526 sides of neck dissection from 439 previously untreated patients”, out of 359 patients suffering from oral cavity cancer (107 patients), lower alveolus (47 patients) and retromolar trigone (44 patients). Only 31 (8.6%) patients suffered from buccal mucosa carcinoma.¹⁸

The above data is mostly from western world, where tongue and floor of mouth are the most common sub-sites of origin of primary carcinoma in oral cavity, whereas in Indian study done by Tandon et al, Phookan et al and in our study group, buccal mucosa was the most common sub-site of origin of carcinoma, probably due to higher incidence of chewable tobacco consumption and habit of keeping tobacco in lower gingivobuccal sulcus.^{15,17}

Rate of cervical lymph node metastases from oral cavity squamous cell carcinoma

In our study group, out of total of 220 patients suffering from squamous cell carcinoma of oral cavity 101 patients (45.9%) had cervical node metastases. None of our patients had crossing midline lesion or bilateral cervical node metastases or extra nodal spread.

In a study by Pitman et al “Effectiveness of selective neck dissection for management of the clinically negative neck” showed that in around 20% cases clinico-radiologically N₀ neck harbor metastasis.¹⁸

In a study by Kapoor et al “Lymph node metastasis: A bearing on prognosis in squamous cell carcinoma”, the incidence of occult metastasis in neck LNs in patients with oral malignant tumors ranges from 23.7% to 42% but the rate is found to be higher in tongue and floor of the mouth tumors.¹⁹

In a study done by Coughlin et al “Oral cavity squamous cell carcinoma and the clinically N₀ neck: the past, present, and future of SLNB” showed that 20 to 30% of patients harbor occult regional metastases, an important feature that correlates with worse outcomes.²⁰ In another study by Woolgar et al “Cervical lymph node metastasis in oral cancer: The importance of even microscopic

extracapsular spread” also showed range of occult metastasis upto 40% depending upon primary subsite.²¹

Most of the available literature supports a rate of cervical nodal metastases of approximately 30-40% from the early squamous cell carcinoma of the oral cavity, also supports our study.

Pattern of cervical lymph node metastases-subsite wise

In present study carcinoma of tongue and lower alveolus had particularly high tendency to show nodal metastases below level III. Most of the metastases were confined to level I and IIA with all the subsites of oral cavity.

Buccal mucosa

In present study group, out of 83 patients with carcinoma buccal mucosa 39.8% of the patients had nodal metastases. None of the patients had level V involvement. Single patient had involvement of level IV. Rest all the patients showed a systematic patterned lymph node metastases with initial involvement of level IB followed by IIA and then a spill over to level III.

In a study Pandey et al on, “Pattern of lymphatic spread from carcinoma of the buccal mucosa and its implication for less than radical surgery”, 36% of the patients suffering from buccal mucosa carcinoma showed cervical node metastases with only one patient having involvement of level IV. All the patients had a patterned metastases.²²

Tongue

The 50% Of the patients suffering from tongue carcinoma showed a cervical node metastases in our study group. Most common lymph nodal group was level IIA (31 patients) followed by level IB (30 patients). 11 patients had level IIA as the first echolen group. Level IV was involved in 3 out of 64 patients having nodal metastases, with all three had skip metastases. Isolated metastases to level III or level V was not seen.

In a study done by Susumu et al on, “Evaluation of histopathologic paramatres in predicting cervical lymph node metastasis of oral and oropharyngeal carcinoma”, 33% of the patients suffering from squamous cell carcinoma of oral tongue showed cervical nodal metastases.²³

In a study done by Dias et al on, “relevance of skip metastases for squamous cell carcinoma of the oral tongue and the floor of the mouth”, metastases to level IV were present in 6.5 % of the patients and metastases to level V was seen in 2% of the patients. Occult metastases was present in 24% of the patients. Skip metastases was seen in 2% of the patients.²⁴

Floor of mouth

45.5% of the patients, suffering from carcinoma floor of mouth in present study had cervical nodal metastases. Level IIA was the most common site of metastases, noted in 5 patients followed by level IA and IB (4 patients at each nodal station). None of the patients had metastases to level IIB, IV or level V. None of the patient had aberrant metastases.

Upper alveolus and hard palate

The number of patients having their primary at these sites was too low to comment upon level of nodal involvement. Although, only two case in our study group had primary at upper alveolus and none of patient had primary at hard palate. In out of two patients of upper alveolus primary, none of patient had any metastatic lymph node in the neck.

A study done by Ramamurthy et al by methylene blue dye and they found the identification rate was 90.6%.²⁵ A study done by Ikramet al by radionuclide and they found the identification rate was 90%.²⁶ In another study of Shivakumar et al also found the identification rate of sentinel lymph node around 95%.²⁷ Alkureishi et al also showed the identification rate was 93% in their study.²⁸

The result of above studies supports the results of present study in both arms.

Significance of time duration between methylene blue dye injection or radionuclide injection and lymph node retrieval

The blue dye passes through the lymphatics of neck very rapidly, so as the time gap increases between dye injection and lymph node removal, the chances of getting falsely positive sentinel lymph nodes along with actual sentinel lymph nodes are high or sometime only falsely positive sentinel lymph nodes identified only and actual sentinel lymph nodes are missed. In this study we tried to keep the time duration cut off as 20 minutes and, in all patients, dye was injected on table so that time interval can be reduced.

So, the detection rate of getting pathological positive lymph node among total pathological lymph nodes found on elective neck dissection are 93.5% in ≤ 20 minutes and 80% in > 20 minutes, so as the time passes more than 20 minutes, the detection rate decreased.

Limitations

As in India, oral cavity cancer is one of the common cancers, larger prospective trials are required to give answers of certain questions like survival benefit as results of SENT-3 trial yet to come for survival benefit.

CONCLUSION

With the above results it can be concluded the SLNB study is liable in detection of actual positive node and can avoid unnecessary neck dissections in patients with early-stage oral cavity SCC with negative sentinel lymph node, as having very low risk of occult lymphatic metastases in the remaining lymphatic drainage (5 to 6%). Further other larger prospective studies required to reach better conclusion.

Funding: No funding sources

Conflict of interest: None declared

Ethical approval: The study was approved by the Institutional Ethics Committee

REFERENCES

- Johnson JT, Barnes EL. The extracapsular spread of tumors in cervical node metastasis. Arch Otolaryngol. 1981;107:725-9.
- Snow GB, Annyas AA, Van Slooten EA, Bartelink H, Hart AA. Prognostic factors of neck node metastasis. Clin Otolaryngol. 1982;7:185-92.
- Pitman KT, Johnson JT, Myers EN. Effectiveness of selective neck dissection for management of the clinically negative neck. Arch Otolaryngology Head Neck Surg. 1997;123:917-22.
- Steiner W, Hommerich CP. Diagnosis and treatment of the N0 neck of carcinomas of the upper aerodigestive tract. Eur Arch Otorhinolaryngo. 1993;1250:450-6.
- Lea J, Bachar G. Metastases to level IIb in squamous cell carcinoma of oral cavity: a systematic review and meta-analysis. Head Neck. 2010;32:184-90.
- Fan S, Tang QL. A review of clinical and histological parameters associated with contralateral in neck metastases in oral squamous cell carcinoma. Int J Oral Sci. 2011;3:180-90.
- Chepeha DB, Taylor RJ. Functional assessment using Constant's Shoulder Scale after modiWed radical and selective neck dissection. Head Neck. 2002;24:432-6.
- Kuntz AL, Weymuller EA. Impact of neck dissection on quality of life. Laryngoscope. 1999;109:1334-8.
- Rogers SN. A Quality-of-life following neck dissections. Acta Otolaryngol. 2004;124:231-6.
- Van Wilgen, Dijkstra PU. Shoulder pain and disability in daily life, following supraomohyoid neck dissection: a pilot study. J Craniomaxillofac Surg. 2003;31:183-6.
- Jatin P, Frank C, Candela, Anil K. The patterns of cervical lymph node metastasis from squamous carcinoma of the oral cavity; Cancer. 1990;66:109-13.
- Woolger JA. Histological frequency and distribution of cervical lymph node metastases from intraoral or oropharyngeal squamous cell carcinomas. Bri J Oral Maxillofacial Surg. 1999;37:175-80.
- Masahiro U, Yokoo S. Lymph Node Metastasis In Squamous Cell Carcinoma Of The Oral Cavity: Correlation Between Histologic Features And The Prevalence Of Metastasis. HEAD & NECK. 1992;14:263-272.
- Selvamani M, Yamunadevi A. Prevalence of oral squamous cell carcinoma of tongue in and around Davangere, Karnataka, India: A retrospective study over 13 years: J Pharm Bioallied Sci. 2015;7:S491-S494.
- Phookan J, Das R. Clinico-Pathological Study of Oral Cancer- A Review of 73 Cases. J Dental Med Sci. 2017;16(4):152-8.
- Mathur PT, Dayal PK. Correlation of Clinical Patterns of Oral Squamous Cell Carcinoma with Age, Site, Sex and Habits. J Indian Academy Oral Med Radiol. 2011;23(2):81-5.
- Tandon P, Dadhich A. The prevalence of squamous cell carcinoma in different sites of oral cavity at our Rural Health Care Centre in Loni, Maharashtra-a retrospective 10-year study: Contemp Oncol (ponz). 2017;21(2):178-83.
- Pitman KT, Johnson JT. Effectiveness of selective neck dissection for management of the clinically negative neck. Arch Otolaryngol Head Neck Surg. 1997;123:917-22.
- Kapoor C, Vaidya S. Lymph node metastasis: A bearing on prognosis in squamous cell carcinoma. Indian j cacner. 2015;52(3):417-24.
- Coughlin A, Resto VA. Oral Cavity Squamous Cell Carcinoma and the Clinically N0 Neck: The Past, Present, and Future of Sentinel Lymph Node Biopsy: CurrOncol Rep. 2010;12(2):129-35.
- Woolgar JA, Rogers SA. Cervical lymph node metastasis in oral cancer: The importance of even microscopic extracapsular spread. Oral Oncol. 2003;39:130-7.
- Pandey M, Shukla M, Nithya CS. Pattern of lymphatic spread from carcinoma of the buccal mucosa and its implication for less than radical surgery. J Oral Maxillofac Surg. 2011;69(2):340-5.
- Susumu S, Suzuki I, Nakajima T, Kawasaki T. Evaluation of histopathologic paramaters in predicting cervical lymph node metastasis of oral and oropharyngeal carcinoma. Oral Surg Oral Med Oral Pathol. 1988;66:683-8.
- Dias FL, Lima RA. Relevance of skip metastases for squamous cell carcinoma of the oral tongue and the floor of the mouth. Otolaryngol Head Neck Surg. 2006;134(3):460-5.
- Ramamurthy R, Seenivasagam RK. A Prospective Study on Sentinel Lymph Node Biopsy in Early Oral Cancers Using Methylene Blue Dye Alone. Indian J Surg Oncol. 2014;5(3):178-83.
- Ikram M, Akhtar AS. Sentinel node localisation using pre-operative lymphoscintigraphy and intraoperative gamma probe in early oral cavity cancer. J Pak Med Assoc. 2013;63:8.
- Shivakumar K, Vipin G. Sentinel Lymph Node Biopsy in N0 Neck for Squamous Cell Carcinoma of

Oral Cavity: a Prospective Study. *Indian J Surgical Oncology.* 2016;7(4):375-9.

28. Alkureishi LW, Roos GL. Sentinel node biopsy in head and neck squamous cell cancer: 5-year follow-up of a European multicenter trial. *Ann Surg Oncol.* 2010;17:2459-64.

Cite this article as: Jain A, Srivastava S, Gupta A, Ledwani N, Tiwari S, Mutha S. Assessment of sentinel lymph node detection by radioisotope scan and methylene blue alone in operable oral cavity cancer to assess its accuracy for metastasis. *Int Surg J* 2022;9:149-58.