

## Case Report

# A rare case of jejunal adenocarcinoma with brain metastasis

M. Harish, N. Hariprasad\*, R. Kannan

Department of General Surgery, Madras Medical College and Rajiv Gandhi Government General Hospital, Chennai, Tamil Nadu, India

**Received:** 30 November 2021

**Revised:** 14 December 2021

**Accepted:** 15 December 2021

### \*Correspondence:

Dr. N. Hariprasad,

E-mail: harive3107@gmail.com

**Copyright:** © the author(s), publisher and licensee Medip Academy. This is an open-access article distributed under the terms of the Creative Commons Attribution Non-Commercial License, which permits unrestricted non-commercial use, distribution, and reproduction in any medium, provided the original work is properly cited.

### ABSTRACT

Small bowel malignancies are rare entity, with adenocarcinoma being one of common type along with neuroendocrine tumours. Associated with Crohns, celiac disease, FAP and HNPCC. Jejunal adenocarcinoma produce vague symptoms, accounting for late presentation leading to difficult and delayed diagnosis in favour of poor prognosis. Diagnosis is established by CECT abdomen and CEA levels. Ro resection with regional lymphadenectomy and jejunojejunal anastomosis is preferred followed by adjuvant FOLFOX chemotherapy. Here we presenting a 68 years old male, anaemic with vague abdominal pain for 3 months, CECT showed malignant wall thickening involving 10 cm of proximal jejunal loop with no enlarged lymph nodes and CEA was elevated. Proceeded with laparotomy, an irregular hard mass of 10×10 cm involving 20 cm of jejunum with transverse colon infiltration with multiple mesenteric nodes found, composite resection with jejunojejunostomy and colocolic anastomosis done. Histopathology showed poorly differentiated jejunal adenocarcinoma with colonic infiltration with reactive nodes and post operatively on day 7, patient developed seizures and weakness of left upper and lower limbs, MRI brain showed solitary metastasis 2×2 cm in right frontal region and PET CT showed brain metastasis and multiple intraabdominal lymph node, lung and prostate metastasis, planned SBRT for brain metastasis and palliative chemotherapy. Lymph node, liver and peritoneum are common site of metastasis for small bowel adenocarcinoma, very rarely brain metastasis can occur in short time and to be considered if neurological symptoms occur pre and postoperatively.

**Keywords:** Brain metastasis, Small bowel, Jejunal adenocarcinoma, Metastatic brain tumor

### INTRODUCTION

Small bowel adenocarcinoma is a rare tumour, accounting for <2% of all gastrointestinal tumours. Its annual incidence rate is 1.2-6.5/1 million people.<sup>2</sup> peak incidence is in seventh decade of life with slight male predominance. It occurs on the duodenum in 57% of cases, jejunum in 29%, and the ileum in 10%.<sup>2</sup> Inflammatory bowel diseases, such as Crohn's disease, Peutz Jegher syndrome and polyposis, such as familial adenomatous polyposis are risk factors.<sup>3</sup> We report a very rare case of brain metastasis from poorly differentiated jejunal adenocarcinoma.

### CASE REPORT

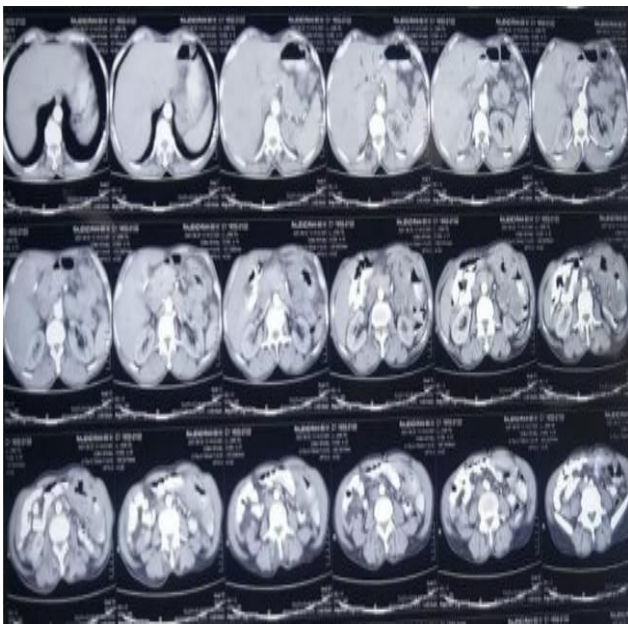
A 68 years old male presented with vague abdominal pain for 3 months, mainly over the umbilical region with no history of vomiting, constipation, loss of weight or loss of appetite. No history of yellowish discoloration of urine, melena, cough, breathlessness, giddiness or easy fatigability. Known smoker and alcoholic. No known comorbidities. no history of any previous surgery.

On Examination, patient conscious, oriented, afebrile, hydration adequate, pallor present. Vitals within normal limits. CVS and RS examination found normal. Per abdomen flat, umbilicus midline, no visible mass and on

palpation soft, no tenderness or guarding, no mass palpable, no organomegaly, per rectal examination was normal.

Complete hemogram showed haemoglobin-6 gm. Coagulation profile, liver, renal. Function tests and serum. Electrolytes were normal

CECT abdomen (IV and oral contrast) showed circumferential, irregular wall thickening involving proximal jejunal loops for a length of 12 cm and maximum thickness 2 cm with normal contrast flow and no lymphadenopathy suggesting malignant wall thickening involving proximal jejunum.



**Figure 1: CECT abdomen of malignant jejunal wall thickening.**

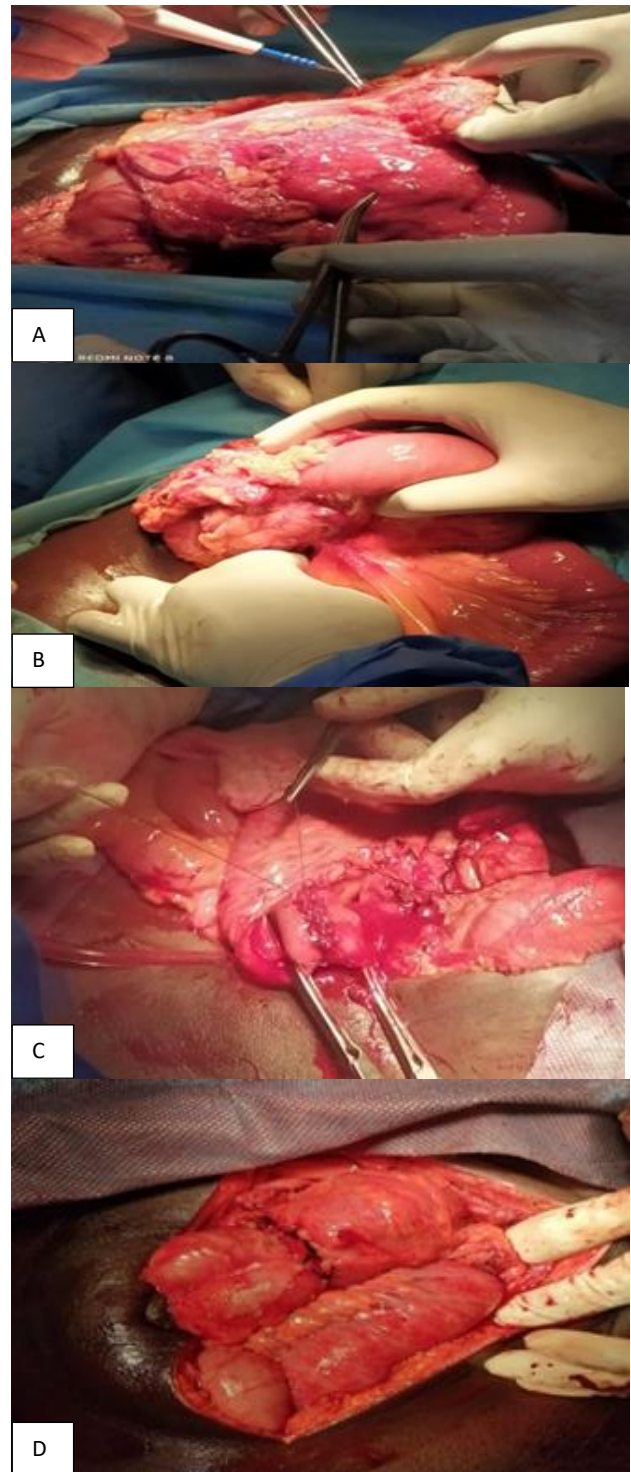
UGI scopy normal and CEA was elevated (42.5 ng/ml). Planned for laparotomy and proceed.

Intraoperatively, an irregular hard mass of 10×10 cm size involving proximal jejunum for a length of 20 cm at about 15 cm from DJ flexure, infiltrating a part of transverse colon for a length of 5 cm found with mesenteric nodes. Composite resection of involved jejunum and transverse colon done, sent for histopathological examination and jejunojejunal and colocolic anastomosis done.

Histopathology report showed infiltrating poorly differentiated adenocarcinoma of jejunum (pT4N0Mx) grade 3, with reactive hyperplasia of nodes and tumour infiltration involving the serosa and muscularis mucosa of transverse colon.

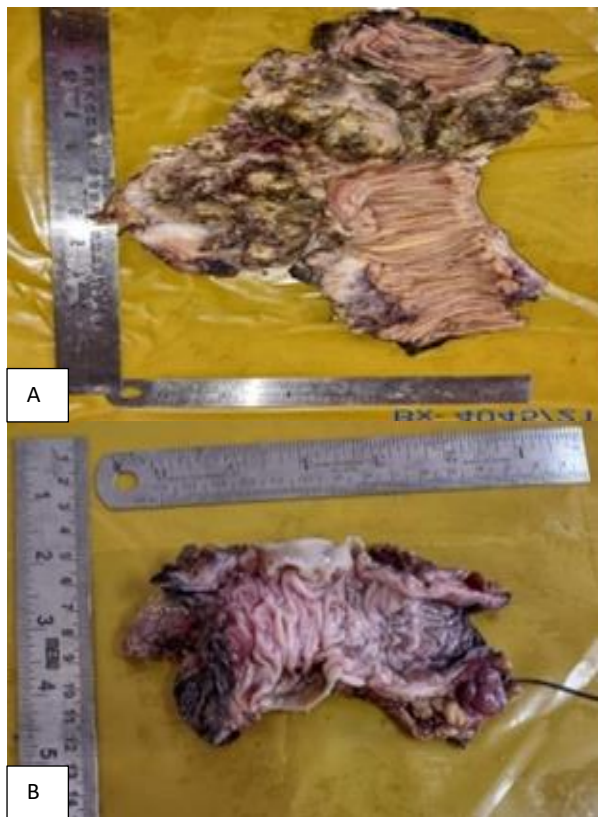
Planned for adjuvant chemotherapy with FOLFOX regimen.

On post operative day 7, patient developed seizures and left sided upper and lower limb weakness, CT brain shows 2×2 cm hypodense lesion in right frontal region and MRI brain shows well defined T2 hyperintense lesion with perilesional edema in cortical and subcortical region of right high frontal lobe in parasagittal location-likely solitary metastasis.

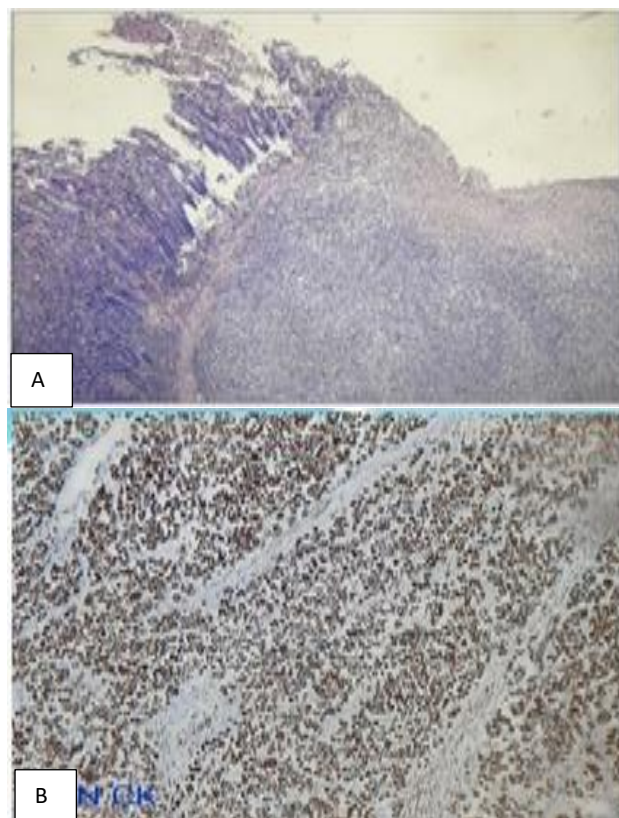


**Figure 2 (A-D): Intra operative picture of jejunal growth with transverse colon infiltration, jejuno-jejunal and colo-colic anastomosis respectively.**

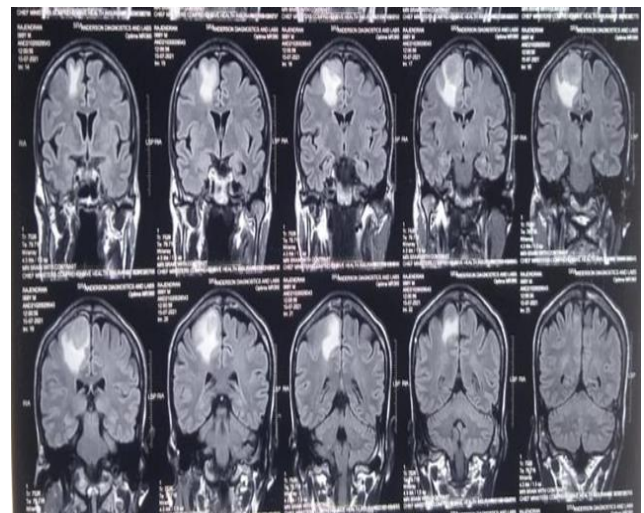




**Figure 3 (A and B): Gross specimen of resected jejunum and transverse colon.**



**Figure 4 (A and B): Histology of jejunal adenocarcinoma with pan CK +ve.**



**Figure 5: MRI brain images of brain metastasis.**

PET CT shows metabolically active hetero-genously enhancing lesion in para-sagittal aspect of right high parietal lobe with mild perilesional edema likely brain metastasis and multiple lymph nodal metastasis planned stereotactic body radio therapy and adjuvant chemotherapy.

## DISCUSSION

Adenocarcinomas constitute approximately 40% of the malignant tumors of the small bowel. The median age at diagnosis is in the sixth decade of life, and most series show a slight male predominance. Most of these tumors are located in the duodenum and proximal jejunum. Those arising in association with Crohn disease tend to occur at a somewhat younger age, and more than 70% arise in the ileum.

Small bowel adenocarcinoma may have important gene mutations (APC,  $\beta$ -catenin, EGFR, VEGF-A, KRAS, HER2, TP53). The most common familial causes include FAP, Lynch syndrome, and Peutz Jeghers syndrome.<sup>3</sup> Tumors of the duodenum tend to manifest somewhat earlier than those in the jejunum and ileum because of the earlier presentation of symptoms, which are usually jaundice and chronic bleeding. Adenocarcinomas of the jejunum and ileum usually produce more nonspecific symptoms that include vague abdominal pain and weight loss. Intestinal obstruction and chronic bleeding may also occur. Perforation is uncommon. As with adenocarcinomas in other organs, survival of patients with small bowel adenocarcinomas is related to the stage of disease at the time of diagnosis. Unfortunately, diagnosis is often delayed, and the disease is advanced at the time of surgery secondary to a variety of factors (e.g., vagueness of symptoms, absence of physical findings, lack of clinical suspicion because of the rarity of these lesions).<sup>1</sup> A variety of radiologic and endoscopic techniques such as CT of the abdomen and pelvis with enteroclysis, video capsule endoscopy, and double

balloon enteroscopy (for biopsy and diagnosis) may be very useful in establishing the diagnosis prior to surgery.

Treatment of small bowel adenocarcinoma is determined by location and stage. An R0 resection of the primary tumor with locoregional lymph node resection is the only curative treatment. Neoadjuvant chemotherapy is appropriate to consider if there is tumor invasion into adjacent structures. Patients are then reevaluated for surgery after 2 to 3 months of treatment. Duodenal resection can be performed for a noninfiltrating tumor if it is located in the first, third, or fourth portion of the duodenum, but this is not recommended if an expected R0 resection (no microscopic tumor at margin) is not possible. Residual microscopic tumor (R1 status) or grossly visible tumor after resection (R2 status) are associated with poor prognosis. Resectable adenocarcinomas in the second portion of the duodenum are treated with pancreaticoduodenectomy. In addition, regional lymphadenectomy of the peri-duodenal, peripancreatic, and hepatic lymph nodes as well as involved vascular structures is necessary. Jejunal and ileal adenocarcinomas require surgical resection with regional lymphadenectomy and jejuno-jejunal or ileoileal anastomosis. If the terminal ileum is involved, an ileocectomy with right hemicolectomy should be performed with ligation of the ileocolic artery and subsequent regional lymphadenectomy. There is currently no standard adjuvant protocol for small bowel adenocarcinoma.<sup>1</sup>

Despite this, most guidelines suggest that patients with poorly differentiated cancers or those who had incomplete lymph node resections (<10 nodes identified) should at least be considered for adjuvant chemotherapy. Adjuvant regimens are often dictated by location, although studies have suggested that fluoropyrimidine and oxaliplatin may increase overall survival in patients with advanced disease. A prospective international phase 3 trial (BALLAD study) comparing observation versus adjuvant chemotherapy in patients with an R0 resection is currently accruing subjects. This trial proposes that adjuvant chemotherapy will result in an improvement in disease-free survival and overall survival compared with observation alone after potentially curative surgery for patients with stage I, II, and III small bowel adenocarcinoma-adenocarcinoma.<sup>1</sup>

In patients with metastatic disease, studies have determined that using FOLFOX (oxaliplatin, 5-FU, and leucovorin) and FOLFIRI (irinotecan, 5-FU, and leucovorin) as first-line therapy significantly improves the performance status and progression-free survival. Unresectable metastatic disease may require surgical intervention for uncontrolled bleeding, bowel obstruction, or perforation. The prognosis of small bowel adenocarcinoma is poor, probably because of the delayed presentation and presence of advanced disease at diagnosis. Five-year survival rates are typically in the 14% to 33% range, although duodenal adenocarcinoma

has a 5-year survival rate of 50%, probably because of the earlier symptom presentation and diagnosis. Lymph node invasion is the main prognostic factor for local small bowel adenocarcinoma; moreover, the number of lymph nodes assessed and the number of positive lymph nodes are of prognostic value. In stage III patients, having more than three positive lymph nodes was associated with a worse 5-year disease-free survival rate than having one or two positive lymph nodes (37% vs 57%, respectively). Multivariate analysis identified advanced age, advanced stage, ileal location, recovery of fewer than 10 lymph nodes, and number of positive nodes as significant predictors of poor overall survival. Notably, any attempts at curative resection should always include an extensive regional lymphadenectomy.<sup>1,4</sup> The most common organs of SBA metastases are the abdominal lymph node, liver, and peritoneum; there have been almost no reports on brain metastases of SBA.<sup>6,7,9</sup> Dabaja et al reported 1 case of brain metastasis out of 217 SBA cases, but details of the clinical course of the case were unclear.<sup>6</sup> Salvati et al reported 10 cases of cerebral metastases from small intestine carcinoma, though no information about the clinical features of small intestine carcinoma was reported.<sup>10</sup>

Very rarely brain metastasis can occur in short time and to be considered if neurological symptoms occur pre and postoperatively. whole-brain radiotherapy (WBRT) has been the standard treatment of brain metastases (BMs), stereotactic radiosurgery SRS is increasingly preferred to avoid cognitive dysfunction; salvage stereotactic radiosurgery (SRS) is noninferior to WBRT and can be established as a standard therapy for patients with four or fewer BMs.<sup>8</sup>

## CONCLUSION

Hereby, we presented a rare case of small bowel adenocarcinoma with brain metastasis which shows very rapid progression. The occurrence of brain metastasis in small bowel adenocarcinoma is very rarely reported. Prognosis being poor, early intervention is of utmost importance.

*Funding: No funding sources*

*Conflict of interest: None declared*

*Ethical approval: Not required*

## REFERENCES

1. Townsend C, Beauchamp RD, Evers BM, Mattox K. Sabiston textbook of surgery, first South Asian edition, chapter 49, Elsevier. 2016;1276-2.
2. Halfdanarson TR, McWilliams RR, Donohue JH, Quevedo JF. A single-institution experience with 491 cases of small bowel adenocarcinoma. *Am J Surg.* 2010;199:797-803
3. Schottenfeld D, Beebe-Dimmer JL, Vignieu FD. The epidemiology and pathogenesis of neoplasia in the small intestine. *Ann Epidemiol.* 2009;19:58-69.

4. Apriaco T, zaanan A, Svreck M. Small bowel adenocarcinoma: Epidemiology, risk factors, diagnosis and treatment. *Dig Lkver Dis.* 2014;46:97-104.
5. Bilimoria KY, Bentrem DJ, Wayne JD, Ko CY, Bennett CL, Talamonti MS. Small bowel cancer in the United States: Changes in epidemiology, treatment, and survival over the last 20 years. *Ann Surg.* 2009;249:63-71.
6. Dabaja BS, Suki D, Pro B, Bonnen M, Ajani J. Adenocarcinoma of the small bowel: Presentation, prognostic factors, and outcome of 217 patients. *Cancer.* 2004;101:518-26.
7. Halfdanarson TR, McWilliams RR, Donohue JH, Quevedo JF. A single-institution experience with 491 cases of small bowel adenocarcinoma. *Am J Surg.* 2010;199:797-803.
8. Kayama T, Sato S, Sakurada K, Mizusawa J, Nishikawa R, Narita Y et al. Effects of surgery with salvage stereotactic radiosurgery versus surgery with whole-brain radiation therapy in patients with one to four brain metastases (JCOG0504): A phase III, noninferiority, randomized controlled trial. *J Clin Oncol.* 2018;36:JCO2018786186.
9. Khrolenko DE, Belaia KA. On metastases to the brain by cancer originating in the small intestine. *Zh Nevropatol Psikhiatr Im SS Korsakova.* 1967;67.
10. Salvati M, Cervoni L, Paolini S, Delfini R. Solitary cerebral metastases from intestinal carcinoma. *Acta Neurochir (Wien).* 1995;133:181-3.

**Cite this article as:** Harish M, Hariprasad N, Kannan R. A rare case of jejunal adenocarcinoma with brain metastasis. *Int Surg J* 2022;9:209-13.