

Original Research Article

Blunt abdominal trauma: initial resuscitation followed by clinical and focused abdominal sonography assessment important diagnostic tools of organ injury due to restricted use of CT-scan in a tertiary care in India

S. K. Sekendar Ali*, Narendra Nath Mukhopadhyay,
Jyotirmoy Bhattacharya, Madhusudan Chattopadhyay

Department of General Surgery, Burdwan Medical College and Hospital, Bardhaman, West Bengal, India

Received: 14 November 2021

Revised: 06 December 2021

Accepted: 09 December 2021

***Correspondence:**

Dr. S. K. Sekendar Ali,

E-mail: smeokbein@gmail.com

Copyright: © the author(s), publisher and licensee Medip Academy. This is an open-access article distributed under the terms of the Creative Commons Attribution Non-Commercial License, which permits unrestricted non-commercial use, distribution, and reproduction in any medium, provided the original work is properly cited.

ABSTRACT

Background: Blunt abdominal trauma (BAT) is one of the common causes of admission in surgical ward in any hospital. It requires high level of suspicion, urgent evaluation and timely management to decrease morbidity and mortality. Objective was to evaluate the role of clinical and ultrasound assessment in early diagnosis of intra-abdominal injury following blunt abdominal trauma and follow up in patients with intraabdominal injury for detecting complications.

Methods: 130 patients who presented to the emergency room were evaluated by clinical and focused abdominal sonography for trauma (FAST) and follow-up sonography was done after 6-12 hours upto 72 hours.

Results: In our study, road traffic accidents (RTA) were the most common cause of blunt abdominal trauma (70.76%) with 75% patients being were males. X-ray erect abdomen and ultrasound of the abdomen were the most sensitive investigation for hollow viscous injury and solid organ injuries, respectively, with bowel (38.33%) and liver injury (26.67%) being the most common organ involved in this study. This study found sensitivity (93.7%) and specificity (98.5%) of focused abdominal ultrasonography (FAST).

Conclusions: Initial resuscitation followed by clinical and ultrasonography assessment is considered the best modality in initial evaluation of blunt abdominal trauma patients as it is noninvasive, readily available, and requires minimal preparation time and also due to restricted use of modern amenities such as CT-scan in tertiary care in India.

Keywords: Blunt abdominal trauma, FAST assessment, Road traffic accident, Ultrasound by general surgeon

INTRODUCTION

Trauma is a global pandemic that kills more than 5 million people every year and accounts for 9% of the world's deaths, which is nearly 1.7 times the number of fatalities that result from HIV/AIDS, tuberculosis and malaria combined.¹ 90% of the global trauma mortality occur in low and middle-income countries. India's 30-day trauma related mortality rate is twice that of high-income countries and the in-hospital mortality trend hasn't shown any improvement over the last decade despite improvements in imaging and medical equipment.² Abdomen is the third most injured region of the body and

is affected in 7-10% of trauma victims, and 85% of abdominal trauma is blunt in nature.³ Blunt abdominal trauma (BAT) can be isolated or can be associated with other injuries. BAT can be missed if not suspected and looked for, significantly increasing the morbidity and mortality of trauma victims.³ Clinical evaluation alone is usually inadequate as there may be associated alteration of mental status due to shock or head injury; or other obvious injuries may engage the attention of the examining doctor. The commoner causes of BAT include road traffic accidents, falls and assaults.³ Though blunt force to the abdomen can injure any internal organ, liver and spleen are injured the most.⁴

Blunt abdominal trauma (BAT) is very common, and the prevalence of intra-abdominal injury following it has been reported to be as high as 12-15%. The mechanisms resulting in BAT were motor vehicle collision (73%), motorcycle collision (7%), auto-pedestrian collision (6%), and fall (6%).⁵ Rapid diagnosis of abdominal injury is an important step in the treatment process to prevent morbidity or mortality in BAT cases. Rapid determination of cases in need of emergency laparotomy is crucial for life saving, especially for those with unstable hemodynamics, the avoidance of unnecessary surgeries with its invasiveness and complications should be considered.⁶

Ultrasonography (US) is the first imaging method for screening patients with blunt abdominal trauma. It can demonstrate variety of post traumatic abdominal organ pathologies including hematomas, contusions, lacerations, and hemoperitoneum.⁶

Clinical examination and focused abdominal ultrasonography comprise the standard initial abdominal evaluation in post trauma patients. Clinical observation following BAT is a common procedure in all hospitals; however, the required period for observation remains controversial, some suggested that injuries among hemodynamically stable patients.⁷

This study aimed to assess the role of clinical examination and focused sonography in early diagnosis of intra-abdominal injuries following blunt abdominal trauma and follow up in patients with intraabdominal injury for early diagnosis of complications.

METHODS

All cases of Blunt abdominal trauma who were managed at a tertiary care, Burdwan medical and hospital from March 2020 to August 2021 were included in this Observational study. Hospital records were reviewed, and data was collected retrospectively which included demographic information like age and gender; mode of injury; diagnostic modalities and their findings; organs injured; therapeutic options adopted, and the outcomes recorded. Documents revealed that all victims were initially managed in the ER and surgical ward of the hospital as per ATLS protocol with i.v. resuscitation/ blood transfusion, urgent haematocrit, coagulation profile, blood grouping and cross-matching and other laboratory investigations. Tetanus prophylaxis and appropriate antibiotics were administered. This study approved by institutional ethical committee of Burdwan medical college.

Inclusion criteria

All patients presenting with history of blunt abdominal trauma to casualty department of our hospital and admitted in surgery or trauma care wards.

Exclusion criteria

Patients not willing to participate in study.

History and clinical assessment

Proper history as like time, place of incidence and mode of injury taken from patients party or attendance followed by clinically asses vital parameters like pulse, BP, respiration pattern, urine passed or not, pallor, GCS score, associated injury and carefully examine abdomen like pain, tenderness, distension of the patients. Simultaneously resuscitated all patients. After resuscitation, send for sonography (FAST) assessment to department of radiology.

Patient preparation: No preparation was done, and the patient was sent directly from the ER to the radiodiagnosis department after proper resuscitation.

Ultrasound scanning: All examinations including the follow up studies were conducted by the first author and radiologist (first author- surgeon cum sonologist who had 5 year experience in ultrasonography) using ultrasound machine with a 3.5 MHz curved array transducer.

Scanning technique: The patients were placed supine. Focused abdominal sonography for trauma (FAST) was performed, which takes no more than 5 minutes, the following four standard views should be obtained:

(1) Epigastric region transverse views to assess the left lobe of the liver. (2) Right hypochondrium longitudinal views to assess the right lobe of the liver, the right kidney, and the Morison pouch. (3) Left hypochondrial longitudinal views to assess the left kidney, the spleen, and the lienorenal space. (4) Suprapubic transverse and longitudinal views to assess the urinary bladder and Douglas pouch.

In addition to these four views, right and left longitudinal views of the lower thoracic cage are acquired to rule out pleural effusion.

Follow up: Ultrasonography was performed after 6-12 hours upto 72 hours except 45 cases who had severe intra-abdominal hemorrhage and entered the operation room urgently after FAST examination.

Contrast enhanced computed tomography (CECT) of few cases was done in FAST positive cases except those who were hemodynamically unstable or sent directly to the operation room. Ultrasonography findings were correlated with patient's clinical and operative data.

Study subject patients records was entered in study formula. Finally all data was entered in Microsoft excel 2017 and statistically analysed by calculating mean, median, average and percentage.

RESULTS

Age distribution

After applying inclusion and exclusion criteria, 130 patients were considered for present study. Most common age group in our study was of 21-30 years (30.47%), followed by age group 31-40 years (24.22%). Calculated mean age of present study was 32.18±6.53 years.

Table 1: Age distribution.

Age in years	Number of cases	Percentage
0-20	24	18.4
21-30	40	30.7
31-40	31	23.8
41-50	19	14.6
51-60	10	7.6
61-70	6	4.6
Total	128	
Mean±SD	32.2±6.5	

Gender distribution

In our study male patients were 97 (75%), while female patients were 33 (25%).

Mode of injury

Most common cause of blunt abdominal trauma in present study was road traffic accidents (70.76%). Assault (19.23%), fall (8.46%) and other causes (1.53%) were also noted.

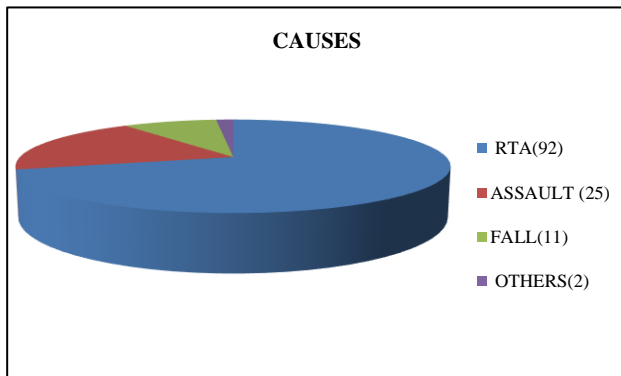


Figure 1: Mode of injury.

Symptoms and sign

The Table 2 shows the incidence of various symptoms and signs with which the 130 patients studied.

Hemodynamic status

The patient who were taken as unstable condition were pulse rate >100/minute, BP<90 mm of Hg. 45 patients were unstable- needs surgery, 85patients were stable.

Table 2: Symptoms and signs.

Symptoms and signs	No. of patients	Percentage
Abdominal pain	118	90.76
Vomiting	70	53.84
Pulse >100/minute	45	34.61
Blood pressure (BP) <90 mm of Hg systolic	20	15.3
Pallor	25	19.23
Abdominal tenderness	80	61.53
Abdominal gurdng	40	30.76
Abdominal distension	35	26.92
Rebound tenderness	28	21.53
Free fluid	61	46.92
Heamaturia	2	1.53

Investigations

Plain x-ray abdomen

Plain x-ray of abdomen was done in 35 cases, out of the total 130 cases. Gas under diaphragm was found in 20 cases out of 23 bowel perforations detected at laparotomy.

Ultrasound examination

Out of the 130 patients only 60 had +ve FAST at time of presentation. Out of the 70 patients with -ve FAST, only 4 cases had false -ve FAST, one of them, small upper pole splenic hematoma and moderate pelvic free fluid were recognized in the follow up ultrasonography done 12 hours later, the patient’s hemodynamic condition was deteriorating progressively, and splenectomy was done.

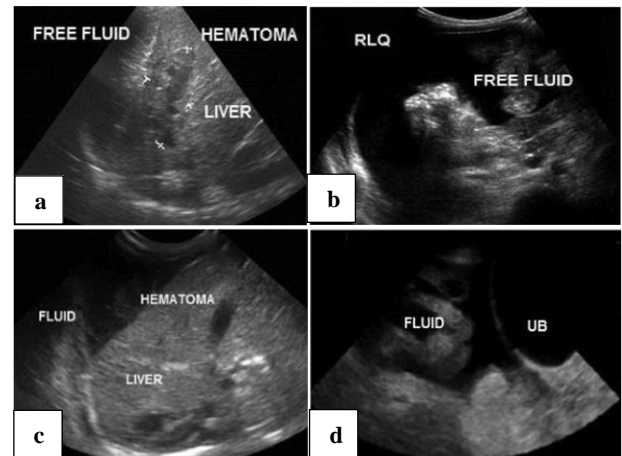


Figure 2: Organ injury, free fluid, haematoma.

Out of the 60 patients with +ve FAST, only one case was false +ve FAST, the patient had ascites due to renal impairment, both kidneys showed grade 2 nephropathy and no gross organ injury is detected by ultrasonography or contrast enhanced computed tomography (CECT).

Out of the 130 patients presented by blunt abdominal trauma, 60 patients had intra-abdominal injury.

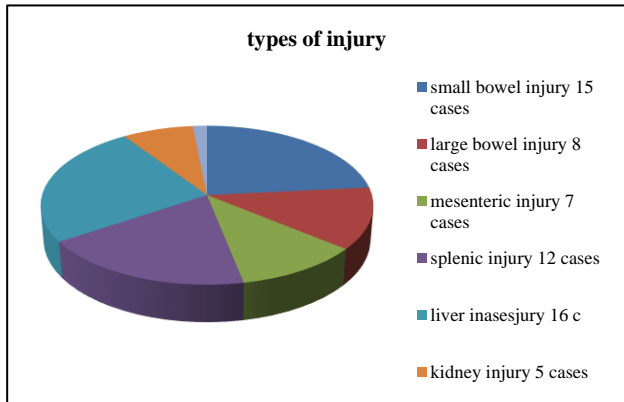


Figure 3: Types of injury.

Out of the 60 patients with intra-abdominal injury, 15 patients had small bowel injury, 8 patients had large bowel injury, 7 patients had mesenteric injury, 16 patients had liver injury, 12 patients had splenic injury, 5 patients had renal injury and one patient had bladder injury (Figure 3).

A total of 130 patients were subjected for ultrasound examination, out of which 60 patients had scan detected solid organ injuries for which they underwent laparotomy for 45 cases and found to have significant injuries that was out of 30 patients bowel and mesenteric injury, 18 patients had primary repair and 5 patients had resection and anastomosis done and 7 patients had mesenteric primary repair. Out of 12 patients had splenic injury, 6 patients had emergency splenectomy. Out of 16 patients hepatic injury, 8 patients had primary repair to stop active bleeding sources. Rest of cases managed conservatively. 1 patients had bladder injury which was repaired.

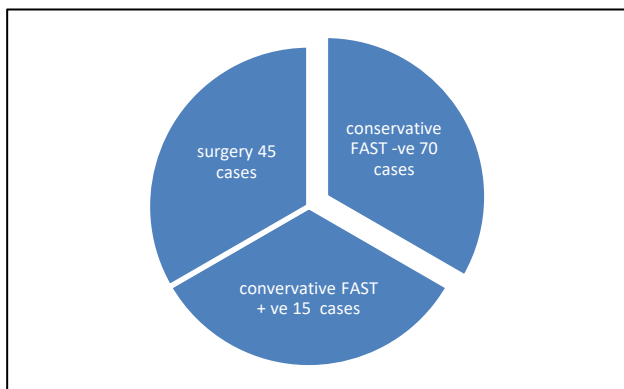


Figure 4: Treatment plan.

Surgically managed 45 cases and conservatively managed 15 patients those was FAST positive but haemodynamically stable, and also 70 patients managed conservatively those was FAST-negative.

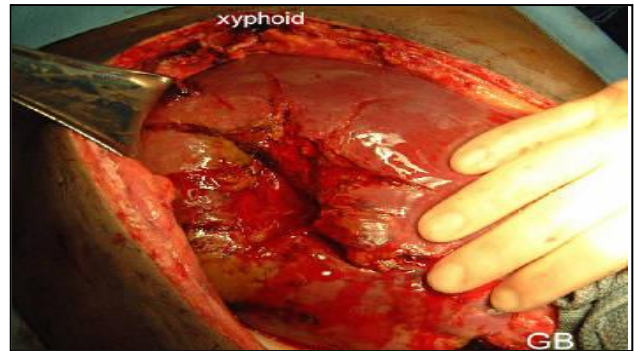


Figure 5: Liver injury.

DISCUSSION

Trauma is one of the common causes of death, and is a major economic and health problem. The abdomen is the third most common injured region, in 25% of cases who require surgical interference. Abdominal trauma is classified as either blunt or penetrating. Penetrating abdominal trauma is easily diagnosed, while blunt trauma complications can be missed if the clinical signs are not evident.⁸

Hemodynamic instability, disturbed level of consciousness and presence of other injuries in the skull, chest, pelvic bones or extremities, all explain the need of an accurate and rapid imaging tool to diagnose associated abdominal visceral injuries.⁹

Contrast enhanced computed tomography (CT) is the radiological golden standard for abdominal visceral injuries. However, renal failure or a previous anaphylactic reaction to contrast material hinders the use of CT in evaluation of some trauma patients. A noncontrast study diminishes the sensitivity of CT in diagnosis of solid organ injuries.¹⁰

CT disadvantages include the need for patient transfer to the CT unit, hazards of ionizing radiation or if contrast media is used, patients may not be co-operative or assume the best position if in pain or with disturbed conscious level. Thus, non-elevated arms, or medical devices (catheters, tubes and lines) will cause artifacts decreasing imaging quality.¹¹ Organ injury can be easily diagnosed by abdominal ultrasound as well as the presence of free intra-abdominal fluid, which could be blood or intestinal secretions that provides indirect evidence of these injuries. Ultrasound is non-invasive, portable using no ionizing radiation, repeatable, and easily performed in the emergency unit, at the same time with resuscitation methods. Focused abdominal sonography for trauma (FAST) is a fast examination method that could demonstrate intraperitoneal fluid. Several studies found this technique to be sensitive (79-100%) and specific (95.6-100%), particularly in hemodynamically unstable patients.¹²

Our study found FAST to be 93.7% sensitive and 98.5% specific, only 4 cases was false -ve FAST, moderate pelvic fluid collection and very small subcapsular splenic (2 cases) and hepatic (2 cases) hypoechoic area less than 1 cm were seen in the follow up ultrasonography done after 24 hours. However, out of 4 false -ve FAST cases, one of the patient was hemodynamically deteriorating with progressive decrease in vital data, and exploration and splenectomy were done. Only one case had false +ve FAST, the patient had ascites due to renal impairment, repeated ultrasonography after 24 hours showed no increase in the amount of intra-peritoneal fluid or organ injury and the patient was hemodynamically stable. Our study showed that 38.3% of cases with intra-abdominal injury had intestinal injury, 26.67% had hepatic injury, 20% had splenic injury, 11.6% had mesenteric injury, 8.3% had renal injury and 1.6% had urinary bladder injury.

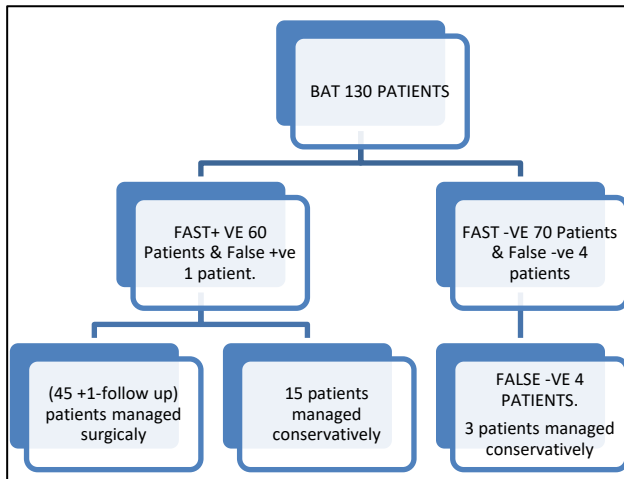


Figure 6: FAST examination.

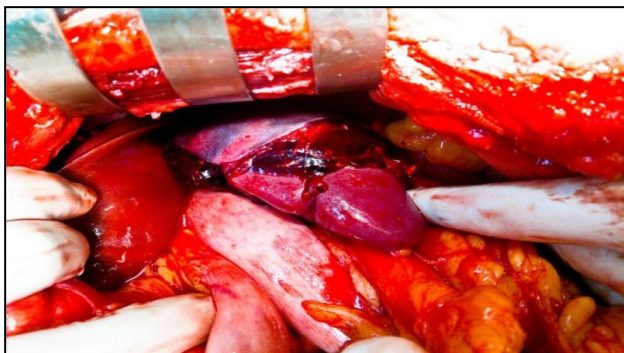


Figure 7: Splenic injury.

Lee et al claimed that hypotensive patients screened in the emergency department with positive FAST findings may be transferred directly to laparotomy, depending on the results of the sonography examination, without the need for CT.¹³

In our study, 45 patients underwent laparotomy after FAST examination. Out of 45 patients, 25 patients had

severe intra-abdominal hemorrhage and hypotension on the basis of clinical assessment and FAST examination. And 20 patients had gas under diaphragm (str. x-ray abdomen) and significant intraperitoneal collection (during FAST). Laparotomy finding that was out of 30 patients bowel and mesenteric injury, 25 patients had primary repair both gut and mesentery and 5 patients had resection and anastomosis done. Out of 12 patients had splenic injury, 6 patients had emergency splenectomy. Out of 16 patients hepatic injury, 8 patients had primary repair to stop active bleeding sources. Rest of cases managed conservatively. 1 patients had bladder injury which was repaired. Surgically managed 45 cases and conservatively managed 15 patients those was FAST positive but haemodynamically stable, and also 70 patients managed conservatively those was FAST-negative.

CT is not an option for patients who are clinically unstable to be transferred to the CT unit, pregnant females, patients with large body habitus. Sonography has some advantages over CT in trauma cases, it is a bedside, fast, reliable one and it uses no ionizing radiation. Furthermore, there is no use of iodinated contrast agents avoiding the associated risk of contrast reaction or nephrotoxicity.¹⁴ CT-scan is very restricted used in our hospital and also it is very time consuming specially to get reports.

Patients with small splenic or hepatic injuries who were hemodynamically stable do not need further investigations and are treated conservatively. Patients with major splenic or hepatic injuries and who are hemodynamically stable could perform CT abdomen for accurate characterization of their injuries. Jalli et al, suggested that CT scan is the modality of choice in hemodynamically stable patients who have major suspicions for renal injuries.¹⁴

In cases of renal trauma, the exact extent of injury should be assessed for accurate therapy choice. Tears that expand into or through the pelvi-calyceal system (grade IV and higher) and ureteric injuries are not very obvious on sonography if there is no significant urinary leakage. Delayed contrast-enhanced CT performed 10 min after contrast injection can easily show extravasation from the pelvi-calyceal system or the ureters and, thus, delineate the location and extent of damage.¹⁵

In our study, 5 cases of renal injury were reported, those cases were hemodynamically stable, one of them had subcapsular hematoma while the other had perinephric hematoma and renal laceration; however, ultrasonography could not detect the exact extension of the injury and could not exclude injury of collecting system, CECT was performed during follow-up period, and the case of subcapsular hematoma was treated conservatively. In a study done by Sato and Yoshii, they reported that ultrasonography was found to detect and classify parenchymal injuries efficiently, when done by

experienced examiners despite disadvantages in detecting superficial and vascular injuries.¹⁶

In our study, 4 cases were false –ve FAST, those were mild to moderate free fluid in pelvis during follow-up sonography. But those cases were clinically and haemodynamically stable, those cases were managed conservatively.

In our study, 2 cases were died due to associate injury like head injury, those cases had FAST –ve.

All conservatively managed cases except one, were followed by clinically and, sonography assessment done after 24 hours, 48 hours and 72 hours after that discharged.

A relatively small study population might not have reflected the manifestations in the whole population, so the study may be repeated with larger sample size.

CONCLUSION

Blunt abdominal trauma is a common surgical emergency and requires immediate medical services. The incidence of abdominal trauma is increasing globally. Blunt trauma to abdomen is on rise due to excessive use of motor vehicles and it is a cause of considerable morbidity and mortality among trauma patients. Initial resuscitation followed by appropriate management decision with help of USG is important in management.

The trauma surgeon should rely on his physical findings in association with the use of modalities such as x-ray abdomen, USG abdomen, and abdominal paracentesis. Hollow viscus perforations are relatively easy to pick on x-ray. However, solid organ injuries are sometimes difficult to diagnose due to restricted use of modern amenities such as CT scan in India.

Initial resuscitation followed by clinical and ultrasonography assessment is considered the best modality in initial evaluation of blunt abdominal trauma patients as it is noninvasive, readily available, and requires minimal preparation time.

Ultrasonography is very useful in follow up of patients with intra-abdominal injury and decreases use of CT which has the disadvantages of being expensive, high dose radiation and also due to restricted use of modern amenities such as CT-scan in tertiary care in India. Repeated ultrasonography in patients of blunt abdominal trauma and close clinical observation increases the sensitivity of ultrasonography for intra-abdominal bleeding to nearly 100%.

Funding: No funding sources

Conflict of interest: None declared

Ethical approval: The study was approved by the Institutional Ethics Committee Burdwan medical college.

REFERENCES

1. World Health Organization (WHO). Injuries and Violence: The Facts 2014. Geneva, Switzerland: WHO Press; 2014.
2. Roy N, Veetil KD, Khajanchi MU, Kumar V, Solomon H, Kamble J, et al. Learning from 2523 trauma deaths in India opportunities to prevent in-hospital deaths. BMC Health Serv Res. 2017;17(1):142.
3. Karamercan A, Yilmaz TU, Karamercan MA. Blunt abdominal trauma: evaluation of diagnostic options and surgical outcomes. Travma Acil Cerrahi Derg. 2008;14(3):205-10.
4. Davis JJ, Cohn I, Nance FC. Diagnosis and management of blunt abdominal trauma. Ann Surg. 1976;183(6):672-8.
5. Kendall JL, Kestler AM, Whitaker KT, Adkisson MM, Haukoos JS. Blunt abdominal trauma patients are at very low risk for intraabdominal injury after emergency department observation. West J Emerg Med. 2010;12(4):496-504.
6. Mohammadi A, Ghasemi-Rad M. Evaluation of gastrointestinal injury in blunt abdominal trauma ‘‘FAST is not reliable’’: the role of repeated ultrasonography. World J Emerg Surg. 2012;7(1):2.
7. Tsui CL, Fung HT, Chung KL, Kam CW. Focused abdominal sonography for trauma in the emergency department for blunt abdominal trauma. Int J Emerg Med. 2008;1:183-7.
8. Gad MA, Saber A, Farrag S, Shams ME, Ellabban GM. Incidence, patterns, and factors predicting mortality of abdominal injuries in trauma patients. N Am J Med Sci. 2012;4(3):129-34.
9. Farrath S, Parreira JG, Perlingeiro JA, Solda SC, Assef JC. Predictors of abdominal injuries in blunt trauma. Rev Col Bras Cir. 2012;39(4):295-301.
10. Hedrick TL, Sawyer RG, Young JS. MRI for the diagnosis of blunt abdominal trauma: a case report. Emerg Radiol. 2005;11(5):309-11.
11. Cokkino D, Antypa E, Stefanidis K, Tserotas P, Kostaras V, Parlamenti A, et al. Contrast-enhanced ultrasound for imaging blunt abdominal trauma-indications, description of the technique and imaging review. Ultraschall Med. 2012;33(1):60-7.
12. Jansen JO, Yule SR, Loudon MA. Investigation of blunt abdominal trauma. BMJ. 2008;336(7650):938-42.
13. Lee BC, Ormsby EL, McGahan JP, Melendres GM, Richards JR. The utility of sonography for the triage of blunt abdominal trauma patients to exploratory laparotomy. AJR. 2007;188(2):415-21.
14. Jalli R, Kamalzadeh N, Lotfi M, Farhangiz S, Salehipour M. Accuracy of sonography in detection of renal injuries caused by blunt abdominal trauma: a prospective study. Ulus Travma Acil Cerrahi Derg. 2009;15(1):23-7.
15. Korner M, Krotz MM, Degenhart C, Pfeifer KJ, Reiser MF, Linsenmaier U. Current role of

emergency US in patients with major trauma. *RadioGraphics.* 2008;28:225-42.

16. Sato M, Yoshii H. Reevaluation of ultrasonography for solid-organ injury in blunt abdominal trauma. *J Ultrasound Med.* 2004;23(12):1583-96.

Cite this article as: Ali SKS, Mukhopadhyay NN, Bhattacharya J, Chattopadhyay M. Blunt abdominal trauma: initial resuscitation followed by clinical and focused abdominal sonography assessment important diagnostic tools of organ injury due to restricted use of CT-scan in a tertiary care in India. *Int Surg J* 2022;9:174-80.