

Case Report

Seat belt syndrome: a case report

Vinod Kumar Nigam*, Sidharth Nigam

General and Minimal Access Surgery, Gurugram, Max Hospital, Haryana, India

Received: 27 October 2021

Revised: 26 November 2021

Accepted: 03 December 2021

***Correspondence:**

Dr. Vinod Kumar Nigam,

E-mail: drnigamvk@gmail.com

Copyright: © the author(s), publisher and licensee Medip Academy. This is an open-access article distributed under the terms of the Creative Commons Attribution Non-Commercial License, which permits unrestricted non-commercial use, distribution, and reproduction in any medium, provided the original work is properly cited.

ABSTRACT

Seat belt syndrome happens when a car meets an accident and person sitting in the car with seat belt on gets abdominal injuries typically, seat belt mark with intestinal injuries and fractures of ribs and lumber spine. The abdominal injuries are usually intestinal perforations. Doctor seeing the motor vehicle accident must keep in mind seat belt syndrome while examining. As the traffic rules are getting enforced strictly in developing countries we are seeing seat belt syndrome cases in these countries more and more. We presented here a case of seat belt syndrome in 35 years old women.

Keywords: Abdominal injuries, Accident, Automobile, Fracture, Intestinal perforations, Seat belt syndrome

INTRODUCTION

Seat belt syndrome is a term used for injuries caused by wearing a seat belt in a vehicle while travelling and getting involved in an accident. It's defined clinically as a seat belt sign (seat belt mark on the body) plus an intra-abdominal organ injury (that is, bowel perforations) and/or thoracic-lumbar vertebral fractures.¹ The seat belt sign was originally described by Garrett and Braunstein in 1962 as linear ecchymosis of the abdominal wall following a motor vehicle accident.²

A unique association of injuries has emerged in adults and children with the use of seat belts.³ Seat belt Syndrome injuris may be very mild as an abrasion or bruising or can be very serious as bowel perforation. Seat belt sign is linear contusion mark over anterior abdominal wall. The first most detailed statistical analysis was carried out by Kohlberg and Robinson and they concluded that the risk taken by an occupant without a seat belt was 70% higher than that for a belted occupant.^{4,5}

A recent federal motor vehicle safety standard requiring lap and shoulder belts in all rear seat position has potential to decrease the risk of injury to elder children using seat belts.⁶

CASE REPORT

A 35 years old female co-passenger of a car was brought to the emergency department of the hospital after an accident. She was in shock with 120/min heart rate, 90/60 mmHg blood pressure and in severe pain, unable to take deep breath. Examination revealed a transverse abrasion mark on lower abdomen and peritonitis. Sternal pressure indicated left lower rib fractures. Investigations including X-ray of chest, ultrasound of abdomen and CT scan of abdomen revealed multiple left lower rib fractures and intestinal perforations. Emergency laparotomy was performed.⁷⁻⁹ Two perforations were found in jejunum (Figure 1) and peritonitis.

Peritoneal lavage was performed with normal saline. Two jejunal perforations were closed with 3-0 silk through and through and then buried with sero-serosal continuous suture. Two 24 number abdominal drains were introduced in peritoneal cavity. One for pelvis and other for right paracolic gutter and intestinal perforation sites. Abdominal wound was closed by no. 1 prolene continuous suture and with skin staples. Patient remained tachycardiac for 3 days, because of peritoneal pain and pain due to rib fractures, and laparotomy but gradually settled and was discharged after 8 days of operation.

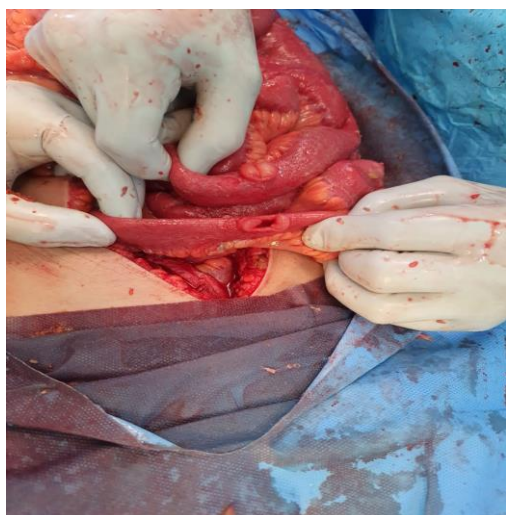


Figure 1: Jejunal perforations after a car accident.

DISCUSSION

A seat belt syndrome involves thoraco-lumbar vertebral fractures and intra-abdominal organ injury.⁷ It was increased significantly in the last two decades, heading to a decrease in mortality for road traffic accidents (RTA). While a seat belt of good design and properly worn will prevent the occupant of a car being flung violently against steering wheel, dashboard, or behind screen, the force applied to the belt is considerable and increases the chances of intra-abdominal injuries.^{8,9}

Bruising of anterior abdominal wall is seen in almost every case, as in our case also, and is due to belt acting as fulcrum on the soft rounds of the abdominal wall. Injury to abdominal viscera has been attributed to the compression between the belt and the vertebral column.¹⁰ In our case there was no muscle injury and the compression caused two jejunal perforations. Early diagnosis and treatment is the main stay of treatment. In this case the initial pain subsided and patient went to home and that caused the delay in the diagnosis and treatment.

Pathogenesis of seat belt syndrome injuries indicates that they are caused by hyperflexion of the spine around the lap strap in sudden deceleration leading to crushing of intra-abdominal contents between the spine and the seat belt. Fixed portion of the bowel such as proximal jejunum and distal ileum are more susceptible to injury than mobile portions since mobile segments can escape the high-pressure injury and damage.¹¹

Due to the use of the most common 3-points seat belts cervical spine is commonly affected. In case of a sudden stoppage of the vehicle or a frontal impact, the head sharply continues its forward motion based on the physical law of conservation of energy. Depending on the value of the deceleration, the relative weight of the head can be increased many times. This causes hyperflexion (bending forward) in the cervical spine and lead to its disability.^{12,13}

CONCLUSION

If one is suspecting a seat belt syndrome in a car accident case and there is an ecchymosis or abrasion mark on abdominal wall, exploratory laparotomy or a diagnostic laparoscopy must not be forgotten. There is a need of awareness among doctors when examining a vehicle accident victim to not to forget seat belt injuries. If the condition of the patient doesn't improve one must consider open and see than wait and watch. Seat belt syndrome is now increasing in Asian countries also because of increased car traffic. Inappropriate seat belt application is one of the main reasons of seat belt injuries. We presented here a case of seat belt syndrome.

ACKNOWLEDGEMENTS

The authors thank Dr. Charvi Chawla and Mr. Manish Kumar for their valuable support during this work.

Funding: No funding sources

Conflict of interest: None declared

Ethical approval: Not required

REFERENCES

1. Torba M, Hijazi S, Gjata A, Buci S, Madani R, Subashi K. Seat belt syndrome, a new pattern of injury in developing countries. Case report and review of literature. *G Chir.* 2014;35(7):177-80.
2. Wotherspoon S, Chu K, Brown AF. Abdominal injury and the seat-belt sign. *Emerg Med.* 2001;13(1):61-5.
3. Santschi M, Echavé V, Laflamme S, McFadden N, Cyr C. Seat-belt injuries in children involved in motor vehicle crashes. *Can J Surg.* 2005;48(5):373-6.
4. Kihlbero JK, Robinson. In: *Automotive Crash Injury Research Report.* Cornell University: New York.
5. George I, Patelis S. Seat belt syndrome: a global issue. *Health Sci J.* 2010;4(4):202-9.
6. España JF, Durbin DR. Injuries to belted older children in motor vehicle crashes. *Accid Anal Prev.* 2008;40(6):2024-8.
7. Kelly F, Brien GC, Broe PJ. Severe abdominal injuries sustained in an adult wearing a pelvic seatbelt: a case report and review of the literature. *Ir J Med Sci.* 2008;177(4):385-7.
8. Hamilton JB. Seat-belt injuries. *Br Med J.* 1968;4(5629):485-6.
9. Ozaibi L, Adnan J, Hassan B, Mazroui A, Badri F. Seat belt syndrome: Delayed or missed intestinal injuries, a case report and review of literature. *Int J Surg Case Rep.* 2016;20:74-6.
10. Williams RD, Sargent FT. The mechanism of intestinal injury in trauma. *J Trauma.* 1963;3:288-94.
11. Abbas AK, Hefny AF, Zidan FM. Seatbelts and road traffic collision injuries. *World J Emerg Surg.* 2011;6(1):18.

12. Saukko P, Knight B. *Knighys forensic pathology*. 3rd ed. London: Edward Arnold; 2004.
13. Schulman CI, Carvajal D, Lopez PP, Soffer D, Habib F, Augenstein J. Incidence and crash mechanisms of aortic injury during the past decade. *J Trauma*. 2007;62(3):664-7.

Cite this article as: Nigam VK, Nigam S. Seat belt syndrome: a case report. *Int Surg J* 2022;9:233-5.