

## Case Report

# The mysterious chronic finger pain- glomus tumour: a case report

Rajranjan Kumar\*

Department of Surgery, Durgapur Steel Plant Hospital, J. M. Sengupta Road, Durgapur, Bardhaman, West Bengal, India

**Received:** 26 October 2021

**Accepted:** 29 November 2021

**\*Correspondence:**

Dr. Rajranjan Kumar,

E-mail: [dr.rajranjan@yahoo.com](mailto:dr.rajranjan@yahoo.com)

**Copyright:** © the author(s), publisher and licensee Medip Academy. This is an open-access article distributed under the terms of the Creative Commons Attribution Non-Commercial License, which permits unrestricted non-commercial use, distribution, and reproduction in any medium, provided the original work is properly cited.

### ABSTRACT

Glomus tumours are very rare, small, painful benign hamartomas, arising from the arterial end of the glomus body. Glomus tumors account for 1-2% of the soft tissue tumors in the hand. The exact etiopathogenesis is unknown. It is incapacitating to the patients because of chronicity of symptoms and lack of proper investigative tools to diagnose the tumor at an early stage. The clinical diagnosis was made on the basis of medical history and MRI findings. We report a case of glomus tumor in a 35-year-old female, situated in the pulp of distal phalanx of right middle finger, which was resected completely. Excision of lesion imparted complete resolution of symptoms. The histopathological report was consistent with glomus tumor.

**Keywords:** Finger, Glomus tumour, MRI hand, Pain

### INTRODUCTION

The normal glomus body is an arteriovenous shunt involved in thermoregulation, mostly concentrated in the digits. Glomus tumors are rare benign hamartomas composed of endothelium lined vascular spaces (Sucquet-Hoyer Canal) surrounded by glomus cells.<sup>1,2</sup> Arising from neuromyoarterial apparatus of glomus body.<sup>7</sup> Hoyer first described them in 1877, while the first complete clinical description was given by Masson.<sup>4</sup>

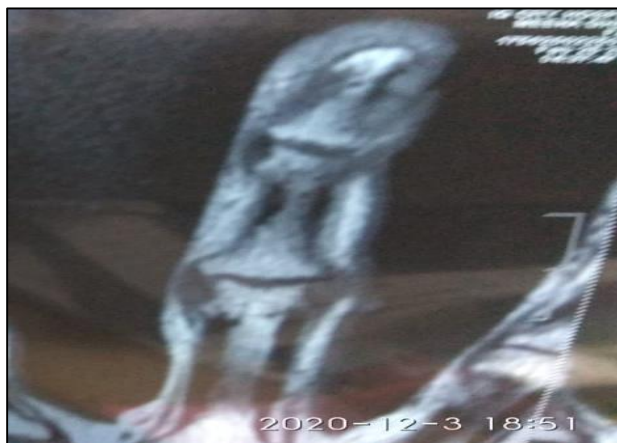Majority of glomus tumors are small benign neoplasm that occur in the dermis or sub cutis of extremities.<sup>5</sup> Glomus tumors can be solitary or multiple. Some cases of large multiple visceral lesions are reported to be malignant.<sup>6</sup> The precise etiopathogenesis is unknown.<sup>8</sup>

Average age at presentation is from 30-50 years of age. Glomus tumors are usually under 1cm in size, present as a faint bluish purple papule and associated with classic triad of symptoms: local sensitivity, pain with cold exposure and severe pain on minor trauma.<sup>2</sup>

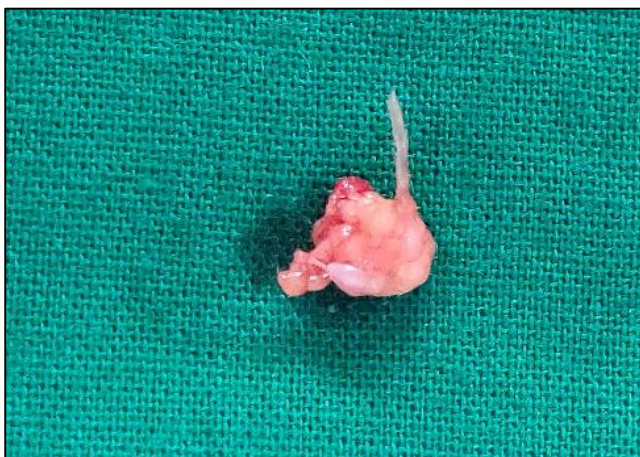### CASE REPORT

A 35-year-old Hindu female came to surgical clinic with history of pain at the tip of right middle finger for the last 2-years. She denied history of any preceding trauma. She had worsening of symptoms at coughing or sneezing, but there is no history of root pain. She had localised pain to a point on the right middle finger near its tip over distal phalanx. There is no history of any skin discoloration. She gave history of worsening of pain on cold exposure, but no history of a typical of Reynaud's phenomenon. On examination there was sharp localised tenderness over the right middle finger near tip. There was no local rise of temperature or any discoloration. She was afebrile and no any regional lymphadenopathy was detected. Systemic examination was normal. Routine blood examination and X-Rays right hand were within normal limits. HRMRI proved the diagnosis of Glomus tumour (Figure 1). Complete excision was done and patient became fully asymptomatic following the surgery and there were no postoperative complications. No recurrence of symptoms was found at one year follow up. Resected specimen sent

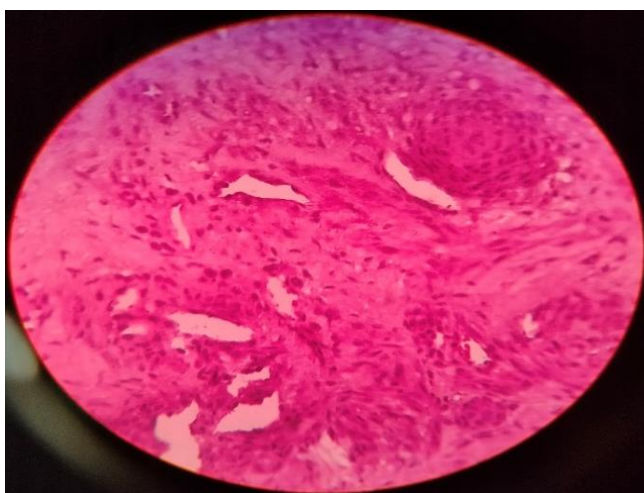
for biopsy (Figure 2) and report was consistent with the diagnosis of Glomus tumour (Figure 3).



**Figure 1: MRI mass with intense high signal on T2 image.**



**Figure 2: The mass removed en block.**



**Figure 3: Neoplastic cells with monomorphic round or oval nuclei and abundant pink cytoplasm. Tumour cells invading vessel wall.**

## DISCUSSION

Glomus tumour is a slow growing benign lesion with intense pain. Lesions are characterised by a faint bluish purple papule, paroxysmal pain, pin head tenderness and cold sensitivity. The lesions are usually located on extremities, especially in subungual area, followed by lateral aspect of digits, pulp and palm, but may occur on any other parts of body.<sup>8</sup> Multiple glomus tumors are common in male called glomangiomas and have autosomal dominance pattern with incomplete penetrance. Rarely glomus tumors may present with clinical features like large size, visceral origin (GUT and GIT), multi-centricity and infiltrative growth pattern.<sup>5-7</sup> The delay in diagnosis causes immense morbidity to patients. Proper history, high index of suspicion and careful clinical examination are prerequisite to clinch the diagnosis. Routine laboratory investigations have no role in diagnosis of glomus tumor. High resolution Magnetic Resonance imaging (HRMRI) is the investigation of choice and assesses tumour characteristics more accurately (Figure 1). High resolution CT scan and X-Rays were not helpful in our case. The treatment of choice is complete excision, which is crucial in prevention of recurrence and reduction of symptoms, with low rate of recurrence.<sup>3</sup> A bloodless surgical field is essential to allow meticulous removal of tumor. We excised the tumor completely and there was no recurrence of pain on follow up for 1 year. Complete excision provides best chance of cure with best functional outcome. The diagnosis was confirmed by histology (Figure 3). The abatement of symptoms following surgery is quite pleasurable both for the patient and the surgeon.

## CONCLUSION

Accurate preoperative localisation of glomus tumour is vital for complete extirpation and to avoid recurrence. HRMRI is the investigation of choice. Complete excision ensures best chance of cure with best functional outcome. The alleviation of symptoms following surgery is quite gratifying both for the patients and the surgeon.

## ACKNOWLEDGEMENTS

Jyoti Prakash was the contributor in the preparation of manuscript, linguistic revision and uploading of the photos. Author is thankful to Dr. P. P. Roy, HOD, general surgery and Dr. Biswajit Saha, director (M and HS) for guidance and motivation.

*Funding: No funding sources*

*Conflict of interest: None declared*

*Ethical approval: Not required*

## REFERENCES

1. Dwaber RP, Baran R. Disorders of nails in: Champion RH, Burton JL, Ebling FJG, editors.

- Rock/Wilkinson /Ebling Textbook of Dermatology. 5th ed. Oxford: Blackwell Science. 1992;2497-532.
2. Heys SD, Brittened J, Atkinson P, Eremin O. Glomus tumour: an analysis of 43 patients and review of the literature. *Br J Surg.* 1992;79:345-7.
  3. Mravic M, La Chaud G, Nguyen A, Scott MA, Dry SM, James AW. Clinical and Histopathological Diagnosis of Glomus Tumor: An Institutional Experience of 138 Cases. *Int J Surg Pathol.* 2015;23(3):181-8.
  4. Gombos Z Zhang PJ. ‘‘Glomus Tumor’. *Arch Pathol Lab Med.* 2008;132(9):1448-52.
  5. Enzinger FM, Weiss SW. *Soft Tissue Tumors.* 2nd ed. St. Louis: Mosby. 1988;422-32.
  6. Hufschmidt K, Glomus tumors of the upper limb: Single –center retrospective study of clinical and functional outcomes. *Hand Surgery and Rehabilitation.* 2017;36.
  7. Chou T, Pan SC, Shieh SJ, Lee JW, Chiu HY, Ho CL. Glomus tumor: twenty- year experience and literature review. *Ann Plast Surg.* 2016;76(1):S35-40.
  8. Rosner IA, Argenta AE, Wshinghton KM. Unusual volar pulp location of glomus tumor. *Plast Reconstr Surg Glob Open.* 2017;5(1):e1215.

**Cite this article as:** Kumar R. The mysterious chronic finger pain- glomus tumour: a case report. *Int Surg J* 2022;9:1262-4.