

Case Report

Synthetic mesh placement - modality of choice in spontaneous intercostal pleural herniation: a case report

Shashwat Vyas*, Amit Goyal

Department of General Surgery, SMS Medical College, Jaipur, Rajasthan, India

Received: 18 October 2021

Revised: 10 November 2021

Accepted: 23 November 2021

***Correspondence:**

Dr. Shashwat Vyas,

E-mail: vyas.shashwat@gmail.com

Copyright: © the author(s), publisher and licensee Medip Academy. This is an open-access article distributed under the terms of the Creative Commons Attribution Non-Commercial License, which permits unrestricted non-commercial use, distribution, and reproduction in any medium, provided the original work is properly cited.

ABSTRACT

Hernia is defined as protrusion of a viscus or its part from the wall covering it and in some rare cases due to increased intercostal space there is spontaneous herniation of pleura and lung also known as extrathoracic lung hernia. A 48 year gentleman was admitted in our centre for chest wall swelling which has developed spontaneously 1 year back, painless, with cough impulse, further investigations like chest x-ray revealed nothing, subsequently CT thorax showed intercostal pleural hernia. He underwent surgery which diagnosed it as a case of intercostal pleural hernia having defect between 8th and 9th rib. Subsequently primary repair of defect was done with placement of monofilament mesh over it and then approximation of intercostal space was done with monofilament suture placed over 8th and 9th ribs. Post operatively patient had no complications and no recurrence of hernia. Spontaneous pleural herniation is a usually caused by coughing, heavy weight lifting, weakness of thoracic muscles by smoking, obesity etc. Ideal management is to treat the aetiology along with repair of the defect to prevent recurrence. In the present case the hernia developed after a bout of cough due to increased intercostal space between 8th and 9th ribs and also due to obesity leading to weak musculature. Intercostal pleural hernia repair can be achieved by primary repair of defect but it is advisable to use synthetic materials such as knitted monofilament polypropylene (Marlex) mesh to provide addition support to prevent recurrence.

Keywords: Spontaneous intercostal pleural hernia, Thoracic hernias, Monofilament mesh repair, Lung herniations

INTRODUCTION

Hernia is defined as protrusion of a viscus or its part from the wall covering it and cases like spontaneous protrusion of pleural herniation is a rare entity.¹ Due to increased intercostal space there is herniation of pleural and lung which can be secondary to an episode of cough, obesity, heavy weight lifting, other causes of lung /pleural herniation include trauma, neoplastic /inflammatory processes etc. We hereby presenting a rare case of a 48yr old gentleman who developed spontaneous intercostal lung herniation subsequent to a bout of cough. The research work has reported in line with SCARE criteria.²

CASE REPORT

A 48-year gentleman, who was admitted in our centre with complain of a chest wall swelling since past 1 year, which was spontaneous in onset, painless, increases in size while coughing and with history of chronic smoking. There was no history of trauma or similar complaint in past. Upon physical examination, there was an 8×7 cm chest wall swelling present over the antero-lateral aspect of thorax, spontaneous reduction and associated with cough impulse. There was no weakness of accessory respiratory muscles. The routine blood investigations were carried out which were within normal limits.

A chest radiograph was advised which revealed nothing even on Valsalva manoeuvre. Thus, CT scan of thorax was done and it diagnosed it as intercostal herniation. The patient was advised surgery and intraoperatively it was found that he has developed herniation of pleura between 8th and 9th ribs which was intact. with defect size 3×4 cms.

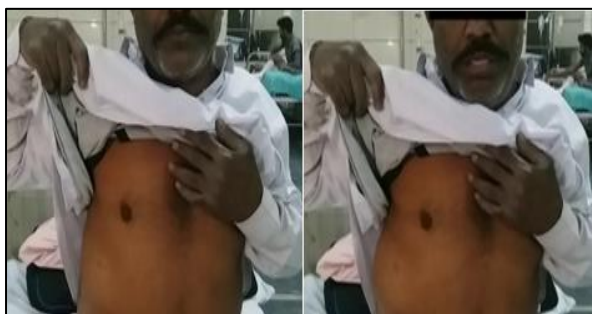

Figure 1: Chest wall swelling before and after coughing.

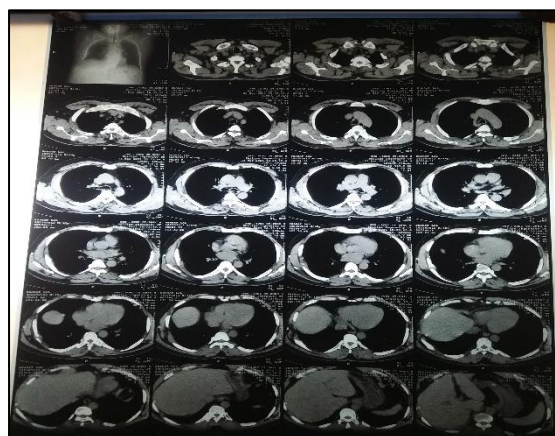


Figure 2: CT scan thorax revealed it as intercostal herniation.

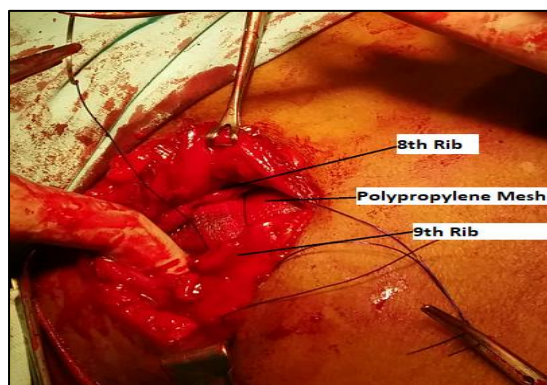


Figure 3: Intraoperative picture showing approximation of intercostal space.

The hernia sac was identified and primary repair of the defect was done. After the reduction of hernia along with pleura, as there was widening of the intercostal space,

monofilament sutures were used to approximate it and a synthetic Monofilament mesh of size 7.5×7.5 cm was placed above the defect and was fixed with ribs and subsequent closure done. There was no obvious widening detected postoperatively and there were no postoperative complications and patient was discharged after 4 days. No recurrence or any other complications after 7 months of surgery.

Table 1: Types of chest wall hernias.

Acc. to anatomic location	Cervical Thoracic Diaphragmatic
Acc. to etiology	Congenital Acquired: Traumatic Spontaneous Neoplastic/inflammatory

DISCUSSION

Lung herniations can be classified as:^{3,4} In cases of spontaneous herniation of lung /pleura usually there is evidence of pre-existing weakness in thoracic wall and superimposed increased intrathoracic pressure due to an episode of cough (secondary to chronic bronchitis, whooping cough).⁵ The frequency is more in Males, with various predisposing factors like smoking, chronic lung disease, obesity. The commonly implicated site for herniation is between 8-9th ribs on anterior side (absent muscular support as seen in posterior side by rhomboids, trapezius, latissimus dorsi). Due to a bout of vigorous cough, there was widening of intercostal space between 8-9th ribs and subsequent herniation of pleura and lung. The clinical presentation of lung hernia involves a palpable, reducible, crepitant chest wall swelling, with cough reflex present and change in size with respiration. Investigations includes chest radiographs which can indicate increased intercostal space and rarely presence of lung parenchyma outside the thorax. Diagnosis can be achieved by CT scan of thorax which delineates the location, dimension, any other abnormality with accuracy. The management of lung herniation depends on clinical picture, conservative management can be tried by treating the aetiology along with using compressive pads, corsets. But intercostal lung hernias rarely resolve spontaneously, thus surgery is the treatment modality of choice. The small defect size increases the risk of incarceration and difficulty in reduction later, also strapping decreases the thoracic wall motion subsequently increases the risk of recurrent infections. The surgical procedure involves reduction of the hernia, fixing the periosteum of both the ribs which decreases the intercostal space and mesh placement can be done if needed in larger defects.⁶ Other approaches include reconstruction by periosteum, muscles or with fascia lata. The mesh used can be a Marlex mesh or Polytetrafluoroethylene (PTFE) patch.¹ The problem with the use of mesh includes risk of mesh infection, chances

of displacement. The potential advantage of mesh in providing additional support thus decreases the risk of relapse is the reason by nowadays it is preferred even in small defects.

CONCLUSION

Thus, in conclusion, we have observed in cases of spontaneous lung herniation, the use of prosthetic mesh can be advised as the surgical modality after primary repair of defect as it reduces the risk associated with recurrence and subsequent risks of incarceration.

Funding: No funding sources

Conflict of interest: None declared

Ethical approval: Not required

REFERENCES

1. Haro A, Komiya K, Taguchi Y. A rare case of an intercostal lung herniation with fractures of the fifth and sixth ribs after thoracic surgery. Int J Surg Case Rep. 2017;41:473-6.
2. Agha RA, Fowler AJ, Saeta A, Barai I, Rajmohan S, Orgill DP et al. The SCARE Statement: Consensus-based surgical case report guidelines. International Journal of Surgery. 2007;34:180-6.
3. Weissberg D. Lung hernia – a review. Adv Clin Exp Med. 2013;22:611-3.
4. Forty J, Wells FC. Traumatic intercostal pulmonary hernia. Ann. Thoracic Surg. 1990;49:670-1.
5. Athanassiadi K, Bagaev E, Simon A. Lung herniation: a rare complication in minimally invasive cardiothoracic surgery. Eur J Cardiothorac Surg. 2008;33:774-6.
6. Jacka MJ, Luison F. Delayed presentation of traumatic parasternal lung hernia. Ann Thoracic Surg. 1998;65:1150-1.

Cite this article as: Vyas S, Goyal A. Synthetic mesh placement - modality of choice in spontaneous intercostal pleural herniation: a case report. Int Surg J 2022;9:242-4.