

## Original Research Article

# Multiple core histopathologies for discriminative diagnosis of phyllodes pathology in breast

Vijay Pratap Singh<sup>1\*</sup>, Akash Kumar Singh<sup>1</sup>, Arun Kumar Jha<sup>2</sup>, Sumantra Sircar<sup>1</sup>, Vishal Mohan Singh<sup>3</sup>, Pranab Kumar Verma<sup>4</sup>, Manish Jaipuriyar<sup>4</sup>, Priyadarshi Ranjan<sup>5</sup>, Chandan Kumar Singh<sup>6</sup>, Sanjay Kumar<sup>4</sup>

<sup>1</sup>Department of Oncoplastic Surgery, <sup>2</sup>Department of Clinical Research and Academics, <sup>3</sup>Department of Anesthesia, <sup>4</sup>Department of Pathology, <sup>5</sup>Department of Onco Plastic Surgery, <sup>6</sup>Department of Cancer Cytogenetics and Research, Savera Cancer and Multispeciality Hospital, Patna, Bihar, India

**Received:** 06 January 2023

**Revised:** 10 May 2023

**Accepted:** 15 May 2023

### \*Correspondence:

Dr. Vijay Pratap Singh,

E-mail: vijaypsingh\_2000@yahoo.com

**Copyright:** © the author(s), publisher and licensee Medip Academy. This is an open-access article distributed under the terms of the Creative Commons Attribution Non-Commercial License, which permits unrestricted non-commercial use, distribution, and reproduction in any medium, provided the original work is properly cited.

## ABSTRACT

**Background:** Historical patient's records were analyzed. Patients diagnosed with phyllodes tumors of the breast who received preoperative core needle biopsy and undergone breast surgery at a tertiary cancer centre in Patna, Bihar, India from January 2020 to December 2020. The resulting data allowed us to compare the accordance between core needle biopsy and final histopathology of phyllodes tumor of the breast patients and evaluate the accuracy of core needle biopsy in preoperative diagnosis.

**Methods:** This is a retrospective study evaluated the case records of one hundred twenty (n=120) patients for core needle biopsy findings and subsequent histopathology reports post-surgery. Sensitivity and significance of core needle biopsy was determined for phyllodes tumor of the breast.

**Results:** A total of one hundred twenty (n=120) patients' data were analyzed. There were ninety (n=90) fibroadenoma and thirty (n=30) phyllodes tumor patients. Sensitivity of core needle biopsy for benign tumor was 64.2%, borderline 40% and a malignant phyllodes tumor was 100% respectively.

**Conclusions:** Core needle biopsy provides a pathological basis for pre-operative diagnosis of phyllodes tumor, but it has a low accuracy and offers limited guidance for surgical decisions, if used alone. An integrated assessment using needle biopsies in combination with clinical data and imaging features is suggested as a reliable strategy to aid phyllodes tumor diagnosis and subsequent treatment.

**Keywords:** Core needle biopsy, Phyllodes tumor of the breast, Phyllodes tumor borderline, Phyllodes tumor malignant, Phyllodes tumor benign, Fibroepithelial tumor, Mammography, Magnetic resonance imaging, Diagnostic accuracy

## INTRODUCTION

Phyllodes tumor of the breast are very rare, accounting for 0.3-1% of all breast tumors and have an incidence of 2.1 per million.<sup>1</sup> They are classified as benign, borderline and malignant tumors based on their histopathological presentation. The peak age of women which occurs is

around 35-55 years.<sup>2,3</sup> The tumor is rarely found in adolescents and the elderly. The world health organization adopted the term phyllodes tumor and as described by Rosen sub classified them histologically as benign, borderline, or malignant according to the features such as tumor margins, stromal overgrowth, tumor necrosis, cellular atypia, and number of mitosis per high power field.<sup>4</sup>

**Table 1: Demonstrates the WHO classification of phyllodes tumor.**

Criteria	Benign	Borderline	Malignant
<b>Stromal cellularity and atypia</b>	Minimal	Moderate	Marked
<b>Stromal overgrowth</b>	Minimal	Moderate	Marked
<b>Mitoses/10 high power fields</b>	0-4	5-9	≥10
<b>Tumor margins</b>	Well circumscribed pushing tumor margins	with Zone of microscopic invasion around tumor margins	Infiltrative tumor margins

The majority of phyllodes tumors have been described as benign (35-64%) with the remainder divided between the borderline and malignant subtypes. The term phyllodes tumor represents a wide range of fibroepithelial diseases and presence of an epithelial component with stromal components differentiates the phyllodes tumor from other stromal sarcomas. Accurate preoperative pathological or core needle biopsy allows correct surgical planning and avoidance of reoperation, either to achieve wider excision or for subsequent tumor recurrence.<sup>5-7</sup> Malignant phyllodes tumors, if left untreated, have an inclination for rapid growth and metastatic spread. In contrast, benign phyllodes tumors on clinical, radiological, and cytological examination are often indistinguishable from fibroadenomas and can be cured by local surgery. With the nonoperative management of fibroadenomas widely adopted, the importance of phyllodes tumors today lies in the need to differentiate them from other benign breast lesions. Treatment can be either wide local excision or mastectomy provided histologically clear specimen margins are ensured.<sup>2,8</sup>

Core needle biopsy provides a pathological basis for pre-operative diagnosis of phyllodes tumor. This study was carried out at a tertiary cancer care centre to determine sensitivity of core needle biopsy in diagnosing benign, borderline and malignant phyllodes tumor. Core needle biopsy findings were used to predict accuracy in diagnosing the phyllodes tumor.

## METHOD

This is a retrospective study and carried out at a tertiary cancer centre during the period from January 2020 to December 2020. A total of one hundred twenty (n=120) clinically/ histologically proven patients of fibroadenoma and phyllodes tumor who underwent surgery during a period of twelve months between January 2020 to December 2020 were included in this study.

### *Ethical approval*

There were no interventions done on the patients. Data collected from medical record department. However informed consent was taken from the participants.

### *Study centre*

Study conducted at Savera cancer and multispeciality hospital, Patna.

### *Inclusion criteria*

Female patients between the age of 25 years and 80 years. Histologically confirmed cases of fibroadenoma and phyllodes tumor. Ability to understand and provide written informed consent were included.

### *Exclusion criteria*

Patients who are pregnant, breast feeding and not willing to sign informed consent document were excluded.

### *Statistical analysis*

Comprehensive data analysis was done.

The aim of this study was to analyze the sensitivity of CNB in the diagnosis of phyllodes tumours and to compare this to the sensitivity of other commonly performed investigations. All cases were reviewed for core needle biopsy results collected from their medical records. The clinicopathological characteristics of patients were documented from their clinical files or histopathological reports. Sensitivity and specificity of core biopsy was determined for phyllodes tumor. Excel sheet was used to assess the association between different variables. We reviewed the medical history, clinical follow-up data, and CNB diagnostic data from our medical record department. A diagnostic test was used to evaluate the sensitivity and specificity of CNB in diagnosing benign, borderline, and malignant phyllodes tumors. SPSS v22.0 software (IBM SPSS, NY, and USA) was used for all statistical analyses and calculations.

## RESULT

All of the study populations were women between the age groups of 32-70. In this study a total of 120 patients (n=120) histologically confirmed of fibroadenoma and phyllodes tumor were enrolled over a period of 12 months between January 2020 to December 2020.

Age group variable of female patients were categorized into 21-30 (n=11), 31-40 (n=17), 41-50 (n=36), 51-60 (n=49) and 61-70 (n=7). In our study majority of the cases were between the ages of 41-60 years.

Group 1, fibroadenoma showing the frequency 95 (75%), the (Odds ratio (OR)=2.26, 95% confidence interval (CI):

(0.46, 0.95),  $p < 0.023$  was not significant compared to control groups. Group 2, benign phyllodes tumor, showing the frequency 14 (11%), the (OR)=4.28, 95% CI: (2.36, 7.72),  $p < 0.001$  was significantly higher compared to control group. Group 3, borderline phyllodes tumor, showing the frequency 05 (4.10%), the OR=12.00, 95% CI: (4.77, 30.14),  $p < 0.001$  was significantly higher compared to control groups. Groups 4, malignant phyllodes tumor showing the frequency 11 (9.5%), the OR=5.20, 95% CI: (2.88, 10.50),  $p < 0.001$  was significantly higher compared to control groups.

Table 2 demonstrated the pathological findings of the patients diagnosed with CNB. Majority of the patients (n=76) were of fibroadenoma on CNB. Out of which histo-pathologically proven cases were Benign PT (n=4), borderline PT and Malignant PT cases were (n=0).

Sensitivity and specificity of benign, borderline and malignant phyllodes tumor.

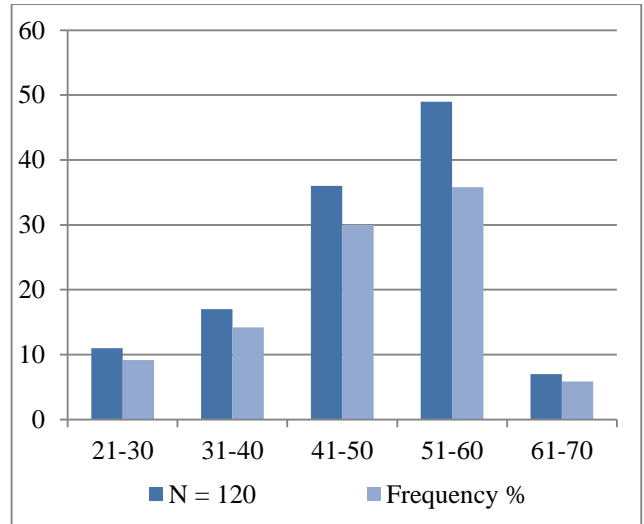


Figure 1: Illustrated the numbers of patients with age groups.

Table 2: Proportion of different types of breast lesions.

Lesion types	N (%)	95% at CI	OD	P value
Fibroadenoma	90 (75)	0.46 to 0.95	2.26	0.023
Benign phyllodes tumor	14 (11.66)	2.36 to 7.72	4.28	0.001
Borderline phyllodes tumor	5 (4.10)	4.77 to 30.14	12.00	0.001
Malignant phyllodes tumor	11 (9.5)	2.88 to 10.50	5.20	0.001

Table 3: Demonstrates the comparison between core biopsy and final biopsy.

Lesion types	No. of pts diagnosed with core biopsy	Final pathological diagnosis			
		Fibroadenoma	Benign PT	Borderline PT	Malignant PT
Fibroadenoma	80	76	4	0	0
Benign phylloes tumor	24	14	9	1	0
Bordeline phyllodes tumor	3	0	1	2	0
Malignant phyllodes tumor	13	0	0	2	11

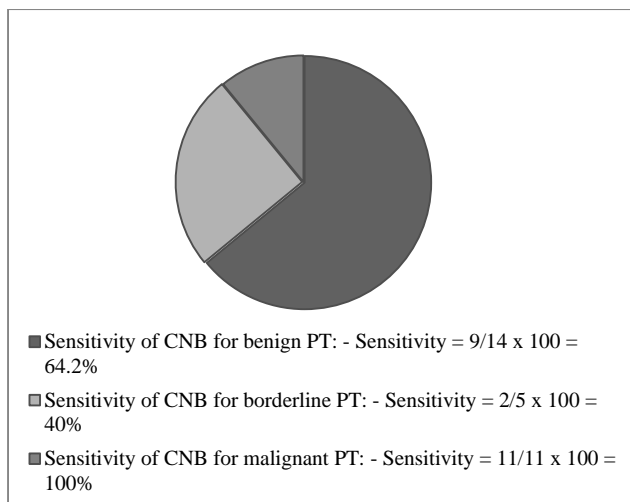


Figure 2: Sensitivity of benign, borderline and malignant tumors.

CNB=Core needle biopsy, PT=Phyllodes tumor. Sensitivity of CNB for PT-M is highest.

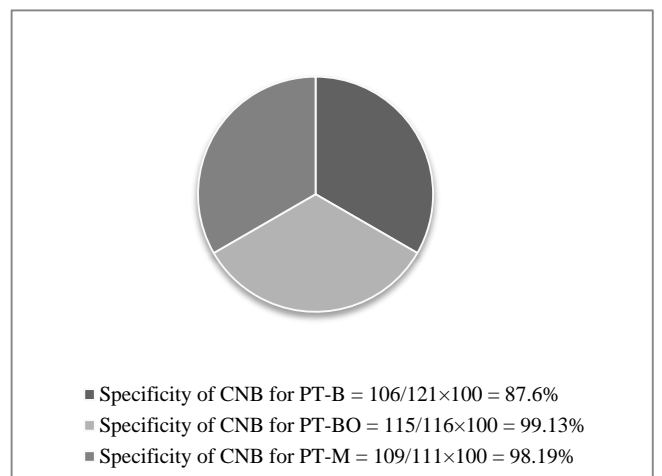


Figure 3: Specificity of benign, borderline and malignant phyllodes tumor

PT-B=Phyllodes tumor benign, PT-BO=Phyllodes tumor border line, PT-M=Phyllodes tumor malignant. Specificity of CNB for PT-BO is highest.

## DISCUSSION

Diagnostic accuracy of pre-operative core needle biopsy for phyllodes tumor is a matter of debate. Recent study has shown its usefulness over imaging but still with lower sensitivity and accuracy.<sup>9,10</sup> One hundred twenty patients (n=120) were enrolled in this study. Overall sensitivity of CNB in diagnosing phyllodes tumor was 75%. While sensitivity of benign PT, borderline PT and malignant PT was 64.2%, 40% and 100% respectively. It means CNB identified all malignant PT correctly while its accuracy decreased significantly in benign PT, borderline PT and malignant PT as 87.6%, 99.13% and 98.19% respectively. So, these results gave an impression that CNB used as a solo diagnostic tool for malignant PT, is promising but not for benign and borderline phyllodes tumor. Choi et al found sensitivity of CNB for benign, borderline and malignant phyllodes as 74.4%, 26.6% and 44.4%.<sup>11</sup> They called this discrepancy due to heterogenous nature and different sizes of tumors. Other studies also showed lesser sensitivity and comparable specificity for CNB in diagnosing phyllodes tumor.<sup>11-14</sup> Young et al found sensitivity of CNB as 67.9% while accuracy for benign and malignant PT was 82.1% and 5.8%.<sup>15</sup> Malignant tumors were rarely diagnosed as malignant by CNB in this study. This could not be explained by pathological stromal differentiation characteristics as malignant phyllodes uniquely present with stromal over growth and hypercellularity and high mitosis's  $\geq 10/HPF$ . Ward et al found sensitivity of core biopsy and imaging, 63% and 65% consecutively while 76% sensitivity for core biopsy and USG combined.<sup>16</sup>

In summary, CNB-derived data provides a pathological basis to assist the preoperative diagnosis of PTB. Because phyllodes tumors are characterized by elaborate histological features that are microscopically similar to other types of fibro epithelial lesions and fibroadenoma. CNB has a poor diagnostic performance and correspondingly limited clinical significance for PTB. An integrated approach involving clinical manifestations, imaging data and CNB pathology may be a more reliable strategy for the preoperative diagnosis of phyllodes tumor of the breast. Importantly, our data suggest that patients with positive CNB-based PTB results along with a surgical history of fibroadenoma and rapid tumor enlargement have a significantly increased likelihood of verifiable PTB.

### Limitations

Pathological differentiation of benign and borderline phyllodes tumor is sometimes very difficult. Proportion of borderline tumor is very less.

## CONCLUSION

Core needle biopsy in combination with clinical data and imaging features were suggested as a reliable strategy in the diagnosis of phyllodes tumor.

*Funding: No funding sources*

*Conflict of interest: None declared*

*Ethical approval: Not required*

## REFERENCES

- Rowell MD, Perry RR, Hsiu JG, Barranco SC. Phyllodes tumors. *Am J Surg.* 1993;165(3):376-9.
- Salvadori B, Cusumano F, Del Bo R. Surgical treatment of phyllodes tumors of the breast. *Cancer.* 1989;63(12):2532-6.
- Bernstein L, Deapen D, Ross RK. The descriptive epidemiology of malignant cystosarcoma phyllodes tumors of the breast. *Cancer.* 1993;71(10):3020-4.
- Rosen PP. *Rosen's Breast Pathology*, Lippincott William Wilkins, New York, NY, USA, 2<sup>nd</sup> edition. 2001.
- Ridgway PF, Jacklin RK, Ziprin P. Perioperative diagnosis of cystosarcoma phyllodes of the breast may be enhanced by MIB-1 index. *J Surgical Res.* 2004;122(1):83-8.
- El-Naggar AK, Mackay B, Sneige N, Batsakis JG. Stromal neoplasms of the breast: a comparative flow cytometric study. *J Surgical Oncol.* 1990;44(3):151-6.
- Jacklin RK, Ridgway PF, Ziprin P, Healy V, Hadjiminias D, Darzi A. Optimising preoperative diagnosis in phyllodes tumour of the breast. *J Clin Pathol.* 2006;59(5):454-9.
- Chaney AW, Pollack A, Marsha D. Primary treatment of cystosarcoma phyllodes of the breast. *Cancer.* 2000;89:1502-10.
- Hanby AM, Walker C, Tavassoli FA, Devilee P. *Pathology and Genetics: Tumours of the Breast and Female Genital Organs. WHO Classification of Tumours series-volume IV.* Lyon, France: IARC Press. *Breast Cancer Res.* 2004;6:133.
- Reinfuss M, Mituś J, Duda K, Stelmach A, Ryś J, Smolak K. The treatment and prognosis of patients with phyllodes tumor of the breast: an analysis of 170 cases. *Cancer.* 1996;77(5):910-6.
- Choi N, Kim K, Shin KH, Kim Y, Moon H, Park W et al. Malignant and borderline phyllodes tumors of the breast: a multicenter study of 362 patients (KROG 16-08). *Breast Cancer Res Treat.* 2018;171(2):335-44.
- Guerrero MA, Ballard BR, Grau AM. Malignant phyllodes tumor of the breast: review of the literature and case report of stromal overgrowth. *Surg Oncol.* 2003;12(1):27-37.
- Guillot E, Couturaud B, Reyat F, Curnier A, Ravinet J, Laé M et al. Management of Phyllodes Breast Tumors. *Breast J.* 2011;17(2):129-37.
- Kalambo M, Adrada BE, Adeyefa MM, Krishnamurthy S, Hess K, Carkaci S et al. Phyllodes Tumor of the Breast: Ultrasound-Pathology Correlation. *Am J Roentgenol.* 2018;210(4):W173-9.
- Young I, Choi SH, Moon HJ, Kim MJ, Kim E. Phyllodes Tumors of the Breast: Ultrasonographic

Findings and Diagnostic Performance of Ultrasound-Guided Core Needle Biopsy. *Ultrasound Med Biol.* 2013;39(6):987-92.

16. Ward ST, Jewkes A, Jones B, Chaudhri S, Hejmadi R, Ismail T et al. The sensitivity of needle core biopsy in combination with other investigations for the diagnosis of phyllodes tumours of the breast. *Int J Surg.* 2012;10(9):527-31.

**Cite this article as:** Singh VP, Singh AK, Jha AK, Sircar S, Singh VM, Verma PK, et al. Multiple core histopathologies for discriminative diagnosis of phyllodes pathology in breast. *Int Surg J* 2023;10:992-6.