

## Case Report

# Recurrent hydatid disease, a case report and literature review

Frances M. Lee\*, Rafael Gaszynski, Neil Merrett

Department of Upper GI Surgery, Bankstown-Lidcombe Hospital, Sydney, New South Wales, Australia

**Received:** 21 September 2021

**Revised:** 18 October 2021

**Accepted:** 02 December 2021

**\*Correspondence:**

Dr. Frances M. Lee,

E-mail: [fran.m.lee1@gmail.com](mailto:fran.m.lee1@gmail.com)

**Copyright:** © the author(s), publisher and licensee Medip Academy. This is an open-access article distributed under the terms of the Creative Commons Attribution Non-Commercial License, which permits unrestricted non-commercial use, distribution, and reproduction in any medium, provided the original work is properly cited.

### ABSTRACT

Hydatid disease (HD) remains endemic in Australia, with estimated incidence highest in rural and indigenous populations. Its recurrence is defined by new active cysts arising after appropriate therapy, and affects anywhere between 2-25% of total cases. Available treatment options include surgical resection, percutaneous drainage, and chemotherapy. Interestingly, their individual contributions to long-term minimisation of recurrence are scarcely described in the literature. We present a unique case of a 27-year-old female with recurrent hepatic HD requiring repeat operations and long-term chemotherapy. Prevention and treatment of recurrent HD requires careful evaluation of a multitude of factors, including disease characteristics, patient attributes, physician expertise and availability of resources. Consistent long-term follow up is required to better ascertain the long-term efficacy of reported treatment modalities for preventing recurrence. Despite a growing body of research looking at treatment of HD, there remains a considerable amount of controversy regarding most effective approach for minimising and preventing its recurrence.

**Keywords:** HD, Hydatid cyst, Hepatic HD, *Echinococcus*, Parasite

### INTRODUCTION

Hydatid disease (HD) is a cosmopolitan parasitic zoonosis caused by cestodes from the *Echinococcus* genus. It is endemic in certain regions (i.e., Mediterranean, China, Africa), with recent migration from middle east contributing to an increasing presence in non-endemic countries such as Europe.<sup>24,37</sup> In Australia, wildlife including dingoes and kangaroos provide important reservoirs for infection.<sup>17</sup> Incidence is highest in rural indigenous communities (5.5/100,000), with mean annual human prevalence in rural NSW estimated to 2.6/100,000 cases.<sup>16,18</sup> We present a unique case of recurrent hepatic HD in Australia, with objective highlighting factors contributing to recurrence that may aid understanding of its treatment and prevention.

### CASE REPORT

A 27-year-old woman presented to emergency with a three-day history of constant right upper quadrant pain.

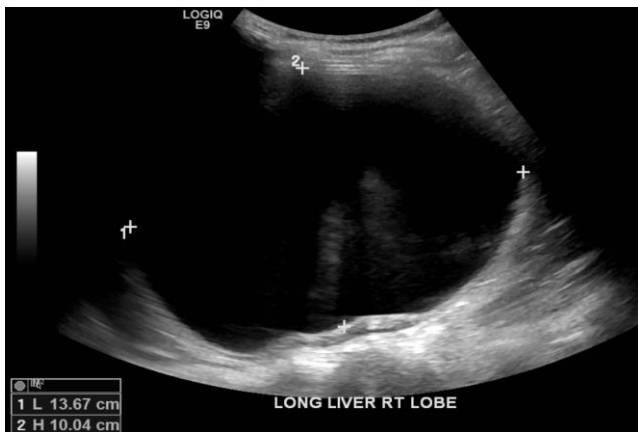She was a refugee from Iraq, with no remarkable past medical history. Her abdomen was soft with right upper quadrant tenderness, and no hepatomegaly or palpable masses.

Abdominal ultrasonography revealed an intact large cyst in the right lobe of the liver. Computed tomography abdomen showed a thin-walled cyst (12.8x11.7x13.4 cm) in the right liver lobe with no internal calcifications or septations. A simple hepatic cyst (14.9x11.2x13.1 cm) without associated mural calcifications, nodules or daughter cysts was demonstrated on follow-up magnetic resonance imaging of the abdomen. The 200 ml of serous fluid was drained on ultrasound-guided aspiration. Aspirated fluid culture was negative for HD, and the patient was discharged home.

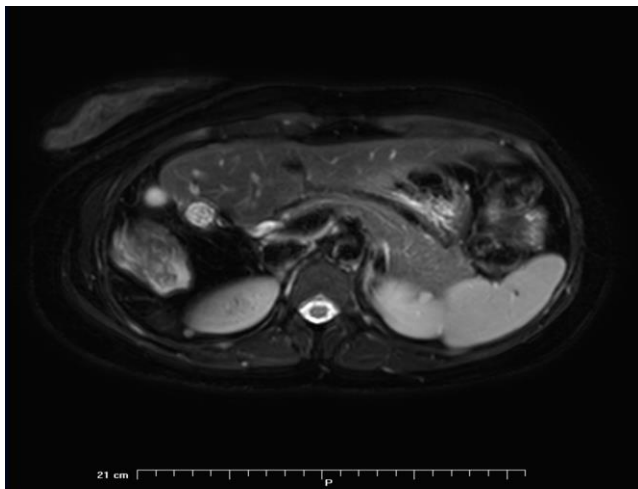
The patient re-presented four months later with worsening abdominal pain, chills and rigours. Abdominal ultrasonography confirmed recurrence, showing a large simple cyst (14x30x10 cm) (Figure 1). Magnetic

resonance cholangiopancreatography revealed a simple cyst with adherence to the gallbladder (Figure 2). Computed tomography was negative for extrahepatic spread. She underwent laparoscopic segmental liver resection of segments V+VI and cholecystectomy. Macroscopic inspection of the surgical specimens found a large cyst involving segments V+VI adjacent to the gallbladder (Figure 3). Histopathological assessment confirmed HD. Laparotomy for the remnant hydatid cyst was performed later that admission. The post-operative course was unremarkable and her *Echinococcus* antibody levels decreased. She was discharged on albendazole.

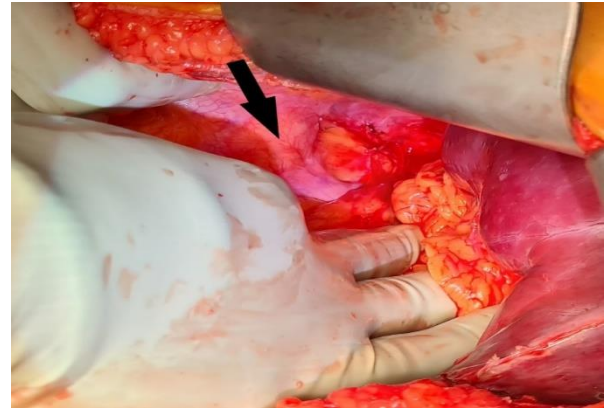
Three years later, she re-presented with similar symptoms. *Echinococcus* antibody levels notably increased from 80-160 (previous admission) to 2560. She underwent exploratory laparotomy and resection of hydatid cyst deposits, during which four cysts were removed from the liver, omentum, abdominal wall and perinephric regions (Figure 4). Her recovery was uneventful, and she was discharged on several months of albendazole.



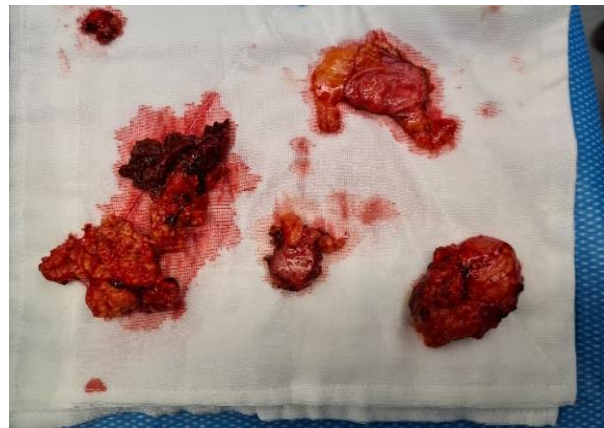**Figure 1: Abdominal ultrasonography of a large simple cyst.**



**Figure 2: MRCP demonstrating large cyst adjacent to the gallbladder.**



**Figure 3: Hydatid cyst adjacent to gallbladder.**



**Figure 4: Four cysts removed from the liver, omentum, abdominal wall and the perinephric regions.**

**Table 1: Gharbi and WHO-IGWE classifications of hydatid cysts.**

Gharbi classification	Lesion features
	Unilocular cyst
<b>Type I</b>	Pure fluid
<b>Type II</b>	Pure fluid with detached membrane
<b>Type III</b>	Multiple cysts within single cavity
<b>Type IV</b>	Semisolid heterogenous lesion
<b>Type V</b>	Solid lesion with thick-calcified wall

**Table 2: Predictors of recurrence after surgical treatment at 10-year follow-up as reported by El Malki et al.<sup>9</sup>**

Variables	Rate of recurrence (%)
<b>History of hepatic cysts</b>	18.3
<b>3+ cysts</b>	20.2
<b>Multiple cysts</b>	16.1
<b>Cysts with diameter &gt;10 cm</b>	12
<b>Extrahepatic cysts</b>	18.4
<b>Fibrotic or calcified pericysts</b>	11.2

**Table 3: Variables associated with recurrence in chemotherapy as reported by Franchi et al.<sup>12</sup>**

Variables	Rate of recurrence (%)
Daughter cysts (Type II)	55.2
Simple cysts (Type I)	30.6
Older age	86
<30 years of age	14
Cysts located in liver	33.9
Cysts located in lung	9.7
Treatment of relapsed cysts	90
Treatment of HD awaiting initial therapy	74.1

## DISCUSSION

Secondary infection occurs after consumption of food and water contaminated by canine faeces containing parasite eggs. Once ingested, the embryo is freed from the egg and can enter the portal vein by penetrating the duodenal mucosa. They can become lodged in the hepatic capillaries or elsewhere, and cystic development may occur.<sup>34</sup> Human infection is typically caused by *Echinococcus granulosus*, which can result in chronic growth of parasitic cysts frequently affecting the liver (52-77% of cases) and lungs.<sup>24,34,37</sup> The majority of cysts are asymptomatic. Others are slowly progressive and can present with symptoms related to expansion, involvement of adjacent structures, rupture, infection, anaphylaxis or extrahepatic growth.<sup>24,37</sup>

### Recurrence

Recurrent HD is the development of new active cysts after intra- and extra-hepatic disease treatment, with overall recurrence estimated to range between 2-25%.<sup>24</sup> It occurs after the incomplete removal of viable cysts and/or minute spillage during the original operation.<sup>35,39</sup>

Up until the 1980s, surgery was the only therapy available for treating HD. Modern chemotherapy and puncture of the cyst wall, aspiration of cyst content, instillation and re-aspiration of scolicedal agent (PAIR) technique have been introduced as adjuncts or sometimes replacements to surgery.<sup>31</sup> Although surgery is still the treatment of choice, the most effective approach for minimising recurrence and treating recurrence remains contentious.<sup>7,27</sup> Surgery is preferred in complicated cysts (rupture, compression of vital organs or vessels, haemorrhage, cysto-biliary fistulas, or secondary bacterial infection). In uncomplicated liver cysts, surgery is increasingly being replaced by alternative methods with potentially less complications.<sup>48</sup> This, however, is not based on trials with consistent long-term follow-up. Selecting the most appropriate treatment depends on cyst number, size, location, characteristics and complications. Sonographic classification of HD (Table 1) may aid evaluation of treatment efficacy and evolutionary stage of the parasite.<sup>27</sup>

## Surgery

The goals of surgical treatment are to obliterate scolices, prevent spillage, eliminate viable elements, and manage residual cystic cavities. There are two primary approaches-radical and conservative. Radical resection completely removes the cyst and pericyst with or without hepatic resection. Conservative procedures evacuate and sterilise cystic contents without pericyst removal. Where the cyst cavity is left behind, additional omentoplasty may reduce biliary fistula risk.<sup>33</sup> Either method is achievable via laparoscopic or open surgery. Current indications for surgery include: cysts >10 cm in diameter, multiple daughter vesicles, superficially-situated single liver cysts, secondary bacterial infection, and involvement of adjacent organs including biliary tree fistulisation.<sup>7,29</sup>

Advocates of radical resections claim that recurrence is reduced in comparison to conservative approaches. Its postoperative complication rate remains contentious.<sup>4,13,26,42</sup> A retrospective review (n=242) showed higher rates of relapse in conservative (3.2%) vs radical (24%) groups.<sup>4</sup> Conversely, another study (n=672) found similar recurrence in conservative (7.9%) and radical groups (11%) at 10-year follow-up.<sup>9</sup> They reiterated this finding in a later study (n=170; 1.7% vs 4%, respectively).<sup>10</sup>

Surgical advancements have led to increasing use of laparoscopic methods. Some are unconvinced about its effectiveness in preventing spillage because of possible technical limitations compromising complete evacuation of cystic contents and accessibility of some ectocysts.<sup>5,23</sup> Others have reported minimal recurrence from laparoscopy, and comparable recurrence rates to open procedures.<sup>11,15,49</sup> However, one must account for pre-selection bias and inconsistencies in laparoscopic techniques/modifications. Yagci et al reported higher recurrence in open (16.2%) vs laparoscopic (3.3%) and percutaneous (3.5%) groups. Notably, open surgery included both radical and conservative procedures, and laparoscopy was reserved for accessible types I-III cysts. Similarly, a later study used localisation (cysts not in hepatic segments 1 or 7) as an exclusion criterion for laparoscopy, finding no recurrence in either laparoscopic or open surgery groups.<sup>49</sup>

Strategies to prevent recurrence and spillage include packing the operative field with scolicedal-soaked sponges, using a cone affixed with dry ice, injecting scolicedal agents, and peri-operative chemotherapy.<sup>1,3,38,46</sup> Others have reported success with modified approaches including using a surgical suction cone<sup>41</sup>, direct trocar entry into hydatid cysts, and incorporating a liposuction device.<sup>2,5</sup> Lam and Merrett paired a 10 mm surgiport with strong suction from an open-ended suction-irrigator to facilitate decompression of hepatic hydatid cysts and introduction of a scolicedal agent.<sup>25</sup> No recurrence occurred at 3-year follow-up

(n=5). Bickel et al described a novel technique of using a large-bore suction catheter to promote drainage of cystic content into the apparatus rather than peritoneum.<sup>6</sup> They found no recurrence (n=32; mean follow-up: 49-months), but did note the limitations of minimally-invasive surgery. One case was converted to laparotomy due to an inaccessible 7x10 cm cyst between the liver and stomach. Another required delayed staged operation due to a large posteriorly-located cyst not amenable to treatment in one operation.

Indeed, localisation is important for deciding best surgical technique for relapse minimisation. Incomplete excision of the endocyst is often observed with difficult to access cysts, and can thus be an important cause of recurrence.<sup>14</sup> Tasev et al concluded that radical therapy reduced recurrence in a cohort (n=250) whose echinococcal cysts were more commonly in the left hepatic lobe. The majority of recurrences in a different cohort were in the previous localisation of posterior segments of the right hepatic lobe.<sup>26</sup> El Malki et al demonstrated higher recurrences in segments II±III (10.2%), IV±I (9.9%), and VII±VIII (9.6%).<sup>9</sup>

Other variables relevant to recurrence after surgery have been postulated (Table 2).<sup>10</sup> A retrospective study (n=391) concluded that the main predictive factors of recurrence were cysts >7cm, rural origin of patients, and unilocular hydatid cysts. They hypothesised that voluminous and unilocular cysts may relapse most often because of their immunogenic character and presence of exocysts within pericysts. This could be related to initial type of surgery.<sup>40</sup> Recurrent hydatid cysts may face increased difficulties during re-operations due to intra-abdominal adhesions increasing risk of spillage or incomplete removal.<sup>22,30</sup>

### ***Percutaneous drainage***

Successful percutaneous drainage (PAIR) of recurrent hydatid cysts was first reported by Mueller et al.<sup>31</sup> Some warn of a theoretical risk of anaphylaxis and dissemination resulting from laminated membranes and daughter cysts interfering with complete shrinkage.<sup>47</sup> Others claim that it is safe and effective in select cases, with recurrence ranging from 0-15%.<sup>19,20,21</sup> Ustunsoz et al theorised that suboptimal therapy may occur from endocyst irregularities creating pockets where viable cyst may avoid optimal contact time with hypertonic solution.<sup>19</sup> Daughter vesicles can develop in residual cyst cavities after PAIR.<sup>21</sup> Advances in percutaneous methods may have contributed to reduced reported recurrence. Saremi found no recurrence in patients who underwent percutaneous drainage using a Teflon 7-French catheter.<sup>36</sup> They claimed that simple drainage via the Seldinger method may increase leakage risk at the catheter's entry point, thus contributing to recurrence. Nayman et al proposed using a single puncture catheterisation technique for minimising recurrence (2.2%).<sup>32</sup>

### ***Chemotherapy***

Chemotherapy using benzimidazole compounds prevents recurrence by reducing the number of viable scolices. There are two antiparasitic agents commonly described- albendazole and mebendazole. Albendazole is the current drug of choice due to its superior absorptive capacity. They may be indicated in those: where surgery is contraindicated; with multiple peritoneal cysts; and as prophylaxis against recurrence from spillage during surgery or percutaneous drainage. It may be most effective in treating small cysts (<4 cm), thin walls, and younger patients.<sup>24</sup> Continuous or intermittent administration is recommended for up to 6 months.

Franchi et al assessed recurrence in patients undergoing 3- to 6-month continuous cycles of chemotherapy with albendazole (10-12 mg/kg/day) or mebendazole (50 mg/kg/day) (n=488).<sup>12</sup> Long-term results yielded similar recurrence rates between both groups (26.7% and 24.3%, respectively). They reported several factors associated with recurrence in chemotherapy (Table 3). Teggi et al demonstrated similar findings, however, they concluded that albendazole was more effective than mebendazole in treating liver cysts.<sup>44</sup> In hepatic HD, recurrence was greater in mebendazole (28.6%) than albendazole (15.4%) groups.

Chemotherapy adjunct to surgery or PAIR may further minimise relapse. A course of chemotherapy before surgery can help to sterilise cysts and reduce tension, whilst use afterwards can minimise recurrence risk. A case study randomised 72 patients into two groups- 1) surgery with no chemotherapy; 2) albendazole administered for 12-weeks pre- and 12-weeks post-operatively. Viable cysts were present in all patients from the former group at time of surgery, compared to 5.55% in the latter. Recurrence at 5-year follow-up was lower in those who received chemotherapy adjunct to surgery (0%) vs surgery alone (16.66%).<sup>38</sup>

Sufficient duration and timing of adjuvant chemotherapy with percutaneous or surgical therapies remains debatable. Akhan et al randomised 39 patients into 3 groups- A: PAIR alone; B: albendazole 1-week pre- and 1-month post-operation; C: albendazole 1-week pre- and 3-months post-operation.<sup>1</sup> All recurrence occurred in A (3.9%), with no statistical difference between B and C. There were, however, more side-effects in C. Another study similarly reported reduced recurrence in groups treated with albendazole both pre- and post-operatively (0%) compared to surgery alone (18.25%), albendazole for 8-weeks pre-operatively (6.25%) or 8-weeks post-operatively (6.25%).<sup>3</sup>

### ***Praziquantel***

Praziquantel is an iso-quinolone derivative that may prevent vesicular evolution of protoscolices and inhibit formation of secondary cysts. Some studies have shown

that combined praziquantel and albendazole therapy may be superior to albendazole or praziquantel alone at treating *Echinococcus* in humans and rodents.<sup>8,28,43</sup> However, these results are based on evaluation of radiological or serological evidence of cure and reduction in cystic size as opposed to relapse rates. Currently, there is insufficient evidence to support routine use of praziquantel with chemotherapy for minimising HD recurrence.

## CONCLUSION

Although HD is relatively unusual in the Australian setting today, the disease remains endemic and increased intake of middle eastern refugees has led to an increase in the numbers of cases seen. Relapse and extrahepatic dissemination occurred despite radical resection and post-operative prophylaxis with albendazole. Due to the slow-growing nature of HD, long-term follow-up will be required in order to determine treatment success. Ultimately, the most effective approach minimises recurrence, morbidity and mortality, and is tailored to each individual.

*Funding: No funding sources*

*Conflict of interest: None declared*

*Ethical approval: Not required*

## REFERENCES

1. Akhan O, Yildiz AE, Akinci D, Yildiz BD, Ciftci T. Is the Adjuvant Albendazole Treatment Really Needed with PAIR in the Management of Liver Hydatid Cysts? A Prospective, Randomized Trial with Short-Term Follow-Up Results. *Cardio Vascular Interventional Radiol.* 2014;37(6):1568-74.
2. Al-Shareef Z, Hamour OA, Al-Shlash S, Ahmed I, Mohamed AA. Laparoscopic treatment of hepatic hydatid cysts with a liposuction device. *J Society Laparoendoscopic Surg.* 2002;6(4):327-30.
3. Arif SH, Shams-ul-Bari, Wani NA, Zargar SA, Wani MA, Tabassum R et al. Albendazole as an adjuvant to the standard surgical management of hydatid cyst liver. *Int J surg.* 2008;6(6):448-51.
4. Unal A, Yazici P, Onen Z, Ozsoy M, Zeytinlu M, Kilic M, Coker A. The optimal treatment of hydatid cyst of the liver: Radical surgery with a significant reduced risk of occurrence. *Turk J Gastroenterol.* 2008;19(1):33-9.
5. Baskaran V, Patnaik, PK. Feasibility and safety of laparoscopic management of hydatid disease of the liver. *J Society Laparoendoscopic Surg.* 2004;8(4):359-63.
6. Bickel A, Loberant N, Singer-Jordan J, Goldfeld M, Daud G, Eitan A. The Laparoscopic Approach to Abdominal Hydatid Cysts. *Arch Surg.* 2001;136(7):789.
7. Brunetti E, Kern P, Vuitton DA. Expert consensus for the diagnosis and treatment of cystic and alveolar echinococcosis in humans. *Acta Tropica.* 2010;114(1):1-16.
8. Yarnoz C, Fraile S, Trujillo A, De-Liaño D, Ciga. Albendazole plus praziquantel versus albendazole alone as a pre-operative treatment in intra-abdominal hydatidosis caused by *Echinococcus granulosus*. *Trop Med Int Health.* 1998;3(6):462-6.
9. El Malki HO, El Mejdoubi Y, Souadka A, Zakri B, Mohsine R, Ifrine L et al. Does Primary Surgical Management of Liver Hydatid Cyst Influence Recurrence? *J Gastrointestinal Surg.* 2010;14(7):1121-7.
10. El Malki HO, Souadka A, Benkabbou A, Mohsine R, Ifrine L, Abouqal R et al. Radical versus conservative surgical treatment of liver hydatid cysts. *Bri J Surg.* 2014;101(6):669-75.
11. Ertem M. Laparoscopically Treated Liver Hydatid Cysts. *Arch Surg.* 2002;137(10):1170.
12. Franchi C, Vico B, Teggi A. Long-Term Evaluation of Patients with Hydatidosis Treated with Benzimidazole Carbamates. *Clin Infect Diseases.* 1999;29(2):304-9.
13. Gollackner B, Längle F, Auer H, Maier A, Mittlböck, M, Agstner I et al. Radical Surgical Therapy of Abdominal Cystic Hydatid Disease: Factors of Recurrence. *World J Surg.* 2000;24(6):717-21.
14. Haddad MC, Sammak BM, Al-Karawi M. Percutaneous treatment of heterogeneous predominantly solid echopattern echinococcal cysts of the liver. *Cardiovascular Interventional Radiol.* 2000;23(2):121-5.
15. Ibrahim I, Tuerdi M, Zou X, Wu Y, Yasen A, Abihan Y et al. Laparoscopic versus open surgery for hepatic cystic echinococcosis: a systematic review and meta-analysis. *Int J Clin Exp Med.* 2017;10(12):16788-97.
16. Jenkins KJ, Power K. Human hydatidosis in New South Wales and the Australian Capital Territory 1987-1992. *Med J Aust.* 1996;164(1):18-21.
17. Jenkins DJ, Macpherson CN. Transmission ecology of *Echinococcus* in wild-life in Australia and Africa. *Parasitology.* 2003;127:S63-72.
18. Jenkins DJ. Cystic Echinococcosis in Australia: The Current Situation. *Southeast Asian J Trop Med Public Health.* 2004;35(1):183-8.
19. Yagci G, Ustunsoz B, Kaymakcioglu N, Bozlar U, Gorgulu S, Simsek A et al. Results of Surgical, Laparoscopic, and Percutaneous Treatment for Hydatid Disease of the Liver: 10 Years' Experience with 355 Patients. *World J Surg.* 2005;29(12):1670-9.
20. Kabaalioglu A, ÇEken K, Alimoglu E, Apaydin A. Percutaneous imaging-guided treatment of hydatid liver cysts: Do long-term results make it a first choice? *Eur J Radiol.* 2006;59(1):65-73.
21. Kahrman G, Ozcan N, Dogan S, Karaborklu O. Percutaneous treatment of liver hydatid cysts in 190 patients: a retrospective study. *Acta Radiologica.* 2016;58(6):676-84.

22. Kapan M, Kapan S, Goksoy E, Perek S, Kol E. Postoperative Recurrence in Hepatic Hydatid Disease. *J Gastrointestinal Surg.* 2006;10(5):734-9.
23. Kathouda N, Hurwitz M, Gugenheim J, Mavor E, Mason RJ, Waldrep DJ et al. Laparoscopic Management of Benign Solid and Cystic Lesions of the Liver. *Ann Surg.* 1999;229(4):460-6.
24. Khuroo MS. Hydatid Disease: Current Status and Recent Advances. *Annals of Saudi Medicine.* 2002;22(1-2):56-64.
25. Lam VWT, Merrett ND. Drainage of hepatic hydatid cyst with a surgiport. *ANZ Journal of Surgery.* 2005;75(11):1022-3.
26. Magistrelli P. Surgical Treatment of Hydatid Disease of the Liver. *Archives of Surgery.* 1991;126(4):518.
27. Menezes Da Silva A. Hydatid cyst of the liver—criteria for the selection of appropriate treatment. *Acta Tropica.* 2003;85(2):237-42.
28. Mohamed AE, Yasawy MI, Al Karawi MA. Combined albendazole and praziquantel versus albendazole alone in the treatment of hydatid disease. *Hepato-gastroenterology.* 1998;45(23):1690-4.
29. Moro P, Schantz PM. Echinococcosis: a review. *Int J Infect Dis.* 2009;13(2):125-33.
30. Mottaghian H, Saidi F. Postoperative recurrence of hydatid disease. *Brit J Surg.* 1978;65(4):237-42.
31. Mueller PR, Dawson SL, Ferrucci JT, Nardi GL. Hepatic echinococcal cyst: successful percutaneous drainage. *Radiology.* 1985;155(3):627-8.
32. Nayman A, Guler I, Keskin S, Erdem TB, Borazan H, Kucukapan A, Ozbiner H, Batur A, Ertekin E, Feyzioglu B, Koc O, Kaya HE, Temizoz O, Kartal A, Ozbek O. A novel modified PAIR technique using a trocar catheter for percutaneous treatment of liver hydatid cysts: a six-year experience. *Diagnostic and interventional radiology (Ankara, Turkey).* 2016;22(1):47-51.
33. Papadimitriou J, Mandrekas A. The surgical treatment of hydatid disease of the liver. *Brit J Surg.* 1970;57(6):431-3.
34. Polat P, Kantarci M, Alper F, Suma S, Koruyucu MB, Okur A. Hydatid Disease from Head to Toe. *RadioGraphics.* 2003;23(2):475-94.
35. Prousalidis J, Kosmidis C, Anthimidis G, Kapoutzis K, Karamanlis E, Fachantidis E. Postoperative recurrence of cystic hydatidosis. *Can J Surg.* 2012;55(1):15-20.
36. Saremi F. Percutaneous drainage of hydatid cysts: use of a new cutting device to avoid leakage. *Am J Roentgenol.* 1992;158(1):83-5.
37. Sayek MD, I, Onat MDD. Diagnosis and Treatment of Uncomplicated Hydatid Cyst of the Liver. *World J Surg.* 2001;25(1):21-7.
38. Shams-Ul-Bari MA, Dass T, Arif S, Khaja A, Naikoo Z. Role of albendazole in the management of hydatid cyst liver. *Saudi J Gastroenterol.* 2011;17(5):343.
39. Sielaff TD, Taylor B, Langer B. Recurrence of Hydatid Disease. *World J Surg.* 2001;25(1):83-6.
40. Bedioui H, Bouslama K, Maghrebi H, Farah J, Ayari J, Hsairi H et al. Predictive factors of morbidity after surgical treatment of hepatic hydatid cyst. *Pan Afri med j.* 2012;13:29.
41. Aarons BJ, Kune GA. A suction cone to prevent spillage during hydatid surgery. *Aust N Zeal J Surg.* 2001;31(5):471-2.
42. Tasev V, Dimitrova V, Draganov K, Bulanov D, Popadiin N, Gaidarski R. Hepatic echinococcosis: radical or conservative surgical treatment. *Khirurgiia.* 2002;58(2):10-13.
43. Taylor DH, Morris DL. Combination chemotherapy is more effective in postspillage prophylaxis for hydatid disease than either albendazole or praziquantel alone. *Brit J Surg.* 1989;76(9):954.
44. Teggi A, Lastilla MG, De Rosa F. Therapy of human hydatid disease with mebendazole and albendazole. *Antimicrobial Agents Chemotherapy.* 1993;37(8):1679-84.
45. Ustünsöz B, Akhan O, Kamiloğlu MA, Somuncu I, Uğurel MS, Cetiner S. Percutaneous treatment of hydatid cysts of the liver: long-term results. *Am J Roentgenol.* 1999;172(1):91-6.
46. Velasco-Tirado V, Alonso-Sardón M, Lopez-Bernus A, Romero-Alegria A, Burguillo FJ, Muro A et al. Medical treatment of cystic echinococcosis: systematic review and meta-analysis. *BMC Infect Dis.* 2018;18:306.
47. Yaghan R, Heis H, Bani-Hani K, Matalka I, Shatanawi N, Gharaibeh K et al. Is fear of anaphylactic shock discouraging surgeons from more widely adopting percutaneous and laparoscopic techniques in the treatment of liver hydatid cyst? *Am J Surg.* 2004;187(4):533-7.
48. Junghans T, Menezes da Silva A, Horton J, Chiodini PL, Brunetti, E. Clinical management of cystic echinococcosis: state of the art, problems, and perspectives. *Am j trop med hygiene.* 2008;79(3):301-1.
49. Zaharie F, Bartos D, Mocan L, Zaharie R, Iancu C, Tomus C. Open or laparoscopic treatment for hydatid disease of the liver? A 10-year single-institution experience. *Surg Endoscopy.* 2013;27(6):2110-16.

**Cite this article as:** Lee FM, Gaszynski R, Merrett N. Recurrent hydatid disease, a case report and literature review. *Int Surg J* 2022;9:194-9.