

## Case Report

# Isolated jejunal necrosis following corrosive acid poisoning

Naveen Kumar Gaur, Oseen Hajilal Shaikh, Chellappa Vijayakumar,  
Uday Shamrao Kumbhar\*

Department of Surgery, JIPMER, Puducherry, India

**Received:** 13 September 2021

**Revised:** 08 October 2021

**Accepted:** 11 October 2021

**\*Correspondence:**

Dr. Uday Shamrao Kumbhar,

E-mail: k26uday74@yahoo.co.in

**Copyright:** © the author(s), publisher and licensee Medip Academy. This is an open-access article distributed under the terms of the Creative Commons Attribution Non-Commercial License, which permits unrestricted non-commercial use, distribution, and reproduction in any medium, provided the original work is properly cited.

### ABSTRACT

Corrosive acid poisoning is common in Asian countries, and most of the time, it is of suicidal intent in adults. Commonly they lead to extensive injuries of the upper gastrointestinal tract, and isolated involvement of the lower gastrointestinal tract is rare. We present a 35-year-old male who presented to us with a history of corrosive acid ingestion mixed with alcohol. Imaging did not demonstrate any pneumoperitoneum. The patient underwent exploratory laparotomy and found to have isolated jejunal necrosis without any evidence of injury to the stomach and duodenum. Segmental resection and end-to-end anastomosis were done.

**Keywords:** Acid ingestion, Necrosis, Jejunal necrosis, Jejunal resection, Corrosive poisoning

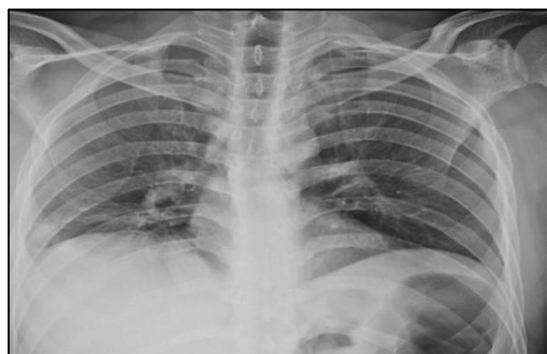### INTRODUCTION

Hydrochloric acid consumption, accidentally or for suicide, is more common in India than in Western countries.<sup>1</sup> Extensive injuries of the upper gastrointestinal tract can occur in patients who have consumed lethal amounts.<sup>1,2</sup> Isolated jejunal involvement is infrequent to occur. Patients usually present with abdominal pain, breathlessness, tachycardia, and vomiting.<sup>3</sup> Radiological investigations help to grade the severity of the injury. Surgical management is helpful in patients who are not stable. Here we present a rare case of suicidal corrosive acid injury in a young male who had isolated jejunal necrosis, managed with segmental jejunal resection.

### CASE REPORT

A 32-year-old male patient presented to us with pain abdomen and multiple episodes of vomiting from three days. The patient gave a history of acid ingestion of 20 to 30 ml mixed with 200 ml of alcohol and food with a suicidal intent four days back. The patient also had breathlessness, but there was no stridor. On examination, the patient was conscious, oriented, but dehydrated. The

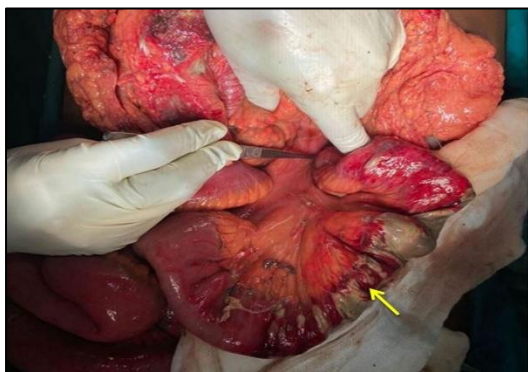
patient had a pulse rate of 130 beats per minute and a respiratory rate of 28 cycles per minute. The abdomen was distended, with diffuse tenderness, guarding, and rigidity. Bowel sounds were absent.



**Figure 1: Chest X-ray not showing any evidence of pneumoperitoneum or pneumomediastium.**

Emergency chest x-ray was done revealed no evidence of pneumoperitoneum or pneumomediastinum (Figure 1). Considering the instability and abdominal signs, the

patient underwent immediate laparotomy. Intraoperatively it was found that the stomach and duodenum were appearing normal. 10 cm from the duodenojejunal flexure, 40 cm segment of jejunum was gangrenous with a perforation within (Figure 2). Segmental resection of the jejunum with end-to-end anastomosis was done. However, patient expired after 48 hours of surgery due to septic shock.



**Figure 2: Intra-operative image showing full thickness jejunal necrosis (arrow).**

## DISCUSSION

Corrosive injuries of the upper gastrointestinal tract are frequently seen in developing countries like India.<sup>2</sup> It can be caused by acid or alkali ingestion. Suicidal attempts are common in adults. The extent of injury depends on the chemical consumed, mode of consumption, resistance to the mucosa. Suicidal ingestion of corrosive substances will have predominant oral, pharyngeal, and upper esophageal lesions, whereas accidental ingestion has predominant gastric injuries, although esophageal injuries may be associated.<sup>3</sup> Isolated involvement of the lower gastrointestinal tract is infrequent. In our patient, there was isolated jejunal necrosis with a normal-appearing stomach and duodenum. This may occur because the patient had consumed acid mixed with alcohol and food, which must have diluted the acid, leading to significant injury to the jejunum rather than stomach and esophagus. However, it has been reported that strong acids, when taken in considerable amounts, can lead to injury beyond the stomach, causing extensive necrosis of the small intestine and colon.<sup>4</sup>

The clinical outcome of corrosive ingestion depends upon the extent and depth of the initial injury. Injuries localized to mucosa will heal without any sequel. Injuries involving the submucosa or muscularis layer results in complications. Rarely perforations can occur when transmural injuries are present.<sup>4</sup> Patients may present with features of vomiting, pain abdomen, stridor, breathlessness, or hematemesis. Our patient had presented predominantly with pain abdomen and vomiting.

A chest x-ray may be an initial investigation to be done. It may show the presence of pneumoperitoneum or pneumomediastinum. Contrast esophagogram and computed tomography are helpful in grading severity. An endoscopy is crucial in assessing the grades of the severity of the injury.<sup>5</sup> In our patient, we did only a chest x-ray, as the patient was not stable. There was no evidence of pneumoperitoneum or pneumomediastinum.

The basic plan in managing corrosive acid injury patients includes fluid and electrolyte management, stabilization of the patient, broad-spectrum antibiotics, and timely surgical intervention.<sup>6</sup> A patient who has signs of peritonitis, evidence of perforation in the imaging studies, evidence of necrosis of the bowel should be explored immediately. Surgical management depends on the extent of the injury. There have been reports of esophagectomy, gastrectomy, pancreaticoduodenectomy, colectomy, and splenectomy were done in various combinations.<sup>7-10</sup> There has been a case report in the literature where patient had an isolated jejunal perforation following corrosive acid poisoning.<sup>3</sup> However, our patient had isolated jejunal necrosis without any other injuries. Our patient underwent jejunal resection with end-to-end anastomosis. However, patient expired due to systemic sepsis.

## CONCLUSION

Corrosive acid poisoning as a suicidal attempt is common in adults. Involvement of the upper gastrointestinal tract is common with; isolated involvement of the jejunum is very rare. Immediate surgical exploration is required in such patients. Adequate surgical treatment depends on the extent and grade of the injury. However, the prognosis may be dismal in these patients.

*Funding: No funding sources*

*Conflict of interest: None declared*

*Ethical approval: Not required*

## REFERENCES

1. Ananthakrishnan N, Parthasarathy G, Kate V. Acute corrosive injuries of the stomach: a single unit experience of thirty years. *ISRN Gastroenterol.* 2011;2011:914013.
2. Kalayarasan R, Ananthakrishnan N, Kate V. Corrosive Ingestion. *Indian J Crit Care Med.* 2019;23:S282-6.
3. Pankaja S, Valooran G, Das G, Suvasini L, Aravind S, Kate V et al. Isolated Full Thickness Jejunal Necrosis Following Sulphuric Acid Cocktail Ingestion – A Clinical Case Report—Isolated Corrosive Jejunal Necrosis. *Surgical Science.* 2011;338-40.
4. Contini S, Scarpignato C. Caustic injury of the upper gastrointestinal tract: a comprehensive review. *World J Gastroenterol.* 2013;19:3918-30.
5. Zargar SA, Kochhar R, Mehta S, Mehta SK. The role of fiberoptic endoscopy in the management of

- corrosive ingestion and modified endoscopic classification of burns. *GastrointestEndosc.* 1991;37:165-9.
6. Chirica M, Bonavina L, Kelly MD, Sarfati E, Cattan P. Caustic ingestion. *Lancet.* 2017;389:2041-52.
  7. Javed A, Pal S, Krishnan EK, Sahni P, Chattopadhyay TK.: Surgical management and outcomes of severe gastrointestinal injuries due to corrosive ingestion. *World J Gastrointest Surg.* 2012;4:121-5.
  8. Wu MH, Lai WW. Surgical management of extensive corrosive injuries of the alimentary tract. *Surg Gynecol Obstet.* 1993;177:12-6.
  9. Brun JG, Celerier M, Koskas F, Dubost C. Blunt thorax oesophageal stripping: an emergency procedure for caustic ingestion. *Br J Surg.* 1984;71:698-700.
  10. Bonavina L, Chirica M, Skrobic O, et al.: Foregut caustic injuries: Results of the world society of emergency surgery consensus conference. *World J Emerg Surg.* 2015;10:44.

**Cite this article as:** Gaur NK, Shaikh OH, Vijayakumar C, Kumbhar US. Isolated jejunal necrosis following corrosive acid poisoning. *Int Surg J* 2021;8:3457-9.