

Original Research Article

A study on clinical analysis and surgical outcomes of occipital encephalocele in children

Harisinh V. Parmar*, Nilay S. Adhvaryu, Jaimin K. Shah, Bhargav Trivedi, Milap Parmar

Department of Neurosurgery, B. J. Medical College, Gujarat University, Ahmedabad, Gujarat, India

Received: 12 September 2021

Revised: 19 September 2021

Accepted: 20 September 2021

*Correspondence:

Dr. Harisinh V. Parmar,

E-mail: impressario.hari@gmail.com

Copyright: © the author(s), publisher and licensee Medip Academy. This is an open-access article distributed under the terms of the Creative Commons Attribution Non-Commercial License, which permits unrestricted non-commercial use, distribution, and reproduction in any medium, provided the original work is properly cited.

ABSTRACT

Background: Occipital encephalocele is the commonest of encephalocele involving protrusion of meningeal and neural structures through the occipital bone defects. It is a congenital anomaly with varied presentation and can include only meninges to the cerebellum, medulla, venous sinus and brainstem structure.

Methods: Study was done at civil hospital Ahmedabad from January 2017 to January 2020 occipital encephalocele patients were operated at the department of neurosurgery. The patients were evaluated by computed tomography scan of the brain, magnetic resonance imaging and ultrasound. The operated cases were reviewed and relevant data such as age, sex, location of encephalocele, the size of the lesion, operative method, seizure and hydrocephalus along with postoperative complications were recorded for analysis.

Results: In our study, we have better results in contrast to literature may be due to absence of hydrocephalus, other anomalies of brain, seizure disorder and lack of functional brain tissue within the sac as these factors has been associated with poor neurological outcome. Out of 35 operated, 2 patients expired of which 1 patient had other complication at presentation and other one had had developed cerebrospinal fluid (CSF) leakage with ventriculitis.

Conclusions: Repair of encephaloceles should be ideally done in the postnatal period to minimize risks of ulceration and trauma to the lesion with subsequent meningitis. We can conclude that folic acid supplementation should be strongly emphasized in health centres to reduce these neural tube defects as none of the patients in our study has taken.

Keywords: Encephalocele, Crania bifida, Cranial dysraphism

INTRODUCTION

"Encephalocele" generally denotes a "cephalic hernia" through a congenital defect in skull (cranium bifidum). They represents 75–85% of the encephaloceles¹. It represents a congenital defect of cranium in which a portion of the central nervous system herniates through the defect. Based on the anatomic location of the skull defect. Encephalocele is far less common than spinal dysraphism. It is a serious congenital anomaly characterized by herniation of brain and meninges through a defect along the midline of the cranial vault or at the base of the skull.¹ The exact worldwide frequency is not known. It occurs in 1-4 cases per 10,000 live births.²

The primary abnormality in the development of an encephalocele is a mesodermal effect resulting in a defect in the calvarium and dura associated with herniation of cerebrospinal fluid (CSF), brain tissues and meninges through the defect. Commonest site of encephalocele is occipital (75%), followed by frontoethmoidal (13 to 15%), parietal (10 to 12%) or sphenoidal. Occipital encephalocele is common in western hemisphere whereas anterior encephaloceles are common in south east Asia.^{3,4} The two main groups are anterior and posterior encephaloceles. Posterior encephaloceles are divided into occipital, occipitocervical and parietal.⁵

The encephalocele is called occipito cervical fit occurred below the foramen magnum.⁶ Nager et al in his classification further divided the occipital encephalocele as superior/inferior based on the relation of the cranial defect to external occipital protuberance. When the defect in the skull is above external occipital protuberance, it is called superior and if below the pro-tuberance it is called inferior⁷.

The overall incidence of encephalocele is 0.8–3.0 per 10,000 births. They are 10 times less common than myelo meningoceles. They contribute to around 10% of craniospinal dysraphisms.⁸

The prevalence of encephalocele in the United States and Europe ranges from 0.4 to 4.3 per 10,000 births.^{9,10} In India, the prevalence varies from 0.3 to 1.5/1000 births.^{11,12}

Aims of study

This study aims at reviewing the pattern of presentation and the surgical outcome of patients operated and will give a general overview of the management of encephalocele and highlight the magnitude of this problem.

Objectives

The objectives of the research were: to study the age at presentation and repair of encephalocele over the study period; to study etiology and clinical presentation of encephalocele; to study the diagnostic methods used; to evaluate the surgical treatment of encephalocele; and to evaluate the post-operative outcomes in patients with occipital encephalocele.

METHODS

In our study 35 exclusively occipital encephalocele patients were conducted from January 2017 to January 2020 at the department of neurosurgery. The medical records of all the operated cases of occipital encephalocele cases are reviewed and relevant data such as age, sex, location of encephalocele, the size of the lesion, operative method, seizure and hydrocephalus along with postoperative complications were recorded for analysis. Patient with follow up were included in this study. The patients were evaluated by computed tomography scan of the brain, magnetic resonance imaging and ultrasound. Patients who developed complications and delayed milestones were regarded as no improvements in them and those who do not have any deficits and achieved the milestones were regarded as improvements. The Chi square test was used to determine statistical significance where (p value of <0.05 was taken as statistically significant).

Ethical aspects

Upon approval by the ethical and research committee of B. J. Medical College, the case notes were retrieved from the

record department and the research were carried out by author.

Study design

A descriptive retrospective and prospective was conducted from January 2017 to January 2020. The study population was all the patients with encephalocele seen at neurosurgery outpatient department (OPD) and ward of Civil Hospital, Ahmedabad during the study period that underwent surgery.

Inclusion criteria

All cases that were recorded as having encephaloceles and underwent surgical repair of the same, during the study period.

Exclusion criteria

The patients excluded from the study were: all those with encephaloceles who did not undergo surgical repair; and those with encephaloceles but were not operated within the study period.

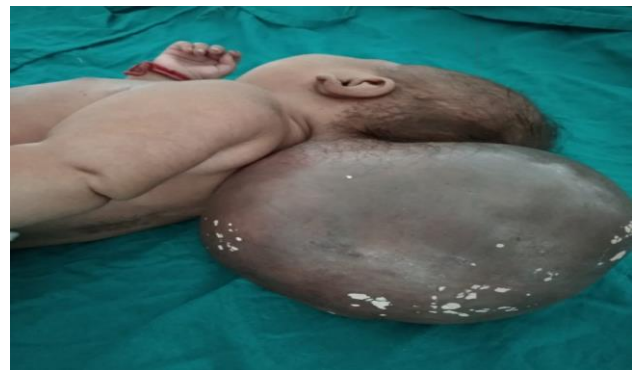

Figure 1: A large occipital encephalocele.

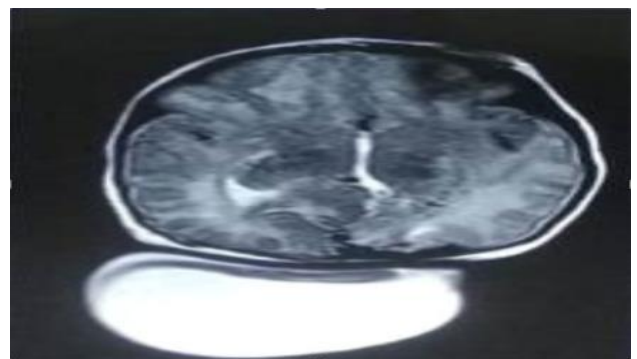


Figure 2: MRI identifies the defect.

Aim of surgery

Early repair in a patient fit to withstand the operation. Aims of the surgery are: exposure of the cranial defect through a planned approach; excision of herniated

dysplastic brain tissue; tension free repair of the dura; and repair of overlying soft tissues free of tension.

Complications

Common complications of these surgeries are hydrocephalus, hemorrhage, infections (wound infection, meningitis) and while ablation of occipital lobes in posterior encephaloceles almost inevitably leads to blindness, with subsequent neurological deficit or seizures.

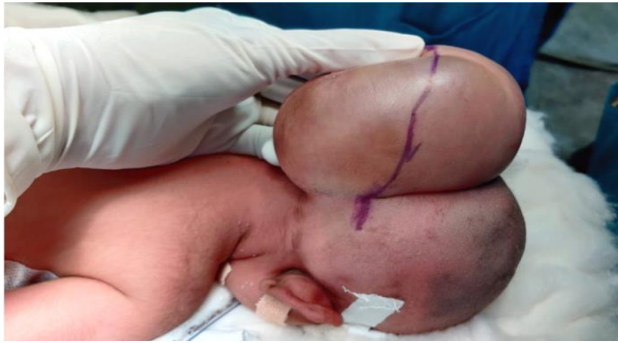

Figure 3: Position of the head in the surgery of occipital encephalocele.

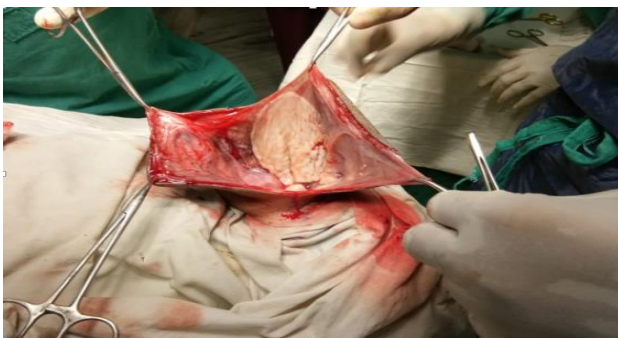

Figure 4: Identification of the sac.

RESULTS

The age of presentation was in the range of 1 day to 11 years, with median age of presentation was 6 months. Only 1 patient was having history of encephalocele in sibling.

By applying chi square test, the chi-square value is 7.196, degree of freedom is 1 with p value 0.007 which shows that complications were associated as per skin condition.

Table 1: Frequency of patients referred to our institute.

Referral centre	Frequency	Percentage (%)
District hospital	10	28.57
Private hospital	5	14.28
Health centre	7	20.00
Not referred	13	37.14
Total	35	100

Table 2: Findings on local examination of the swelling and post-op complications (n=35).

Findings on the swelling	Frequency (%)	Post-op complications	
		Yes	No
Ulcerated skin	3 (8.57)	2	1
Thin skin	14 (40)	6	8
Normal thickness skin	16 (45.71)	1	15
CSF leak with thin skin	2 (5.71)	1	1

Table 3: Associated conditions.

Conditions	No. of patients	Percentage
Hydrocephalus	7	20
Ventricular septal defect	1	2.85
Atrial septal defect	3	8.57
Patent foramen ovale	2	5.71
Arnold Chiari malformation	1	2.85
Neo-natal sepsis	1	2.85
Anemia	4	11.42
None	21	60

The average duration of hospital stay was in range of 1 to 35 days with median of 7 days.

Mortality

1 patient had non neurosurgical complications at presentation and other one had develop CSF leakage with ventriculitis. These patients died while undergoing treatment in the post-operative period. This prognosis depends largely on the presence of additional congenital anomalies of the brain and systemic manifestation.³

Table 4: Time intervals between repair and VP shunt surgery (n=35).

Time interval between main operation and shunt surgery (months)	Pre-operative shunt surgery (%)	Intra-operative shunt surgery (%)	Post-operative shunt surgery (%)
< 1	2 (5.71)	-	-
1-6	1 (2.85)	-	1 (2.85)
>6	-	-	-
Total	3 (8.57)	-	1 (2.85)

Table 5: Number of patients with complications following surgery in our study versus Wamae et al study.

Complication	Frequency (%)	
	Our study	Wamae et al study ¹⁴
None	25 (71.42)	40 (44.9)
Wound complication	8 (22.85)	17 (19.1)
CSF leakage	5 (14.28)	5 (5.6)
Hemorrhage	1 (2.85)	16 (18)
Hydrocephalus (post-op)	1 (2.85)	3 (3.4)
VP shunt blockage/infection	2 (2.35)	5 (5.6)
Seizures	2 (2.35)	2 (2.2)
Ventriculitis	1 (2.85)	2 (2.2)
Meningitis and local abscess	4 (11.42)	2 (2.2)

DISCUSSION

In our study none of the patients have taken folic acid supplementations before planning of pregnancy, nor did they underwent counseling.

Age/sex

In the study there were more females than males, with a ratio of 1.9:1. A higher proportion of females (65.72%) had occipital encephaloceles compared to males (34.28%). This pattern resembles that seen in Gujarat, India and over most parts of the world.¹³

It was noted in this study that most children were operated upon between the ages of 1 month to 6 months (25.71%).

Term

In this study 77.1% of the children were born at term pregnancy, 2.85% prematurely born while information on the duration of pregnancy was missing in 20%.

Caesarian sections were performed due to cephalo-pelvic disproportion in 3 mothers, due to macrocephaly in 2 patient and in one patient with fetal distress and oligohydroamnios. 28 patients (80.00%) were born by vaginal delivery, 6 (17.14%) through cesarean section and breech delivery 1 (1.1%).

In 34 (97.14%) patients there was no family history of encephaloceles. A positive family history of encephalocele was found in 1 (2.85%) patient.

Imaging

Among the imaging studies performed, magnetic resonance imaging (MRI) followed by computed tomography (CT) scan and ultrasonography (USG).

Ultrasonography was done in 12 patients (34.28%) and was the third imaging modality. Unfortunately in our study none of the patient underwent antenatal fetal USG due to various factors as poor socio-economic status, illiteracy, social belief, and lack of nearby facilities.

A/W congenital anomalies

It was found that 40% of the study cases had associated congenital malformation. There were no associated malformations in 21 (60%) patients. This high rate of associated conditions at presentation may be the explanation for the high rate (28.57%) of complications of surgery.

Wound complications

All of the patients in our study underwent primary skin closure, however common complications were sepsis, dehiscence, necrosis and ulceration with delayed healing. Wound complications were the commonest (22.85%), where as in study performed by Wamae et al study had 19.1%. The lowest complication rate was in the age 6-12 months (2.85%). The highest complication rate was in those younger than 1 month (11.47%, 4 patients) followed by those older than 1 year (8.57%, 3 patients).

Shunt insertion

In addition to repair of encephaloceles, 4 patients (11.42%) had surgery for insertion of VP shunts. This association may be as high as 50%.^{5,6} In 3 patients (8.57%) VP shunts were inserted up to 1 month before repair of encephalocele while 1 patient (2.85%) had them inserted within 1 month postoperatively. No patients had insertion of VP shunts at the same time as repair of encephalocele.

Post op stay and follow up

The average post-operative hospital stay was up to 14 days.

The longest follow up period was 3 years in 1 patient.

Probably most of the patients in our study having been referrals preferred to be followed up in hospitals near their home after surgery. As 2 patients expired, 33 patients were on regular follow up for 1 year then some of them prefer to referral hospital, nearby health center and private clinic. None of the patients who had excision of neural tissue in

this study were reported in their follow up to have any neurological complications. Those who required shunt also does not develop hydrocephalus or blockage or any shunt related complications. 2 of the patients operated between ages of 6-12 months developed delayed milestones in form of gross motor skill i.e. not able to stand with support till 2 years of age. Many patients defaulted from follow-up at discharge from the ward.

Limitations

Our sample size is small and short follow up period which can be a limitation of our study which should be considered before making any solid conclusion.

CONCLUSION

Encephaloceles are a common condition in this country. Most of the children with this condition are likely to have an associated congenital malformation. For occipital encephaloceles, where an infant is found to be fit for surgery, an early repair of the lesion may be done in the immediate postnatal period. This permits reasonable nursing and custodial care. Early repair also allows the facial skeleton to remodel with growth and improves cosmesis. Proper counseling and education of the parents on the condition (encephaloceles) with its complications is advisable and a follow-up of many years recommended. Folic acid supplementation should be given preconception to reduce this neural tube defects as none of patients in our study have taken. It should be strongly emphasize in health centers for counseling. Repair of encephaloceles should be ideally done in the postnatal period to permit reasonable nursing and minimize risks of ulceration and trauma to the lesion with subsequent meningitis. The average duration of hospital admission Compared to the post-operative hospital stay was too long implying there were delays in operating on patients who were already in the ward. Encephaloceles are commonly associated with hydrocephalus, which may be present before or after repair of the encephaloceles. The timing of VP shunting of these hydrocephalus may influence the outcome of repair of encephaloceles.

In our study, we have better results in contrast to literature may be due to absence of hydrocephalus, other anomalies of brain, seizure disorder and lack of functional brain tissue within the sac as these factors has been associated with poor neurological outcome.

Recommendations

As most of those operated are referrals, it is recommended that many doctors, nurses and other staff be trained, on how to manage this condition and be dispatched to the

peripheral hospitals at least at the level of tertiary care hospital.

Funding: No funding sources

Conflict of interest: None declared

Ethical approval: The study was approved by the Institutional Ethics Committee

REFERENCES

1. Siffel C, Wong L Y, Olney R S, Correa A Survival of infants diagnosed with Enecephalocele in Atlanta. *Pediatr Perinat Epidemiol.* 2003;17:40-8.
2. Lone MC. Congenital malformations of the central nervous system. *Clin Neurosurg.* 2000;47:346-77.
3. Mahapatra AK, Agrawal D. Anterior encephaloceles; a series of 103 cases over 32 years. *J Clin Neurosci.* 2006;13:536-9.
4. Hoving EW. Nasal encephaloceles. *Child's Nerv Syst.* 2000;16:702-6.
5. Saadi G. Encephalocele. Winn HR, editor. *Youmans Neurological Surgery.* 6th Edition. Philadelphia: Saunders. 2011;2:1898-905.
6. Simpson DA, David OJ. Cephaloceles: treatment, outcome and antenatal diagnosis. *Neuro-surgery.* 1984;15:14-21.
7. Nager GT. Cephaloceles. *Laryngoscope.* 1987;97(1):77-84.
8. Naidich TP, Altman NR, Braffman BH, McLone DG. Cephaloceles and related malformations. *Am J Neuroradiol.* 1992;13:655-90.
9. Parker SE, Mai CT, Canfield MA, Rickard R, Wang Y, Meyer RE, et al. Updated National Birth Prevalence estimates for selected birth defects in the United States, 2004-2006. *Birth Defects Res A Clin Mol Teratol.* 2010;88(12):1008-16.
10. Prevalence of neural tube defects in 20 regions of Europe and the impact of prenatal diagnosis, 1980-1986. EUROCAT Working Group. *J Epidemiol Community Health.* 1991;45(1):52-8.
11. Bhide P, Sagoo GS, Moorthie S, Burton H, Kar A. Systematic review of birth prevalence of neural tube defects in India. *Birth Defects Res A Clin Mol Teratol.* 2013;97(7):437-43.
12. Kandasamy V, Subramanian M, Rajilarajendran H, Ramanujam S, Saktivel S, Sivaanandam R. A study on the incidence of neural tube defects in a tertiary care hospital over a period of five years. *J Clin Diagn Res.* 2015;9(7):QC01-4.
13. Tubbs RS, Hogan E, Deep A, Mortazavi MM, Loukas M Oakes WJ. Lateral cephaloceles: case-based update. *Childs Nerv Syst.* 2011;27(3):345-7.
14. Wamae RN. A ten year retrospective study on encephaloceles as seen and managed at Kenyatta National Hospital (January 1992-December 2001). *University of Nairobi Research Archives.* 2009.

Cite this article as: Parmar HV, Adhvaryu NS, Shah JK, Trivedi B, Parmar M. A study on clinical analysis and surgical outcomes of occipital encephalocele in children. *Int Surg J* 2021;8:2946-50.