

## Case Series

# Tucked and treated- a case series on outcome of meshplasty with abdominoplasty for incisional hernia

Nagamallesh C. S.\*, Nandini S. Tanwar, F. Sadiq Nawaz, Padmanath Bhat

Department of General Surgery, Sapthagiri Institute of Medical Sciences and Research Centre, Karnataka, India

**Received:** 11 September 2021

**Accepted:** 06 October 2021

**\*Correspondence:**

Dr. Nagamallesh C. S.,

E-mail: [attitudemys95@gmail.com](mailto:attitudemys95@gmail.com)

**Copyright:** © the author(s), publisher and licensee Medip Academy. This is an open-access article distributed under the terms of the Creative Commons Attribution Non-Commercial License, which permits unrestricted non-commercial use, distribution, and reproduction in any medium, provided the original work is properly cited.

### ABSTRACT

Incisional hernia is the second most common type of hernia. Incisional hernia occurs in 10-20% of patients who were subjected to abdominal surgery in India. Here we are presenting a case series of 20 patients with incisional hernia and obesity. Body mass index (BMI) ranges from 28 to 35 in all cases. Females outnumbered the male in the ratio of 4:1 and 40% of cases had a previous history of caesarean section. All cases were operated by combining open polypropylene meshplasty and abdominoplasty techniques and follow up consultations were done for 1 year. 10% of cases had post-op wound infections, who were known to be diabetic. They were managed with appropriate antibiotics and maintained strict glycemic control. 90% of patients were satisfied from the procedure performed which improved their quality of life, significant cosmetic outcome and no recurrence. 10% of cases had recurrence after heavy weight lifting following surgery (BMI was 36). By incorporating the above mentioned techniques in hernia repair, recurrence rate and complications were reduced, quality of life and aesthetic outcome are enhanced.

**Keywords:** Incisional hernia, Obesity, Meshplasty, Abdominoplasty, Aesthetics

### INTRODUCTION

Incisional hernia is defined by the European Hernia Society (EHS) as “any abdominal wall gap with or without a bulge in the area of postoperative scar perceptible or palpable by clinical examination or imaging”.<sup>1</sup> It is the second most common type of hernia. The incidence of incisional hernia is exactly unknown globally.<sup>2</sup> Incisional hernia occurs in 10-20% of patients who had undergone abdominal surgeries.<sup>3</sup> The incidence seems to be less in smaller incisions than midline abdominal incisions till today.<sup>4</sup> The risk factors for the development of incisional hernia includes obesity, age, sex, smoking, emergency surgery, nutritional status of patient, chronic obstructive lung disease (COPD), diabetes mellitus, jaundice, malignancies, prostatism, corticosteroids, chronic constipation as well as heavy weight lifting.<sup>5</sup> Wound infection is seen as one of the most significant prognostic risk factors for development of an incisional hernia. Majority of incisional hernias presented within the first 12 months following

laparotomy. Long-term data indicate that at least one-third of these hernias will present 5–10 years postoperatively. After 5 years of surgery, incisional hernia is less likely. The patient with an incisional hernia may complain of a bulge in the abdominal wall which originates deep in the skin scar. Other symptoms include expansion of incisional hernia size on coughing, sneezing or straining, which causes discomfort and is considered as a cosmetic anxiety. On examination the hernia is usually easy to identify and the edges of the fascial defect can often be defined by palpation. The treatment of ventral incisional hernia is operative repair, and three general classes of operative repair have emerged in the modern era. These techniques include primary suture repair of the hernia, open repair of the hernia with prosthetic mesh and laparoscopic incisional hernia repair. The cumulative rates of recurrence among patients who had suture or mesh for repair of a primary hernia were documented as 43% and 24% respectively. The use of sheets of nonabsorbable prosthetic mesh placed across the incisional hernia defect and sutured to the abdominal

wall is routinely employed in the modern era. Incisional hernias are frequently associated with excess fat, laxity of abdominal muscles and deformity in shape of abdomen with hernia bulge and scars. Abdominoplasty is an aesthetic surgery chosen in patients who have suprapubic and infrapubic excess fat confined to the anterior aspect of the lower trunk. It involves removal of excess fat, tightening of lax abdominal muscles and augmenting the waist definition in some patients. It is usually seen in young women who have had one or two pregnancies, have good skin elasticity and are not overweight.<sup>6</sup> Here we are presenting a case series of 20 patients who underwent meshplasty and abdominoplasty for incisional hernia with android obesity.

## CASE SERIES

A series of 20 patients of incisional hernia admitted to the surgery ward of our hospital from July 2019 to May 2020 with the complaints mentioned in Table 2.

**Table 1: Distribution of patients according to gender.**

Gender	No. of patients	Percentage
Male	04	20
Female	16	80

**Table no 2: Distribution of patient according to clinical history.**

Clinical history	No of patients	Percentage
<b>Mode of presentation</b>		
Abdominal swelling only	14	70
Swelling with pain	06	30
<b>Duration of presentation in months</b>		
<6	02	10
6-12	08	40
12-18	06	30
18-24	02	10
24-30	01	5
30-36	01	5
<b>According to previous surgery</b>		
Caesarean section	08	40
Appendectomy	04	20
Cholecystectomy	02	10
Laporotomy	06	30
<b>According to risk factors</b>		
Obesity	13	65
Diabetes	05	25
Chronic respiratory illness	02	10

### General examination

General physical examination revealed patients with a mean blood pressure (BP) of 120/70 mmHg and pulse rate 86/min in 80% of patients. 20% of patients had a BP

ranged between 140/100 mmHg. Out of 20 patients, 40%, 45% and 15% of patients have BMI ranges between 28-30, 30-32 and 34-35 respectively.

Per abdomen examination revealed protruded abdominal wall, wide scar over lower abdomen, swelling in lower abdomen which appears on coughing that reduces completely on lying down. The skin over the swelling was stretched and thinned out. The diagnosis in place of which was confirmed by computed tomography (CT) abdomen in all cases.

### Preoperative investigations

Complete blood count (CBC), diabetic profile, lipid profile, coagulation profile, liver function test (LFT), renal function test (RFT), chest X-ray, electrocardiography (ECG) and abdominal ultrasound were carried out in all patients. The informed consent was obtained from all patients prior to surgery.

### Operative technique

Under general anesthesia, an incision is marked on the patient's natural suprapubic crease and angled toward the ASIS. Often the incision can be limited to the width of the pubic hair or just beyond its lateral edges. Intraoperatively, the proposed incision is made and the dissection extended to the muscle fascia. An abdominal flap is elevated superiorly to the level of the umbilicus without disturbing it. Here the hernial defect is identified and sac is then freed from the fascia in order to reduce the hernia contents and prevent recurrence and the hernial defect is repaired using prolene 1. Now, the anterior and posterior rectus sheath was split, followed by a placement of polypropylene mesh between posterior rectus and rectus muscle and fixed to underlying posterior rectus. The rectus sheath was closed using prolene 1. The abdominal flap was advanced inferiorly and tailored to remove the excess skin and underlying fat. This advancement will usually pull the umbilicus down 1 to 3 cm. The closure of this incision was performed in multiple layers, with the most important layer being the re-approximation of the superficial fascial system or Scarpa's fascia. Retro rectus and subcutaneous negative suction drain placement was done. Skin was closed with subcuticular suture using monofilament absorbable suture.

### Post-operative attention

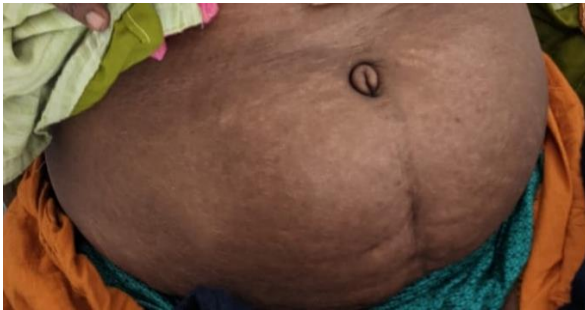Post-operative respiratory and leg exercises were done. Early ambulation was given to all patients between the first to third days of post-operative day. Antibiotics were administered post-operatively for 5 days. Drains were removed between 3<sup>rd</sup> to 5<sup>th</sup> post-operative days. Patients were advised to wear abdominal belts and to abstain from any strenuous physical activity for 5 months. The patients were instructed to consult the surgeon in case of any

abnormality found in the contour of abdominal wall following discharge.

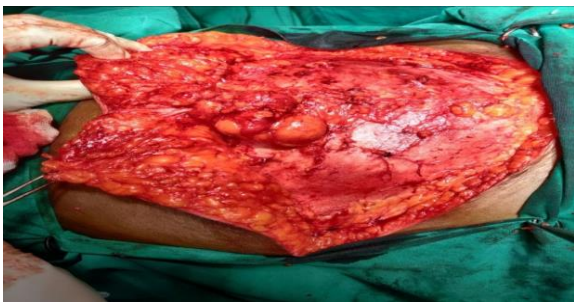**Table 3: Post-operative complications.**

S. no.	Abdominoplasty with mesh repair	Percentage
<b>Wound infection</b>	02	10
<b>Seroma</b>	03	15
<b>Wound dehiscence</b>	01	05
<b>No complications</b>	14	70
<b>Total</b>	20	100

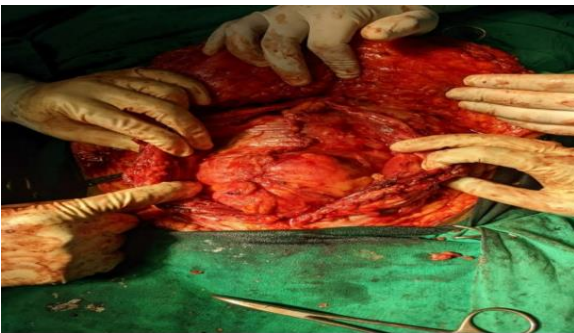The duration of follow-up was done for 1 year to assess the contour of abdomen and post-operative complications. Recurrence was not seen in 90% of cases.



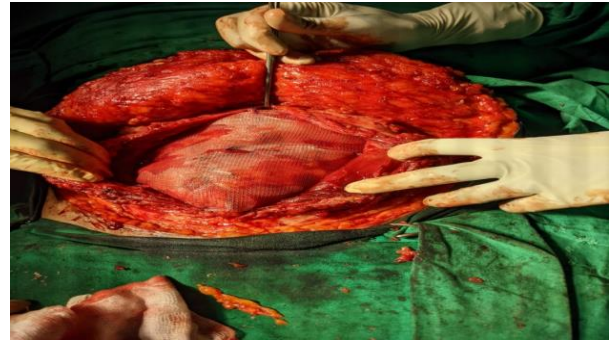
**Figure 1: Pre-operative front view of a 39-year-old lady.**



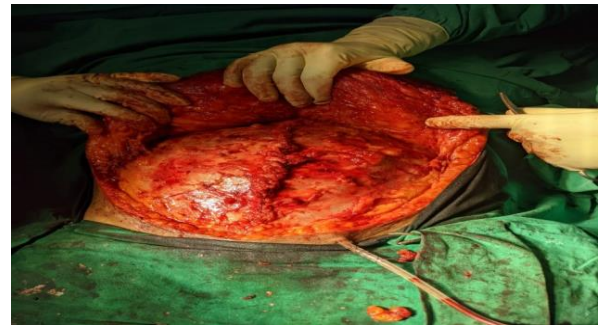**Figure 2: Dissecting the flap till the umbilicus showing the large sac with omentum as content.**



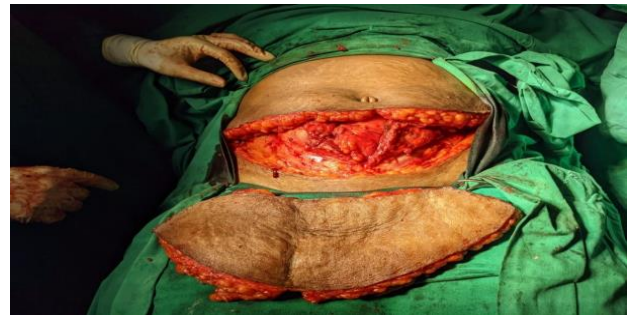**Figure 3: Rectorectus plane created for placement of mesh.**



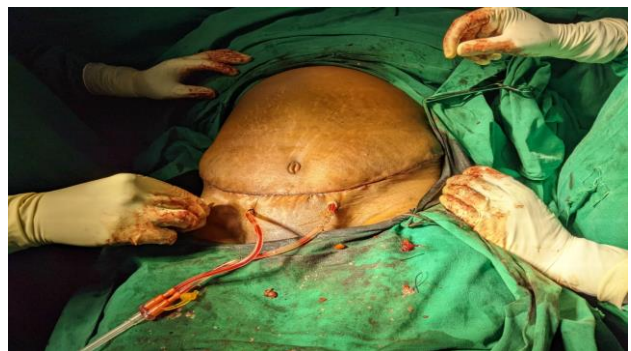**Figure 4: 30x30 polypropylene mesh placed in between posterior rectus sheath and abdominal muscle.**



**Figure 5: Closure of anterior rectus sheath and placement of drain.**



**Figure 6: The abdominal flap is advanced inferiorly and tailored to remove the excess skin and underlying fat.**



**Figure 7: Skin is closed with subcuticular suture after placing a drain.**



## DISCUSSION

The female to male ratio of incisional hernia in this study was found to be 4:1. Female outnumbered the male in the ratio 6:1 in a comprehensive study conducted on the incidence of incisional hernia female.<sup>10</sup> The age group of 30-50 years was found to have the highest incidence of incisional hernia. In the present study 80% and 20% of patients were in the age group of 30-54 years and 56-64 years respectively

A previous study reported 50% of patients who underwent caesarean section developed incisional hernias.<sup>7</sup> In our study, 40% of female patients had a previous history of lower segment caesarean section, 30% of patients had previous history of laparotomy, whereas patients with previous history of appendectomy and cholecystectomy contributing to 20% and 10% of cases respectively. In contrast to previous study which documented 6 to 15% of cases of incarceration in untreated incisional hernia as a complication, our study shows no such complications in the span of the previous 2 years.<sup>8</sup>

A study reported abdominal swelling was the most common (90.57%) presenting symptom.<sup>8</sup> In our study 70% of cases with abdominal swelling and 30% of cases with abdominal pain were reported. 60% of cases had BMI of more than 30 where as 40% of cases fell under the category of overweight with android obesity for which meshplasty with abdominoplasty was carried out in all patients. In obese patients with a suspected incisional hernia which cannot be confirmed on examination, CT abdomen is the best diagnostic tool for confirmation. In our study CT was done in all cases to know the size of the defect.

The operative procedure elaborated above was carried out in all patients under strict control of hypertension (HTN) and glycemic level who had these morbidities.

An article was published on the use of a vertical abdominoplasty technique and open hernia repair.<sup>9,10</sup> Here the surgery was open mesh repair and abdominoplasty. Some of the complications encountered are tabulated in Table 3 which were managed successfully. 10% of cases who had wound infection postoperatively were known diabetics. They were managed with strict glycemic control and appropriate antibiotics based on culture and sensitivity reports.

Rogmark et al conducted a randomized controlled trial (RCT) to compare open with laparoscopic incisional hernia repairs focused on quality of life preoperatively and 1 year after surgery.<sup>11</sup> In our study, 80% cases were satisfied from the procedure with improved quality of life and cosmetic outcome in one year follow up with no fresh complaints of hernia.

Here the procedure conducted involved the polypropylene mesh repair with abdominoplasty suction drain placement showed no recurrence in 90% of cases in one year follow up. 10% of cases who had recurrence was found to be involved in heavy weight lifting with BMI of 36.

## CONCLUSION

Incisional hernia is the second most common type of hernia. Here we are presenting a series of 20 patients with female to male ratio 4:1. 40% of cases had a previous history of caesarean section. The gold standard of repair is considered to be retrorectus mesh placement. All hernia patients who were overweight and obese underwent meshplasty with abdominoplasty. By incorporating these techniques in hernial repair, recurrence rate and complications are reduced, quality of life and aesthetic outcome are enhanced.

*Funding: No funding sources*

*Conflict of interest: None declared*

*Ethical approval: Not required*

## REFERENCES

1. Muysoms FE, Miserz M, Benevoet F, Campanelli G, Champault GG, Chelala E, et al. C of primary and incisional abdominal wall hernias. *Hernia*. 2009;13(4):407-14.
2. Dietz UA, Menzel S, Lock J, Wiegeling A. The Treatment of Incisional Hernia. *Deutsches Arzteblatt Int*. 2018;115(3):31-7.
3. Bucknall TE, Cox PJ, Ellis H. Burst abdomen and incisional hernia: A prospective study of 1129 major laparotomies. *British Medical J*. 1982;284:931-3.
4. Zinner MJ, Ashley SW. Maingot's abdominal operation. Abdominal wall Part II, 12th edition. The Mc graw-Hill companies. 1997;150.
5. Ellis H, Gajraj H, George CD. Incisional hernias when do they occur? *Br J Surg*. 1983;70:290
6. Thorne CH. Grabb and Smith's plastic surgery. Abdominoplasty and belt lipectomy. Chapter 66. 7th edition. Wolters Kluwer. 2015;689-91.
7. Malviya A, Patel A, Bhardwaj G, Bulchandani HP, Saini V. A comprehensive study on the incidence and management of incisional hernia. *Int Surg J*. 2017;4:2303-7.
8. Conze J, Klinge U, Schumpelick V. Narbenhernien [Incisional hernia]. *Chirurg*. 2005;76(9):897-909.
9. Cheesborough JE, Dumanian GA. Simultaneous prosthetic mesh abdominal wall reconstruction with abdominoplasty for ventral hernia and severe rectus diastasis repairs. *Plast Reconstr Surg*. 2015;135:268-76.
10. Shermak M. Hernia repair and abdominoplasty in gastric bypass patients. *Plast Reconstr Surg*. 2006;117:1145-50.
11. Rogmark P, Petersson U, Bringman S, Eklund A, Ezra E, Sevonius D, Smedberg S, Osterberg J,

Montgomery A. Short-term outcomes for open and laparoscopic midline incisional hernia repair: a randomized multicenter controlled trial: the ProLOVE (prospective randomized trial on open versus laparoscopic operation of ventral eventrations) trial. *Ann Surg.* 2013;258(1):37-45.

**Cite this article as:** Nagamallesh CS, Tanwar NS, Nawaz FS, Bhat P. Tucked and treated- a case series on outcome of meshplasty with abdominoplasty for incisional hernia. *Int Surg J* 2021;8:3421-5.