

Case Report

An unusual presentation of mycotic aneurysm of popliteal artery and the challenges faced: a case report

Obed Manuel Kuruvilla^{1*}, Arun Narayanapanicker², Anu Tresa Antony³

¹Department of General Surgery, Believers Church Medical College Hospital, Thiruvalla, Kerala, India

²Department of Cradiothoracic and Vascular Surgery, Pushpagiri Institute of Medical Sciences, Thiruvalla, Kerala, India

³Department of Pathology, Mahadevappa Rampure Medical College, Kalaburagi, Karnataka, India

Received: 27 October 2021

Accepted: 05 November 2021

*Correspondence:

Dr. Obed Manuel Kuruvilla,

E-mail: obedmanuel@gmail.com

Copyright: © the author(s), publisher and licensee Medip Academy. This is an open-access article distributed under the terms of the Creative Commons Attribution Non-Commercial License, which permits unrestricted non-commercial use, distribution, and reproduction in any medium, provided the original work is properly cited.

ABSTRACT

Mycotic aneurysm of popliteal artery is a very rare condition, most commonly caused by gram positive organisms. This term was coined by William Osler describing aneurysms associated with bacterial endocarditis. Though cases of peripheral vessel mycotic aneurysm are very rare, it is a dangerous condition as it can go for rupture/ thrombosis. The treatment of choice is resection and revascularization, preferably by using autologous vein graft along with antibiotics. A 35-year-old female who presented with features of cerebrovascular accident, during the course of stay was diagnosed to have mycotic aneurysm of the left popliteal artery. We describe the clinical course, investigation findings and challenges faced in management of the case.

Keywords: Mycotic aneurysm, Popliteal artery, Cerebrovascular accident, Thrombosis

INTRODUCTION

Mycotic aneurysms are most commonly found in the intracranial vessels and less commonly in the peripheral vessels.¹ This term was first used by William Osler describing aneurysms associated with bacterial endocarditis with an appearance of fresh fungal vegetation.² The term mycotic aneurysm is a misnomer as most are caused by bacteria. Mycotic aneurysm in the popliteal artery is a very rare condition, usually caused by gram positive organisms.³ We describe an unusual case with clinical presentation, imaging studies and challenges faced in the management of a patient, who had developed a mycotic aneurysm of popliteal artery.

CASE REPORT

A thirty-five year old female patient who was being treated at a local hospital presented to Pushpagiri Institute

of Medical Sciences, a tertiary care hospital in central Kerala with right hemiparesis.

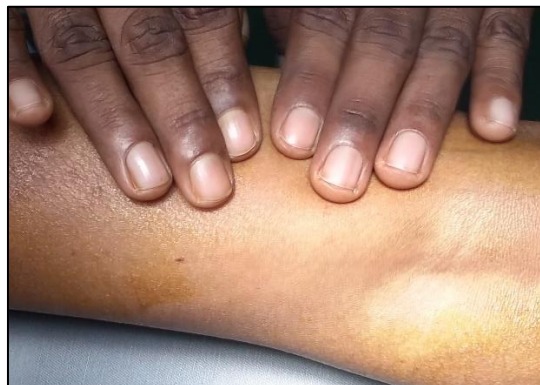

Figure 1: Pulsatile swelling due to popliteal aneurysm.

She had a history of recurrent low-grade fever of one month duration and weight loss. On examination she was found to have pallor, clubbing, left great toe splinter haemorrhage and a pansystolic murmur in the mitral region.

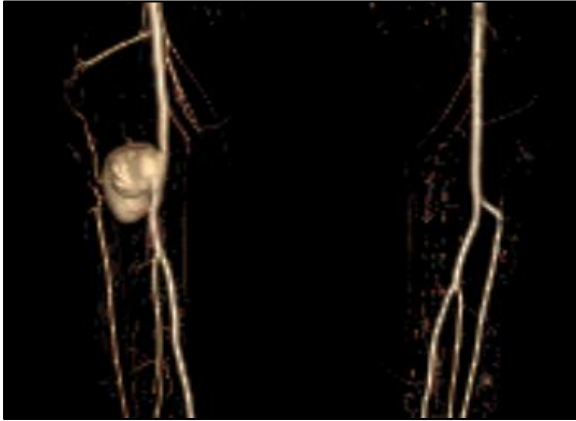


Figure 2: CT angiogram showing an aneurysm in the distal popliteal artery with the anterior tibial artery arising from aneurysm.

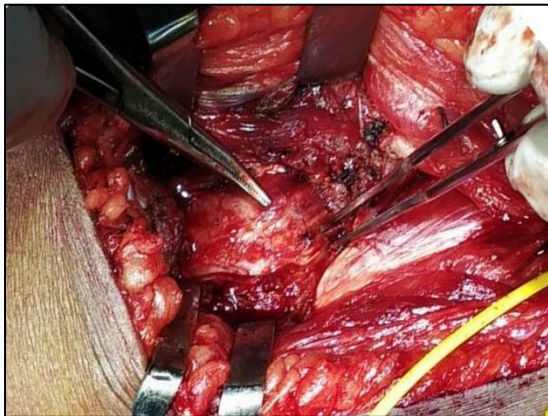

Figure 3: Intraoperative picture of the aneurysm.

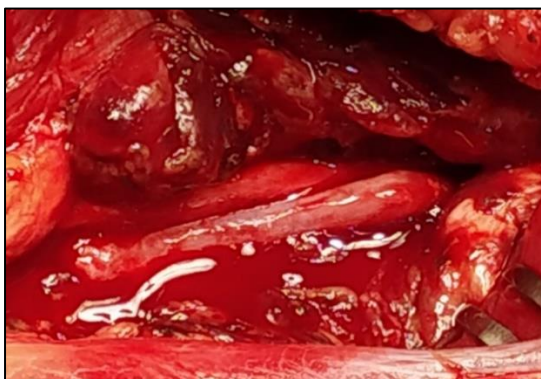

Figure 4: Revascularisation using reversed great saphenous vein graft.

Echocardiography revealed a vegetation 15×9 mm on anterior mitral leaflet and CT brain showed subacute

infarct with haemorrhagic transformation in the left frontal region which was diagnosed to be due to a septic embolus. Blood culture revealed *Streptococcus viridans* growth and was treated with intravenous antibiotics (ampicillin and gentamycin).

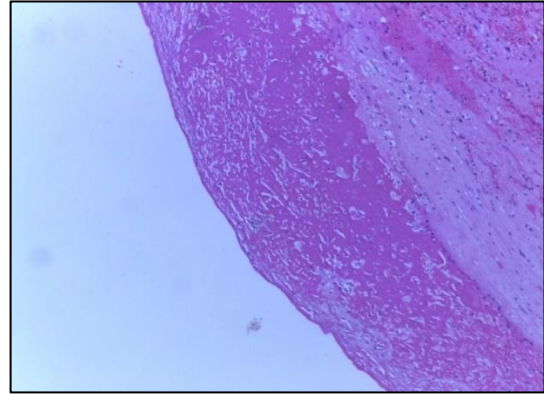


Figure 6: Histopathology study section. Intima was having coagulative necrosis and infiltration by polymorphs. There were areas of haemorrhage and foci of fibrinoid necrosis.

Patient showed improvement with treatment, having no further fever spikes and no residual neurological deficits. Two weeks later the patient started to complain of pain in the left leg and was found to have a tender pulsatile swelling in the left popliteal fossa. Investigations were carried out - arterial doppler showed an aneurysm in the popliteal artery. CT contrast angiogram was done which showed an aneurysm arising from the distal popliteal artery with the anterior tibial artery originating from the aneurysm. There was no evidence of thrombosis and there was good contrast opacification in the distal vessels. By the next day the pain increased markedly and on examination of the limb, distal pulses were absent. She was immediately taken up for surgery. On exploration there was a thrombosed aneurysm with necrotic tissue from distal popliteal artery till the origin of posterior tibial artery.

Debridement was done till viable vessel edges after attaining proximal control and specimen was sent for histopathological and microbiological assessment. Revascularisation was done with a reversed great saphenous vein graft taken from the opposite leg. After surgery, posterior tibial pulses were palpable and the patient symptomatically improved. Microbiological assessment showed no growth. Histopathology study showed intima having coagulative necrosis and infiltration by polymorphs. There were areas of haemorrhage and foci of fibrinoid necrosis.

The patient was started on physiotherapy and got ambulant, after a month patient underwent mitral valve replacement with 31 mm Saint Jude bileaflet mechanical valve.

DISCUSSION

Mycotic aneurysm is defined as an infected aneurysm developing in a previously normal artery secondary to septic embolisation due to bacterial endocarditis, or trauma. It is commonly caused by gram positive organisms, most commonly *Staphylococcus aureus* followed by *Streptococcus viridans*. It can also be caused by *Mycobacterium tuberculosis*, *Salmonella* species.⁴ Septic emboli are lodged in the lumen or vaso vasorum of peripheral arteries which leads to vessel wall infection and ischaemia resulting in destruction of tunica media and formation of mycotic aneurysm.⁵

Patients usually present with fever, leg pain and tender pulsatile leg swelling maybe noted. There maybe also features of thrombosis. These patients may also have neurological concomitant symptoms in the limb due to compression. Imaging studies like duplex USG and CT/MR angiography are used for diagnosis. The size and type of aneurysm can be assessed and complications like thrombosis, rupture can also be ruled out. Echocardiography should also be done for assessing source of embolus. Blood culture may reveal the causative organism in around 50% of cases.

Mycotic aneurysms require antibiotic care and requires resection and revascularisation. As the tissue is infected, prosthetic conduits are to be avoided. Great saphenous vein/ deep leg veins are used, former more preferred.^{6,7} This patient had CVA with haemorrhagic transformation and the aneurysm developed during the course of hospital stay. Using anticoagulants normally would risk an increase in intracerebral haemorrhage. Even though the aneurysm was thrombosed and there was acute limb ischemia, the anastomosis using reversed great saphenous vein had to be done with a gradual increase in anticoagulants to prevent neurological deterioration. The post surgical course was good, and her followup was uneventful.

CONCLUSION

Though mycotic aneurysm of the popliteal artery is a very rare condition, there is a high risk of rupture/thrombosis leading to limb ischaemia. Hence a

high index of suspicion is needed. Non-invasive investigations like USG arterial doppler and CT/ MR angiography aids in diagnosing the disease. The treatment of choice is resection and revascularization preferably by using autologous vein graft along with intravenous antibiotics.

Funding: No funding sources

Conflict of interest: None declared

Ethical approval: Not required

REFERENCES

1. Johnson JR, Ledgerwood AM, Lucas CE. Mycotic aneurysm. New concepts in therapy. Arch Surg. 1983;118(5):577-82.
2. Osler W. The Gulstonian Lectures, on malignant endocarditis. Br Med J. 1885;1:577-9.
3. Moneta GL, Taylor LM Jr, Yeager RA, Edwards JM, Nicoloff AD, McConnell DB et al. Surgical treatment of infected aortic aneurysm. Am J Surg. 1998;175(5):396-9.
4. Brown SL, Busuttill RW, Baker JD, Machleder HI, Moore WS, Barker WF. Bacteriologic and surgical determinants of survival in patients with mycotic aneurysms. J Vasc Surg. 1984;1(4):541-7.
5. Baddour LM, Wilson W, Bayer A, Fowler V, Tleyjeh I, Rybak MJ, et al. Infective endocarditis in adults: Diagnosis, antimicrobial therapy, and management of complications: A scientific statement for healthcare professionals from the American Heart Association. Circulation. 2015;132(15):1435-86.
6. Lajos P, Bangiyev R, Safir S, Weber T. Mycotic Popliteal Artery Aneurysm With Rapid Enlargement Post-Bypass. Cureus. 2021;13(6):e15746.
7. Flanigan DP. Aneurysms of the peripheral arteries. In: Moore WS, ed. Vascular Surgery: a Comprehensive Review. Philadelphia: W. B. Saunders Company. 1998:457-67.

Cite this article as: Kuruvilla OM, Narayanapanicker A, Antony AT. An unusual presentation of mycotic aneurysm of popliteal artery and the challenges faced: a case report. Int Surg J 2022;9:214-6.