

Case Report

Spontaneous rupture of bladder diverticulum: a case report of non-traumatic extraperitoneal urinary bladder rupture managed with surgical intervention

Lim Shiau Ping*

Department of General Surgery, Hospital Pakar Sultanah Fatimah, Muar, Johor, Malaysia

Received: 26 August 2021

Revised: 24 September 2021

Accepted: 14 October 2021

***Correspondence:**

Lim Shiau Ping,

E-mail: zoel7302@gmail.com

Copyright: © the author(s), publisher and licensee Medip Academy. This is an open-access article distributed under the terms of the Creative Commons Attribution Non-Commercial License, which permits unrestricted non-commercial use, distribution, and reproduction in any medium, provided the original work is properly cited.

ABSTRACT

Spontaneous extraperitoneal bladder rupture is a rare urology emergency. Most of the extraperitoneal urinary bladder rupture cases were management conservatively. To my best knowledge, there was very few reported about outcome of surgical management for spontaneous extraperitoneal urinary bladder rupture. Herein we shared our experience treating a 84 year old male who first presented with gross hematuria and frequent clots retention. Later he developed septic shock and peritonism which prompted us to do an urgent CT and found out the cause of his acute abdomen. The dilemma we faced to go in for operation was explained and patient had a turbulent post-operative time and he eventually succumbed to death due to various factors. Spontaneous extraperitoneal urinary bladder rupture is a rare cause of acute abdomen and prompt diagnosis and management can produce best clinical outcome.

Keywords: Non traumatic urinary bladder rupture, Spontaneous extraperitoneal bladder diverticulum rupture

INTRODUCTION

Spontaneous bladder rupture is a rare cause of acute abdomen and the reported incidence is 1:126000.¹ Signs and symptoms of spontaneous bladder rupture are non-specific and sometimes misleading and lead to delay in diagnosis and treatment and eventually unfavorable sequelae. The mortality rate associated with delay in diagnosis has been recorded as high as 25% for spontaneous bladder rupture.² Predisposing factors mentioned in previous studies included malignancy, previous bladder irradiation, neuropathic bladder dysfunction and acute overdistension secondary to alcohol intake.³ Conservative treatment with urinary bladder catheterization and antibiotics was the standard approach for extraperitoneal urinary bladder rupture. However, surgery approach was suggested in case of septicemia, formation of urinoma/abscess in extraperitoneal cavity, bladder neck injury.⁴

CASE REPORT

This was an 84 year old Malay male with underlying hypertension, diabetes mellitus, chronic kidney disease and gout (functional class II). He presented with hematuria on and off for 1 month, worsening for 2 days, suprapubic pain for 2 weeks but worsening for 2 days, dysuria for 3 months, constitutional symptoms for 3 months and lower urinary tract symptoms for 6 months (IPSS=28/35). Otherwise, patient had no fever, no other bleeding tendency, no anemic symptoms. Hematuria was not preceded by trauma/catheterization. Patient denied history of massage, taking any antiplatelet medication, traditional medication or radiation history for cancer treatment. Patient was a retired lorry driver and no history exposure to industrial chemical substances. He did not smoke cigarettes or drink alcohol. Family history was unremarkable. On examination, patient was not septic looking, GCS full, pink. Vital were stable. Per abdomen

was soft, tender over suprapubic region. Renal punch was negative. DRE prostate 4FB, median sulcus felt, no nodularity felt. 3 ways CBD was inserted and drained frank hematuria and thereby he was treated as hematuria secondary to BPH to rule out prostate carcinoma and started on bladder irrigation. In the ward, he had frequent episodes of clot retention and required frequent manual flushing. On day 2 of admission, patient developed hypotensive episodes and transiently responded to fluid resuscitation and eventually inotrope initiated. Serial ECG revealed no acute ischemic changes, cardiac enzyme was 155. Case referred to medical team and treated as anemia induced acute coronary syndrome.

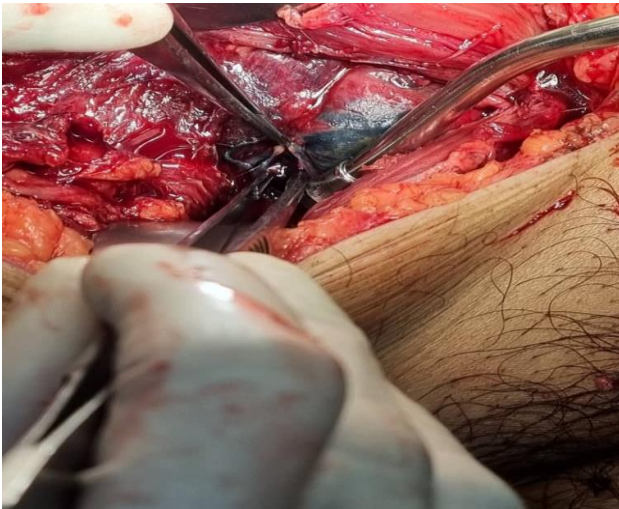

Figure 1: Methylene blue dye drained out from perforation site at the right lateral wall of extraperitoneal portion of the urinary bladder; thin segment of right lateral bladder wall raised possibility of a perforated bladder diverticulum.

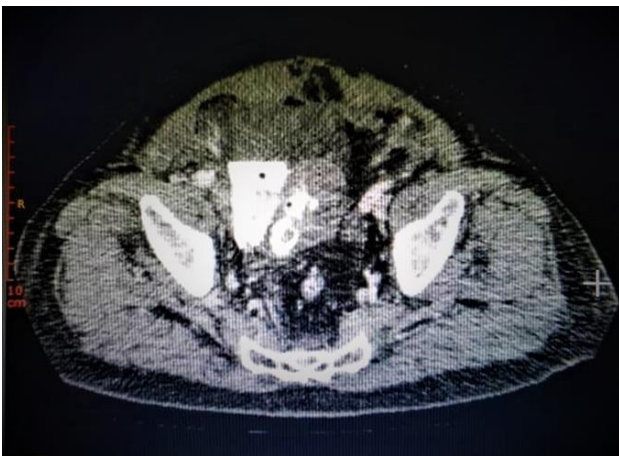


Figure 2: (Pre-operation CT imaging) contrast was pooled in the right hemipelvis; bladder wall defect noted measured 1.2 cm; hyperdensity within urinary bladder suggestive of hematoma.; multiloculated fluid collection with extensive air locules at suprapubic and lower abdomen (mainly at the extraperitoneal space).

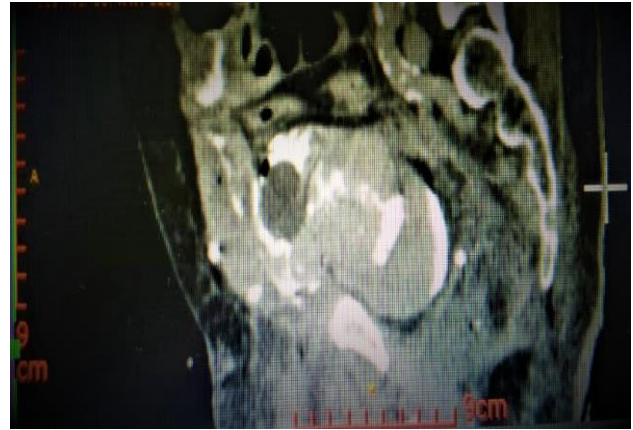


Figure 3: (Day 4 post operation CT imaging) contrast leak demonstrable from a defect measured 0.6 cm at right lateral wall of urinary bladder which was similar to the previously seen bladder defect; SPC's balloon seen outside the urinary bladder, located at perivesical space.

Despite on bladder irrigation and frequent manual bladder flushing, patient still had gross hematuria on day 3 of admission. Hb dropped from 11.5 to 8.4 g/dl within 3 days. Clinically, tender over lower abdomen and bladder distended. Urgent USG KUB was requested and planned for urology referral in view of persistent gross hematuria with frequent clots retention. Radiology team noted suspicious finding during ultrasound kidneys, ureters, bladder (USG KUB) and proceeded with contrast enhanced computed tomography abdomen pelvis (CECT AP). There was extravescical contrast leakage with multiloculated fluid collection in the pelvis with extension involve the lower abdomen wall muscles suggestive of extraperitoneal urinary bladder rupture. Case discussed with urologist consultant and patient was counselled for surgical intervention as patient was in septic shock due to extraperitoneal urinary bladder rupture. Exploratory laparotomy, urinary bladder repair and open SPC insertion done on 14 May 2021. Intraoperative findings showed perforation at the lateral wall of extraperitoneal portion of the urinary bladder, measured 2x2 cm with thin wall and jagged edges. Perforation site repaired in 2 layers. Urinary bladder was hard in consistency. At dome, filled with blood clots and partially removed from perforation site. 3 ways SPC (20Fr) was inserted. Minimal hemoserous fluid intraperitoneally. 3 ways Foley's catheter *in situ* (20Fr). GA team noted ECG changes (supraventricular tachycardia) upon completion of operation and resolved with IV amiodarone. Subsequently, he was transferred to ICU for post operation stabilization. In ICU, patient became oliguria (urine=0-20 cc/hour), hypothermia, hemodynamically supported, metabolic acidosis and worsening renal profile. Bedside USG KUB done on day 2 post operation showed no intraabdominal free fluid and unchanged left mild hydronephrosis and minimal separation of right pelviccalyceal system. Referred to nephrology team and SLED done on day 3 and day 5 post

operation. Later on, noted patient unable to tolerate enteral feeding, increased inotropic support, persistent anuria and distended abdomen. CECT abdomen/pelvic done on day 4 post operation showed right lateral bladder wall defect (0.6 cm) with extravascular contrast leak. Multiloculated intraperitoneal and extraperitoneal fluid collections in the abdomen and pelvis and bladder hematoma. SPC was seen outside the urinary bladder, bilateral mild obstructive uropathies, dilated small bowels with no transition zone likely paralytic ileus.

Patient's generally condition was ill due to overwhelming sepsis and his family decided to withdraw care and eventually he died on postoperative day 9.

DISCUSSION

Spontaneous urinary bladder rupture is a rare urological emergency.⁵ Prompt diagnosis possessed great challenge as the presenting symptoms were non-specific. Our patient first presented with persistent gross hematuria with frequent clots retention despite bladder irrigation and manual catheter flushing. At first, we did not think of spontaneous urinary bladder rupture. However, the clinical findings of patient in septic shock with peritonitis and worsening renal function heightened our suspicious and led to diagnostic imaging. To our surprise, his CECT abdomen revealed the cause of his dismay, extraperitoneal urinary bladder rupture.

Bladder rupture can be broadly classified into intraperitoneal or extraperitoneal depending on the defect location. It commonly occurred in the bladder dome which was the weakest point of the bladder wall, causing an intraperitoneal bladder rupture.^{6,7} Interestingly, in our case, the perforation site was located at the lateral wall and caused extraperitoneal bladder rupture. Common predisposing factors for spontaneous bladder rupture were associated with either increased intravesical pressure or decreased strength of the bladder wall or its combination.⁸

We hypothesized that it could be due to spontaneous rupture of bladder diverticulum. From the CECT AP, there was bilateral obstructive uropathy secondary to prostatomegaly (4.8×5.3×4.1 cm). Chronic bladder outlet obstruction could lead to formation of bladder diverticulum. Majority of bladder diverticula were small and asymptomatic. However, some patients may develop complications associated with inflammation, calculi, infections, large diverticular, urinary retention or malignancy. Patel et al reported in such bladder diverticulum-associated complications, rupture of a bladder diverticulum was rare and its early diagnosis was difficult.⁹ Chronic urinary stasis and poorly controlled bladder outlet symptoms causing the bladder diverticula to rupture spontaneously under high pressure voiding.¹⁰ This idea was supported by intraoperatively finding of perforated thin wall of bladder suggestive of perforated bladder diverticula.

Most extraperitoneal urinary bladder ruptures were treated conservatively with catheter drainage only. However, Patel et al had illustrated a similar case and pointing out that surgical approach may be required even in cases with extraperitoneal nontraumatic rupture due to the risk of uncontrolled sepsis.⁹ Similarly in this case, we were facing a patient in septic shock with concomitant large intravesical blood clots and frequently occluded urinary catheter causing inadequate drainage. Placing a SPC for him under local anesthesia deemed impossible. Thus, after discussion with urologist from tertiary center, we decided to go in for surgical repair of rupture urinary bladder with suprapubic catheter insertion. The perforation site was repaired in 2 layers and SPC inserted. Unfortunately, his condition continued to deteriorate post operatively and complicated with supraventricular tachycardia, renal shut down, persistent metabolic acidosis and worsening sepsis and eventually succumbed to death.

Retrospectively, we were looking at alternatives from studies which could have improve patient's clinical outcome. We were frustrated by the frequent urinary retention caused by intravesical blood clots in this case. Some authors had established novel technique in which hydrogen peroxide (H₂O₂) solution was applied in manual bladder irrigation to evacuate bladder clots.^{11,12} H₂O₂ maybe helpful in weakening adhesive property of blood clots and promoting clots disruption. The outcome was promising and follow up cystoscopy examination showed no abnormalities in the urinary bladder. This method might alleviate patient's distress but surgery approach was inevitable due to uncontrolled sepsis. On the other hand, Chih et al had used retrograde ureteral catheter insertion to bypass intravesical clots and drained out urine and patient recovered uneventfully.¹³ Evacuation of blood clot via cystoscopy was not a good idea as persistent bleeding and distension of urinary bladder during procedure may cause intraabdominal wall dissection and intractable pain. Percutaneous nephrostomy was reported as alternative for urine diversion in spontaneous bladder rupture cases. Unfortunately, limitation that we faced was we did not have urology subspecialty service in our center and other drainage methods were deemed impossible at the time.

CONCLUSION

Spontaneous urinary bladder rupture is a rare cause of acute abdomen. Patient who presented with hematuria, acute urinary retention, peritonitis, oliguria or acute kidney injury should raise high index of suspicion of spontaneous bladder rupture. Extraperitoneal bladder rupture with concomitant intravesical hematoma should be managed with surgical intervention. Early detection and appropriate management can produce best possible outcome.

ACKNOWLEDGEMENTS

The author acknowledges Dr. Ros'aini Binti Paijan, head of department of general surgery for her support in this case writing.

Funding: No funding sources

Conflict of interest: None declared

Ethical approval: Not required

REFERENCES

1. Peters PC. Intraperitoneal rupture of the bladder. Urol Clin North Am. 1989;16(2):279-82.
2. Bastable JRG, Jode LD, Warren RP. Spontaneous rupture of the bladder. Br J Urol. 1959;31(1):78-86.
3. Keeler LL, Sant GR. Spontaneous rupture of a bladder diverticulum. J Urol. 1990;143(2):349-51.
4. Sabat DK, Panigrahi PK, Sahoo RK, Acharya M, Sahu MC. Spontaneous puerperal extraperitoneal bladder wall rupture in young woman with diagnostic dilemma. J Fam Med Prim Care. 2015;4(4):601.
5. Sawalmeh H, Al-Ozaibi L, Hussein A, Al-Badri F. Spontaneous rupture of the urinary bladder (SRUB); a case report and review of literature. Int J Surg Case Rep. 2015;16:116-8.
6. Ibrahim A, Kallat A, Ziani I, ElSayegh H, Benslimane L, Nouini. Spontaneous intraperitoneal rupture of bladder diverticulum: a rare cause of peritonitis. Case Rep Urol. 2020;2020:8880748..
7. Itoh N, Kounami T. Spontaneous rupture of a bladder diverticulum: ultrasonographic diagnosis. J Urol. 1994;152(4):1206-7.
8. Mitchell T, Al-Hayek S, Patel B, Gilbert H. Acute abdomen caused by bladder rupture attributable to neurogenic bladder dysfunction following a stroke: a case report. J Med Case Rep. 2011;5(1):1-4.
9. Patel RI, Haas C, Spirnak JP, Erhardt C. Spontaneous extraperitoneal bladder rupture. J Urol. 1998;159(6):2089-90.
10. Kivlin D, Ross C, Lester K, Metro M, Ginsberg P. A case series of spontaneous rupture of the urinary bladder. Curr Urol. 2014;8(1):53-6.
11. Xu M, Jin L, Shan Y, Zhu J, Xue B. A simple and effective method for bladder blood clot evacuation using hydrogen peroxide. J Int Med Res. 2020;48(5):0300060520924546.
12. Bagheri M, Tahmasebi M, Najafi S, Rafsanjani ZJ. Using hydrogen peroxide as a bladder irrigation solution for clot evacuation. J Pharmaceut Care. 2015:79-81.
13. Fu CY, Shih CH, Chang PY, Hsiao CH, Wang YC, Chen RJ. Conservative treatment of concomitant extraperitoneal bladder rupture and intrablaadder blood clot formation: case report of application of ureteral catheterization. Canadian Urolog Assoc J. 2012;6(6):256.

Cite this article as: Ping LS. Spontaneous rupture of bladder diverticulum: a case report of non-traumatic extraperitoneal urinary bladder rupture managed with surgical intervention. Int Surg J 2021;8:3437-40.