

Original Research Article

Utility of pre-operative abdominal ultrasound to predict conversion to open cholecystectomy

Reetesh Sharma¹, Ramesh Dumbre¹, Arun Fernandes¹, Deepak Phalgune^{2*}

¹Department of Surgery, ²Department of Research, Poona Hospital and Research Centre, Pune, Maharashtra, India

Received: 16 August 2021

Accepted: 09 September 2021

*Correspondence:

Dr. Deepak Phalgune,

E-mail: dphalgune@gmail.com

Copyright: © the author(s), publisher and licensee Medip Academy. This is an open-access article distributed under the terms of the Creative Commons Attribution Non-Commercial License, which permits unrestricted non-commercial use, distribution, and reproduction in any medium, provided the original work is properly cited.

ABSTRACT

Background: Many factors like unclear Calot triangle anatomy, intensely inflamed and thick gallbladder, dense adhesions in the operative area, obscure biliary tree anatomy, local inflammation like pancreatitis contribute to the conversion of laparoscopic cholecystectomy to open cholecystectomy. The aim of the present study was to find the utility of abdomen sonography parameters that predict the conversion from laparoscopic to open cholecystectomy.

Methods: Ninety patients aged between 20 and 75 years with the diagnosis of cholelithiasis/cholecystitis were included in this observational study. Every patient underwent ultrasonography (USG). The USG findings such as gallbladder wall thickness, presence or absence of stones, number of calculi, size of the calculi, presence of abdominal adhesions, size of the common bile duct was recorded. If feasible, laparoscopic cholecystectomy was done. If not, the procedure was converted to open cholecystectomy. Association of USG findings was correlated with conversion to open cholecystectomy. The comparison of the qualitative variables was done using Fisher's exact test.

Results: Of 90 patients, 7 (7.8%) had a conversion to open cholecystectomy. There was no statistically significant difference of USG parameters studied such as gallbladder wall thickness >4 mm, pericholecystic fluid collection, common bile duct diameter >7 mm, presence of calculus, number of calculi, size of calculus >6 mm and adhesions/fibrosis in patients who required conversion to open cholecystectomy and who were operated laparoscopically.

Conclusions: Pre-operative USG parameters did not predict conversion to open cholecystectomy.

Keywords: Laparoscopic cholecystectomy, Open cholecystectomy, Ultrasonography

INTRODUCTION

Gallstone disease is a common problem affecting women more than men in the ratio of 4:1.¹ Obese, fertile and middle-aged females are more at risk. Autopsy reports have shown the prevalence of gallstones is 11% to 36% in the Central Indian population.² USG of the abdomen is an extremely useful and accurate method for identifying gallstones and pathologic changes in the gallbladder. It has a high specificity of >98% and sensitivity of >95% in diagnosing cholelithiasis.³ Laparoscopic cholecystectomy has rapidly become the procedure of choice for routine

gallbladder removal and is currently the most commonly performed major abdominal procedure worldwide.⁴

The revolution in laparoscopic surgery began three decades ago when laparoscopic cholecystectomy was introduced. It did not take long for a consensus to develop and for the national institute of health to pronounce laparoscopic cholecystectomy, as the procedure of choice for patients with symptomatic cholelithiasis.⁵ Retrospective data show that laparoscopic cholecystectomy is safe and effective when compared to open cholecystectomy. The advantages of laparoscopic cholecystectomy have been described as obvious and

compelling. Laparoscopic cholecystectomy reduces hospital stay, decreases morbidity, has a short recovery time and better cosmesis.⁶⁻⁹

In spite of the advances in technique, visualization and instrumentation in laparoscopy, there still are 1% to 13% of patients, who need an open procedure to complete the removal of the gallbladders during laparoscopic cholecystectomy.¹⁰ This happens because of many factors like unclear Calot triangle anatomy, intensely inflamed and thick gallbladder, dense adhesions in the operative area, obscure biliary tree anatomy, local inflammation like pancreatitis and others.¹¹ Since many of these factors cannot be determined clinically, a precise abdominal sonographic examination sheds light on various such conditions. A well-informed surgeon can then make appropriate choices of proceeding with laparoscopic cholecystectomy or offering elective open cholecystectomy in such patients.⁹ It will be useful to have some reliable predictive factors for difficulty in laparoscopy procedures. The aim of the present study was to find the utility of abdominal ultrasonographic parameters which can predict the conversion from laparoscopic to open cholecystectomy.

METHODS

This observational study was conducted between May 2020 and February 2021 in Poona hospital and research Centre, Pune, India. After approval from the scientific advisory committee (Letter No. RECH/SAC/2020-21/667), and institutional ethics committee (Letter No. IEC/2020/25), written informed consent was obtained from all the patients prior to enrollment. Patients were explained the risks and benefits of the procedure. Patients aged between 20 and 75 years with a diagnosis of cholelithiasis/cholecystitis were included. Patients with choledocholithiasis on USG, having co-morbid conditions like uncontrolled diabetes mellitus, uncontrolled hypertension, coagulopathies, chronic obstructive pulmonary disease, severe cardiac failure, jaundice, cholangitis, body mass index (BMI) >30 kg/m² and a history of upper abdomen surgery were excluded.

The data was collected by pre-tested study proforma, which included general information, clinical details of the patient and investigations. Every patient underwent USG. The USG findings such as gallbladder wall thickness, presence or absence of stones, number of calculi, the size of the calculi, presence of adhesions/fibrosis, pericholecystic fluid collection and common bile duct diameter was recorded. All the patients underwent diagnostic laparoscopy. If feasible, laparoscopic cholecystectomy was performed. If not, the procedure was converted to open. All patient's findings at laparoscopy were compared to USG findings and the reason for conversion in each patient was documented in detail. Association of USG findings was correlated with conversion to open cholecystectomy.

Pneumoperitoneum was created by insufflating the peritoneal cavity with CO₂ gas by using a veress needle inserted through the sub-umbilical port site. Electronic insufflators produced pneumoperitoneum to a pressure of 12-15 mm of Hg. A 10 mm trocar was inserted through the sub-umbilical incision using a rotatory movement and entry into the peritoneal cavity was confirmed. The telescope with the camera mounted was inserted through the cannula and initial diagnostic laparoscopy was carried out visualizing the gallbladder and abdominal viscera. The other three ports were inserted under vision.

The port in the epigastrium was a 10 mm cannula inserted just below the xiphisternum based on the inferior liver edge. This port was used for dissection of the Calot triangle, application of various clips, suction irrigation and for extraction of the gallbladder specimen. The port in the mid-clavicular line (5 mm) was inserted through a right sub-costal incision slightly lateral to the fundus of the gallbladder. This was used to pass a grasper to manipulate the gallbladder (body and neck) for dissection of the Calot triangle. The final port, another 5 mm cannula, was placed laterally in the anterior axillary line at the level of the umbilicus. This port was directed towards the fundus of the gallbladder and used for its retraction.

The patient was positioned in the reverse Trendelenburg position with a tilt to the left of approximately 30 degrees to the horizontal for better visualization of the gallbladder. A grasping forceps was inserted and the gallbladder fundus was held and pushed upwards and laterally towards the patient's right shoulder (superolateral). After the fundus of the gallbladder was retracted up and to the right over the liver using an atraumatic forceps, the further retraction was accomplished by a second atraumatic grasping forceps holding the gallbladder neck and retracting it laterally to expose the Calot triangle for achieving the critical view of safety (Figure 1). Once adhesions from neighboring structures were released from the gallbladder and peritoneal lining was taken down, gentle anterior and posterior dissection with straight and curved blunt dissector (Maryland forceps) was continued with alternating inferolateral and superomedial retraction of the neck until the gallbladder was dissected away from the liver, creating a "window" crossed by two structures: the cystic duct and artery. The cystic duct was skeletonized and exposed up to its junction with the common bile duct. Polymer clips were applied to the cystic duct and it was divided. The cystic artery was doubly clipped and divided similarly. The gallbladder was lifted from its bed, exposing the connective tissue between it and the liver. Using the grasping forceps, the gallbladder was held close to the area to be dissected and traction was maintained to expose the fibrous tissue, which was then divided by a diathermy hook. Thus, the gallbladder was gradually dissected until completely freed and placed on the surface of the liver for easy access. Extraction of the dissected gallbladder was done

through the epigastric port. The gallbladder extraction forceps were passed through the port and the neck of the gallbladder was grasped in the region of the previously applied cystic duct clips. The neck of the gallbladder was then gently maneuvered into the port and the port was slowly extracted from the abdomen. The gallbladder was externally held with artery forceps and opened externally while continuing a laparoscopic visualization of it. The suction cannula was inserted and gallbladder decompression was done. The gallbladder was then gradually removed. Once the specimen was extracted, the 10 mm epigastric port was placed back in position. If laparoscopic cholecystectomy was not possible, it was converted to open cholecystectomy (Figure 2).

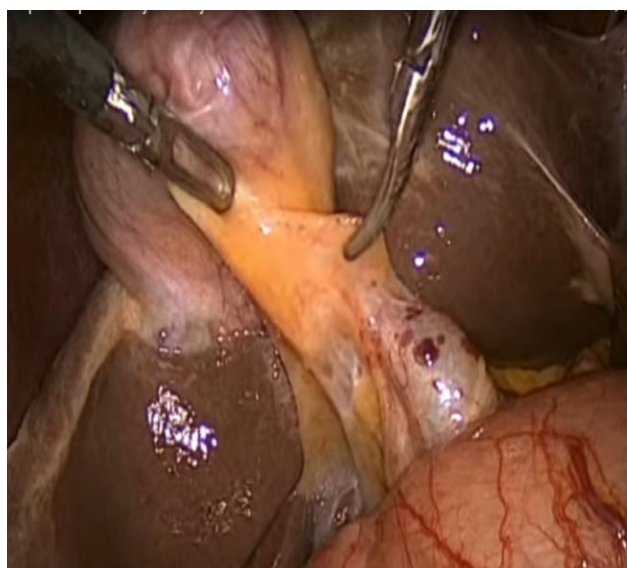


Figure 1: Dissection of Calot's triangle.

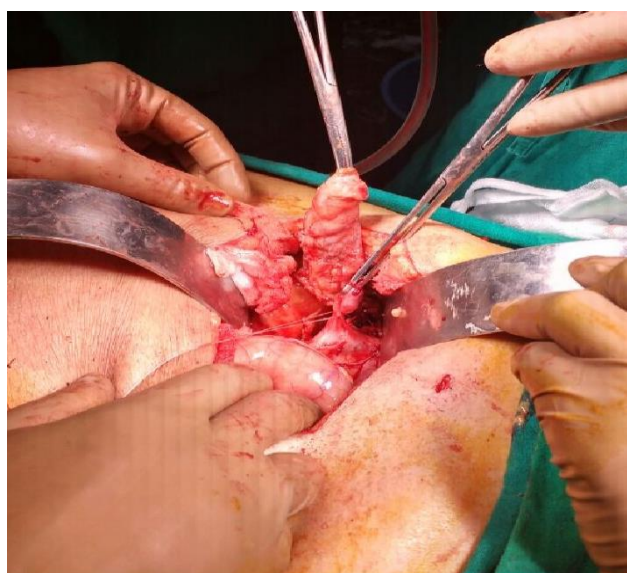

Figure 2: Conversion to open cholecystectomy.

The closure of 10 mm ports with 1-0 or 2-0 absorbable, synthetic, braided polyglactin 910 sutures (Vicryl) and

skin closure with 3-0 non-absorbable-synthetic-monofilament nylon sutures (Ethilon) were done. Pain relief was obtained by intravenous (IV) diclofenac or paracetamol injections. IV antibiotics were continued for 48-72 hours. Patients were ambulated on the first post-operative day and were discharged on the 3rd or 4th post-operative day in most of the cases.

The primary outcome measure was conversion to open cholecystectomy. On the basis of a previously published study, the sample size was calculated by formula $N = (Z\alpha)^2 p(1-p)/d^2$. We have taken $Z\alpha$ a standard normal variate at 5% type 1 error as 1.96.^{12,13} A total sample size of 85 patients was calculated by the above method. We included 90 patients to validate the results.

Statistical methods

Data collected were entered in excel 2007 and analysis of data was done using statistical package for social sciences for windows, version 20.0 from IBM corporation, Armonk, NY, USA. The data on categorical variables are shown as n (% of cases) and the data on continuous variables are presented as mean and standard deviation (SD). The comparison of qualitative variables was done using Fisher's exact test. The confidence limit for significance was fixed at a 95% level with a $p < 0.05$.

RESULTS

The present research was an observational study to find the utility of abdominal USG parameters which can predict the conversion from laparoscopic to open cholecystectomy. A total of 90 patients were included in the study. Of 90 patients, 7 (7.8 %) had a conversion to open cholecystectomy. There was no statistically significant difference between the two groups in relation to age groups and gender (Table 1). There was no statistically significant difference between the two groups in relation to abnormal gallbladder, presence and number of calculi, size of the calculus (>6 mm), gallbladder thickness (>4 mm), pericholecystic collection, adhesions/fibrosis and size of the common bile duct (Table 2).

Table 1: Baseline characteristics.

Variables	Conversion to open cholecystectomy, n (%)			P value
	Yes	No	Total	
Age group (years)				
≤30	1 (12.5)	7 (87.5)	8 (100)	0.962
>31-40	1 (8.3)	11 (91.7)	12 (100)	
41-50	2 (10.5)	17 (89.5)	19 (100)	
51-60	1 (5.0)	19 (95.0)	20 (100)	
61-70	1 (4.8)	20 (95.2)	21 (100)	
>70	1(10.0)	9 (90.0)	10 (100)	
Gender				
Male	5 (9.3)	49 (90.7)	54 (100)	0.698
Female	2 (5.6)	34 (94.4)	36 (100)	

Fisher's exact test was used

Table 2: Correlation of ultrasonographic findings of abdomen and conversion to open cholecystectomy.

Variables	Conversion to open cholecystectomy, n (%)			P value
	Yes	No	Total	
Gallbladder				
Normal	3 (4.8)	59 (95.2)	62 (100)	0.198
Abnormal	4 (14.3)	24 (85.7)	28 (100)	
Presence of calculus				
Yes	7 (7.9)	81 (92.1)	88 (100)	0.999
No	0 (0.0)	2 (100)	2 (100)	
No. of calculi				
No	0 (0.0)	2 (100)	2 (100)	0.839
1-2	0 (0.0)	7 (100)	7 (100)	
Multiple	7 (8.6)	74 (91.4)	81 (100)	
Size of the calculus (mm)				
Small (≤6)	2 (5.7)	33 (94.3)	35 (100)	0.765
Large (>6)	5 (9.4)	48 (90.6)	53 (100)	
Gallbladder wall thickness (mm)				
≤4	1 (4.2)	23 (95.8)	24 (100)	0.670
>4	6 (9.1)	60 (90.9)	66 (100)	
Peri-cholecystitis collection				
Present	3 (15.0)	17 (85.0)	20 (100)	0.181
Absent	4 (5.7)	66 (94.3)	70 (100)	
Adhesion/fibrosis				
Present	5 (5.9)	79 (94.1)	84 (100)	0.067
Absent	2 (33.3)	4 (66.7)	6 (100)	
Size of common bile duct (mm)				
Dilated (>7)	1 (9.1)	10 (90.9)	11 (100)	0.999
Normal	6 (7.6)	73 (92.4)	79 (100)	

Fisher's exact test was used

DISCUSSION

Laparoscopic cholecystectomy is the gold standard for symptomatic gallstones. The present study was conducted to evaluate some pre-operative abdominal USG findings, which can reliably predict the chances of conversion from laparoscopic cholecystectomy to open cholecystectomy. This will benefit patients because they can be informed of the possibility of laparoscopic difficulty and chances of conversion to an open procedure. In the present study, there was no statistically significant difference between the two groups in relation to abnormal gallbladder, presence and number of calculi, size of the calculus, gallbladder thickness, pericholecystic collection, adhesions/fibrosis and size of the common bile duct.

In the present study, the conversion rate to open cholecystectomy was 7.8%. Singh et al, Rosen et al, Sultan et al, Liu et al, Ishizaki et al and Nidoni et al reported that the conversion from laparoscopic cholecystectomy to open cholecystectomy was 19/255 (7.4%), 71 (5.3%), 234 (5.3%), 45/500 (9%), 7.5%, and 10/180 (5.6%) respectively which is similar to our study.^{2,11,14-17} Chindarkar et al, Ibrahim et al, Sikora et al, Lal et al and Yetkin et al reported that the conversion from laparoscopic cholecystectomy to open

cholecystectomy was 9/60 (15%), 103/1000 (10.3%), 29/150 (19%), 17/73 (13.3%) and 19/108 (17.6%) respectively which is higher than our study.^{12,18-21} Jansen et al reported conversion in 26/738 (3.5%) which is lower than our study.²²

In the present study, there was no significant correlation between gallbladder wall thicknesses > 4 mm with the conversion from laparoscopic cholecystectomy to open cholecystectomy. Rosen et al, Chindarkar et al, Stanisic et al, Liu et al, Ishizaki et al, Sikora et al, Daradkeh et al and Jansen et al reported a significant correlation between gallbladder wall thicknesses > 4 mm with the conversion from laparoscopic cholecystectomy to open cholecystectomy.^{11,12,15,16,19,22-24} In the present study, there was no significant correlation between the diameter of the common bile duct with the conversion from laparoscopic cholecystectomy to open cholecystectomy. Chindarkar et al, Daradkeh et al and Jansen et al reported a significant correlation between the diameter of the common bile duct with the conversion from laparoscopic cholecystectomy to open cholecystectomy.^{12,22,24}

In the present study, there was no significant correlation between the collection of the pericholecystic fluid with the conversion from laparoscopic cholecystectomy to open cholecystectomy. Rosen et al, Chindarkar et al, Stanisic et al, Nidoni et al and Yetkin et al reported a significant correlation between the collection of the pericholecystic fluid with conversion from laparoscopic cholecystectomy to open cholecystectomy.^{11,12,17,21,23}

In the present study, there was no significant correlation between the size of the calculus with the conversion from laparoscopic cholecystectomy to open cholecystectomy. Chindarkar et al, Stanisic et al and Jansen et al.^{12,22,23} reported a significant correlation between the size of the calculus with the conversion from laparoscopic cholecystectomy to open cholecystectomy.

In the present study, there was no significant correlation between adhesions/fibrosis with the conversion from laparoscopic cholecystectomy to open cholecystectomy. In the present study, of 90 patients, 84 patients had adhesion/ fibrosis of gallbladder. Of 84 patients, 5 (5.9 %) underwent conversion. Sultan et al and Daradkeh et al reported a significant correlation between adhesion/ fibrosis of gallbladder with conversion from laparoscopic cholecystectomy to open cholecystectomy.^{14,24} Daradkeh et al reported that to improve the predictability of operative difficulty of laparoscopic cholecystectomy, other nonultrasonographic factors must be included as independent variables, such as age, sex, BMI of the patient and the presence of adhesions.²⁴

Limitations

The study was conducted on a limited patient population hence these results cannot be extrapolated to a large population. Although USG is the best modality for the

diagnosis of gallstones, it is operator-dependent. A high level of skill and experience is needed to acquire good-quality images and make an accurate diagnosis. In the present study, although the USG of the abdomen was performed by a team of sonologists who were well experienced, some degree of deviation of the values of the USG parameters can be expected. The physique of the patient has a large influence on the image quality. The image quality and accuracy of diagnosis are limited with obese patients. Overlying subcutaneous fat attenuates the sound beam and a lower frequency transducer is required (with lower resolution) thus affecting the values considered. Gas in the abdomen distorts image quality. This can influence operator observations. Multicentric studies with a large sample size should be undertaken to substantiate the research findings described in this paper.

CONCLUSION

Of 90 patients, 7 (7.8%) had a conversion to open cholecystectomy. There was no statistically significant difference of USG parameters studied such as gallbladder wall thickness >4 mm, pericholecystic fluid collection, common bile duct diameter >7 mm, presence of calculus, number of calculi, size of calculus >6 mm and adhesions/fibrosis in patients who required conversion to open cholecystectomy and who were operated laparoscopically.

Funding: No funding sources

Conflict of interest: None declared

Ethical approval: The study was approved by the Institutional Ethics Committee

REFERENCES

- Brett M, Barker DJP. The World Distribution of Gallstones. *Int J Epidemiol.* 1976;5(4):335-41.
- Singh AP, Sharma P, Sajith Babu SM, Gaharwar APS. Predicting the conversion of laparoscopic to open cholecystectomy: an experience in a tertiary care hospital of central India. *Int Surg J.* 2016;3(4):1898-900.
- Tsai J, Sulkowski JP, Cooper JN, Mattei P, Deans KJ, Minneci PC. Sensitivity and predictive value of ultrasound in pediatric cholecystitis. *J Surg Res.* 2013;184(1):378-82.
- Litwin DEM, Cahan MA. Laparoscopic cholecystectomy. *Surg Clin North Am.* 2008;88(6):1295-313.
- Gollan JL, Kalser SC, Pitt HA, Strasberg SM. Foreword: Gallstones and laparoscopic cholecystectomy. *Am J Surg.* 1993;165(4):388-9.
- Begos DG, Modlin IM. Laparoscopic cholecystectomy: from gimmick to gold standard. *J Clin Gastroenterol.* 1994;19(4):325-30.
- Dubois F, Icard P, Berthelot G, Levard H. Coelioscopic cholecystectomy. Preliminary report of 36 cases. *Ann Surg.* 1990;211(1):60-2.
- Lichten JB, Reid JJ, Zahalsky MP, Friedman RL. Laparoscopic cholecystectomy in the new millennium. *Surg Endosc.* 2001;15(8):867-72.
- Macintyre IMC, Wilson RG. Laparoscopic cholecystectomy. *Br J Surg.* 1993;80(5):552-9.
- Kim JYS, Khavanin N, Rambachan A, McCarthy RJ, Mlodinow AS, De Oliveria Jr GS et al. Surgical duration and risk of venous thromboembolism. *JAMA Surg.* 2015;150(2):110-7.
- Rosen M, Brody F, Ponsky J. Predictive factors for conversion of laparoscopic cholecystectomy. *Am J Surg.* 2002;184(3):254-8.
- Chindarkar H, Dumbre R, Fernandes A, Phalgune D. Study of correlation between pre-operative ultrasonographic findings and difficult laparoscopic cholecystectomy. *Int Surg J.* 2018;5(7):2605-11.
- Charan J Biswas T. How to calculate sample size for different study design in medical research Indian J Psychol Med. 2013;35(2):121-6.
- Sultan AM, El Nakeeb A, Elshehawy T, Elhemmal M, Elhanafy E, Atef E. Risk factors for conversion during laparoscopic cholecystectomy: retrospective analysis of ten years' experience at a single tertiary referral centre. *Dig Surg.* 2013;30(1):51-5.
- Liu CL, Fan ST, Lai EC, Lo CM, Chu KM. Factors affecting conversion of laparoscopic cholecystectomy to open surgery. *Arch Surg.* 1996;131(1):98-101.
- Ishizaki Y, Miwa K, Yoshimoto J, Sugo H, Kawasaki S. Conversion of elective laparoscopic to open cholecystectomy between 1993 and 2004. *Br J Surg.* 2006;93(8):987-91.
- Nidoni R, Udachan TV, Sasnur P, Baloorkar R, Sindgikar V, Narasangi B. Predicting Difficult Laparoscopic Cholecystectomy Based on Clinicoradiological Assessment. *J clin diagnostic res.* 2015;9(12):PC09.
- Ibrahim S, Hean TK, Ho LS, Ravintharan T, Chye TN, Chee CH. Risk factors for conversion to open surgery in patients undergoing laparoscopic cholecystectomy. *World J Surg.* 2006;30(9):1698-704.
- Sikora SS, Kumar A, Saxena R, Kapoor VK, Kaushik SP. Laparoscopic cholecystectomy-can conversion be predicted? *World J Surg.* 1995;19:858-60.
- Lal P, Agarwal P, Malik VK, Chakravarti A. A difficult laparoscopic cholecystectomy that requires conversion to open procedure can be predicted by preoperative ultrasonography. *JLS.* 2002;6(1):59-64.
- Yetkin G, Uludag M, Citgez B, Akgun I, Karakoc S. Predictive factors for conversion of laparoscopic cholecystectomy in patients with acute cholecystitis. *Bratisl Lek Listy.* 2009;110:688-91.
- Jansen S, Jorgensen J, Caplehorn J, Hunt D. Pre-operative ultrasound to predict conversion in laparoscopic cholecystectomy. *Surg Laparosc Endosc.* 1997;7:121-3.
- Stanisic V, Milicevic M, Koccev N, Stojanovic M, Vlaovic D, Babic I et al. Prediction of difficulties in

laparoscopic cholecystectomy on the base of routinely available parameters in a smaller regional hospital. *Eur Rev Med Pharmacol Sci.* 2014;18(8):1204-11.

24. Daradkeh SS, Suwan Z, Abukhalaf M. Pre-operative ultra-sonography and prediction of technical difficulties during laparoscopic cholecystectomy. *World J Surg.* 1998;22:75-7.

Cite this article as: Sharma R, Dumbre R, Fernandes A, Phalgune D. Utility of pre-operative abdominal ultrasound to predict conversion to open cholecystectomy. *Int Surg J* 2021;8:3007-12.