

Original Research Article

Assessment of early outcome in laparoscopic totally extraperitoneal inguinal hernia repair using lightweight mesh

Sabhari Haran Sivakumar, Jainendra K. Arora*, Nishith S. Mandal

Department of Surgery, Vardhman Mahavir Medical College and Safdarjung Hospital, New Delhi, India

Received: 08 August 2021

Accepted: 10 August 2021

*Correspondence:

Dr. Jainendra K. Arora,

E-mail: dr.jaiarora@gmail.com

Copyright: © the author(s), publisher and licensee Medip Academy. This is an open-access article distributed under the terms of the Creative Commons Attribution Non-Commercial License, which permits unrestricted non-commercial use, distribution, and reproduction in any medium, provided the original work is properly cited.

ABSTRACT

Background: Laparoscopic surgery is dominating in the field of hernia. The search for the ideal prosthetic biomaterial has been a longstanding issue with debate over simple versus composite biomaterial and lightweight versus heavyweight meshes. This study was done to evaluate the early outcome of lightweight mesh in laparoscopic totally extraperitoneal (TEP) repair.

Methods: This prospective observational study was done for a period of 16 months. On the basis of selection criteria patient underwent laparoscopic TEP repair using light weight mesh, early outcomes were evaluated in terms of immediate postoperative pain (analysed via visual analog scale) and chronic groin pain (analysed by visual analogue scale and graded according to Cunningham), patients were also evaluated for operation time, intraoperative bleeding, seroma, stiffness or numbness around groin, or any other complications.

Results: There was no intraoperative bleeding among any of the patients. Immediate post-operative pain assessed by visual analogue scale 20% scored one in the visual analogue scale in post-operative day 1. None of the patients were having any complications (like stiffness or numbness in groin or thigh and any other complication) during post-surgery follow up. Only one patient reported mild chronic groin pain at the end of 3 months after surgery.

Conclusions: The short term results of laparoscopic TEP repair for inguinal hernia using light weight mesh are quite encouraging. We can conclude that light weight mesh is fulfilling important role in successful hernia repair as it is associated with very less morbidity.

Keywords: Laparoscopic TEP and light weight mesh, Light weight mesh results

INTRODUCTION

Inguinal hernia is the most common hernia owing to the weak muscular anatomy in the inguinal region because of presence of natural weakness like deep ring and cord structures.

70-80% of abdominal wall hernias are groin hernias. 27% of males and 3% of females develop groin hernias.¹ Presently all hernias in groin are called as groin hernias. Modified Bassini and Shouldice technique are earlier used methods of open herniorrhaphy. But these procedures are rarely being done now in elective settings however these

procedures are employed as in the treatment of emergency inguinal hernias. Open hernioplasty using mesh repair has been used in surgery for hernia. Now laparoscopic hernioplasty is dominating in the field of hernia surgery by improvements in patients' long term.

Laparoscopic hernioplasty has many advantages over open repair. Laparoscopic repair has reduced postoperative pain and short recovery period. With laparoscopic repair the entire myo-pectineal orifice can be inspected, this allows repair of any unexpected occult hernias which reduces the chance of recurrence. Laparoscopic hernioplasty also avoids previous operative scar site in patients with

recurrent hernias. In addition, simultaneously bilateral inguinal hernias can be managed easily through same port sites.

The disadvantages of laparoscopic repair include requirement of general anaesthesia, the breach of peritoneum in transabdominal, preperitoneal (TAPP) repairs and the cost of the procedure and the need of experience of the operating team. The manipulation of the mesh in the confined space is quite tedious and prevents the operating surgeons from using laparoscopic technique in majority of the patients having inguinal hernias.

Cobbs et al and Junge et al observed that polypropylene mesh may be associated with pain and discomfort as it generates a profound inflammatory response that results in scar formation, increased rigidity and stiffness of the abdominal wall, and shrinkage of the biomaterial with time.²

The introduction of a new “lightweight” mesh for inguinal hernia repair has raised questions as to whether this will translate to a better outcome. Reducing the density of “heavyweight” polypropylene and creating a lightweight mesh should induce less foreign-body response and scar formation.³ Weight of the mesh is actually mass of the material in a set area, which is actually density. Lightweight meshes considered less than 35 g/sq.m and these meshes are mostly caliber woven meshes with large pores upto 4 mm. Heavyweight mesh has a density of more than 60 g/sq.m, knitted and has small pores. Tensile strength of heavyweight mesh is in a range of 1200 N and compared with lightweight mesh of 540 N.

The bridging fibrosis is the key to sustained tissue strength which depends upon porosity. More is the size of the pores greater is the infiltration of macrophages and fibroblasts to create neovascularisation and tissue ingrowth. Lightweight mesh has a pore width of 3 to 4 mm compared with heavyweight mesh of 1 mm or less. This may result in improved abdominal-wall compliance, with less contraction or shrinkage of the mesh, thus allowing for better tissue incorporation and less morbidity related to the mesh.

The search for the ideal prosthetic biomaterial has been a longstanding issue with debate over simple versus composite biomaterial, whether or not to fix the mesh in place with sutures/staples, and lightweight versus heavyweight meshes. There is no clear evidence to favour any of the different types of mesh currently available, and there is little data regarding efficacy.

There is currently paucity of Indian studies evaluating about light weight mesh in laparoscopic totally extraperitoneal (TEP) procedure. So the objective of our study was to evaluate short term results of light weight mesh in laparoscopic TEP inguinal hernioplasty in terms of operation time, intraoperative bleeding, immediate postoperative pain, stiffness or numbness around groin,

chronic groin pain (pain persisting beyond 3 months from date of surgery according to the international association of study of pain).

METHODS

This prospective observational study was conducted in the Department of General Surgery, VMMC and Safdarjung Hospital, New Delhi from November 2019 to March 2021, for a period of 16 months. The study was undertaken after approval from institutional ethic committee and informed consent was taken from all participants

The primary objective of the study was to evaluate the short term results of light weight mesh in laparoscopic TEP repair for inguinal hernia especially in terms of immediate postoperative pain (analysed via visual analog scale) and chronic groin pain (analysed by visual analogue scale and graded according to Cunningham) and also to assess operation time, intraoperative bleeding, seroma, stiffness or numbness around groin, any other complications.

Inclusion criteria

All patients undergoing elective laparoscopic TEP inguinal hernia repair were included.

Exclusion criteria

Patients of age less than 18 years, patients unfit for laparoscopic surgery, and obstructed/strangulated/irreducible inguinal hernia were excluded.

Chronic pain was defined in line with the International association of study of pain as that pain persisting beyond 3 months from the date of surgery.⁴ The type of pain (somatic ligamentous, neuropathic or visceral) and its severity were classified according to Cunningham.⁵ Mild pain was defined as occasional pain or discomfort and caused no limitation to usual activities and allowed for a full return to pre-hernia lifestyle.

Moderate pain was defined as pain interfering with or preventing a full return to pre-hernia activities such as sports, but not limiting basic daily activities. Severe pain was defined as pain that incapacitated the patient at regular intervals or interfered with basic activities of daily living such as walking, or caused significant occupational difficulties. Sensory impairment was categorized into anesthesia, paraesthesia or hyperaesthesia.

Sample size

The study of Prakash et al observed that the mean pain score at 24 hour in LW mesh was 2.2 ± 1 .⁶ Taking this value as reference, the minimum required sample size with precision error to be 17.5% and 5% level of significance is 26 patients. To reduce margin of error, total sample size taken was 30.

Formula used is:

$$N \geq [(SD \times Z\alpha)/d]^2$$

Where $Z\alpha$ is value of Z at two sided alpha error of 5%, d is precision error and SD is standard deviation.

Calculations:

$$n \geq [(1 \times 1.96)/0.175 \times 2.2]^2 = 25.92 \\ = 26 \text{ (approx)}$$

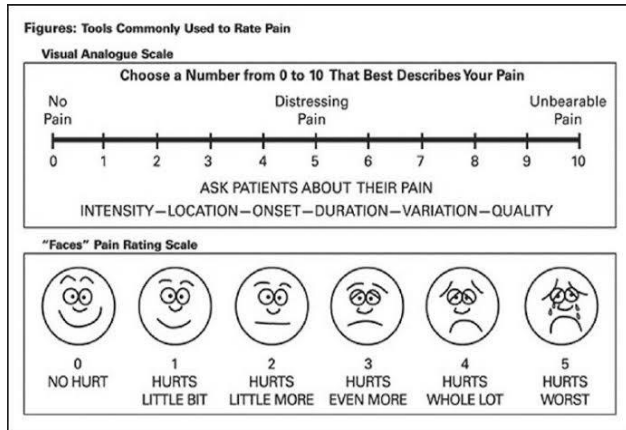


Figure 1: Visual analogue scale.

Statistical analysis

Categorical variables will be presented in number and percentage (%) and continuous variables will be presented as mean±SD and median. Normality of data will be tested by Kolmogorov-Smirnov test. If the normality is rejected then non parametric test will be used. Quantitative variables will be compared using paired t-test/Wilcoxon test (when the data sets were not normally distributed) between pre and post. A p value of <0.05 will be considered statistically significant. The data will be entered in Microsoft excel spreadsheet and analysis will be done using statistical package for social sciences (SPSS) version 21.0.

Methodology

Patients undergoing laparoscopic inguinal hernia TEP inguinal repair was prospectively enrolled in a surgical database. One surgeon performed all cases using a standard technique, all patients received prophylactic antibiotics before the first incision based on individual drug allergy information. Light weight mesh 15 cm by 15 cm (approximately equal parts of absorbable poliglecaprone-25 monofilament fibre and non-absorbable polypropylene monofilament fibre) was used for hernia repair. The mesh was secured in place with two absorbable hernia tackers one along the pubic symphysis medially and another laterally.

Patients were evaluated for operating time, intra operative bleeding or any other intra operative event. At a mean follow-up of 1, 4 and 12 weeks, all treated patients were evaluated for post-operative pain (accessed by visual analogue scale), seroma, stiffness and numbness around groin and chronic groin pain.

RESULTS

The median (Q1, Q3) age of participants was 30 (27, 34.5) years shown in Figure 2.

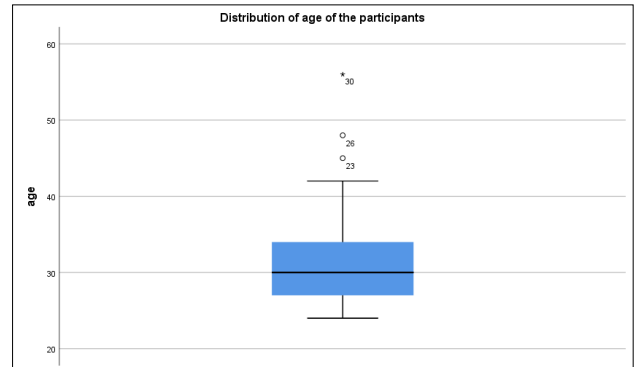


Figure 2: Distribution of age of participants.

Table 1 shows majority of the patients were having right sided hernia (20, 66.7%) and majority of the patients were having indirect hernia (23, 76.7%) as shown in Table 2.

Table 1: Side of hernia.

Side	Frequency	Percentage
Right	20	66.7
Left	10	33.3
Total	30	100.0

Table 2: Hernia type.

Type	Frequency	Percentage
Direct	7	23.3
Indirect	23	76.7
Total	30	100.0

Table 3 depicts majority of the patients were having right indirect hernia (16, 53.3%), followed by left indirect hernia (7, 23.3%), right direct (4, 13.3%) and left direct hernia (3, 10%).

Table 3: Type of hernia.

Type	Frequency	Percentage
Right direct	4	13.3
Right indirect	16	53.3
Left direct	3	10.0
Left indirect	7	23.3
Total	30	100.0

Table 4 shows intra-operatively, right indirect sac was observed in 16(53.3%) patients, followed by left indirect sac (7, 23.3%), right direct sac (4, 13.3%) and left direct sac (3, 10%).

Table 4: Intra-op findings.

Intra-op findings	Frequency	Percentage
Right direct sac	4	13.3
Right indirect sac	16	53.3
Left direct sac	3	10.0
Left indirect sac	7	23.3
Total	30	100.0

Table 5 depicts right TEP was done for 20 (66.7%) patient, while left TEP was conducted for 10 (33.3%) patients.

6 (20%) scored one in the visual analogue scale in post-op.

Table 5: Procedure done.

Procedure done	Frequency	Percentage
Right TEP	20	66.7
Left TEP	10	33.3
Total	30	100.0

The median (Q1, Q3) operative time was 70 (60, 75.5) minutes as shown in Figure 3.

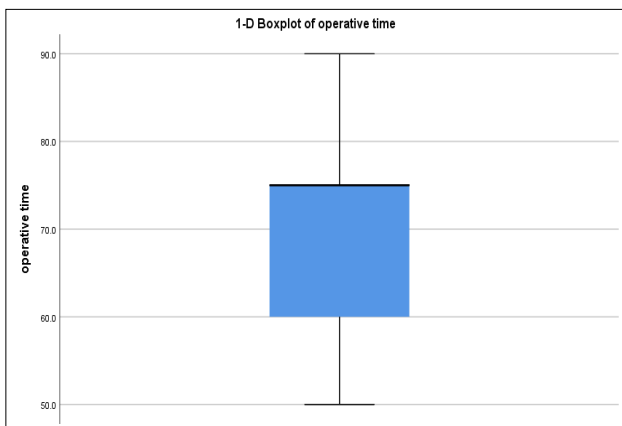


Figure 3: Distribution of operating time.

Immediate post-operative pain was assessed by visual analogue scale 6 (20%) scored one in the visual analogue scale in post-operative day 1 (shown in Table 6), however except for one patient rest all other patients had no pain in groin during 1st week, 4th week and 12th week follow up. There was no intraoperative bleeding among any of the patients. None of the patients were having any complications (like stiffness or numbness in groin or thigh and any other complication) during 1st week, 4th week and 12th week post-surgery follow up. 2 patients (6%) had seroma (Figure 4) on follow up which got resolved spontaneously on further follow up. One of the patient (3%) had reported mild chronic groin pain at the end of 3

months after surgery (Figure 5) which got relieved on further follow up.

Table 6: Pain (visual analogue scale) on POD 1.

Visual analogue scale	Frequency	Percentage
0	24	80.0
1	6	20.0
Total	30	100.0

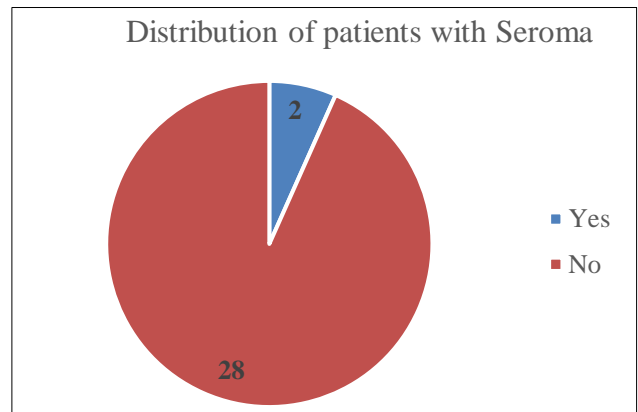


Figure 4: 6% of patients (2 patients) had seroma on follow up examination, which got resolved spontaneously on further follow up.

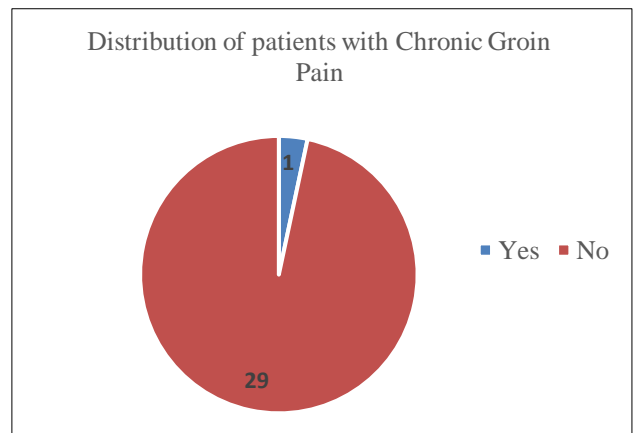


Figure 5: One patient (3%) had reported mild chronic groin pain at end of 3 months.

DISCUSSION

A prospective observational study of 30 patients undergoing laparoscopic TEP by a single surgical team was followed prospectively with a physical examination on immediate postoperative period (POD1) pain (via visual analogue scale) at 1st week, 4th week and 12th week and were also observed for seroma formation, early recurrences, stiffness and numbness around groin and any other complications related to procedure. Data collected also included operative time, intraoperative bleeding, and intraoperative findings.

In this study all the patients were male, median age of patients were 30 (27-34 years). All patients were operated for unilateral inguinal hernia by laparoscopic TEP repair by using lightweight mesh ultrapro. The median operating time in this study was 70 minutes. In a study done by Mir et al median operating time was 37.4 minutes.⁷

Majority of patients in this study had indirect hernia. Majority of patients in this study had right indirect hernia consistent with a study done by Tamme et al.⁸

Majority of the patients in this study had undergone right TEP repair. Intraoperatively majority patients had right indirect sac.

In this study 20% of patients (6 patients) had visual analogue scale of 1 on first postoperative day.

Except for one, no patients in this study had any pain when followed up at first, fourth and twelfth week, the results of our study were comparable to study done by Wollert et al.⁹ And another study by Chowbey et al had similar comparable results that early pain score was less with lightweight mesh in TEP repair.¹⁰

Regarding seroma, two patients did have seromas in the early postoperative period. However this seroma was asymptomatic (no pain and/or infection), and did not require aspiration and got resolved spontaneously, these results were comparable to studies done by Bringman et al and Heikkinen et al.^{9,11}

In our study one patient (3%) reported chronic groin pain at the end of 3 months of study, the pain was mild in intensity, patient is still in follow up and has got complete relief in pain after six month follow up, none of the patient complaints of stiffness or numbness of thigh and groin. These results were also comparable to study done by Chui et al.¹²

Wound was observed in our patients till follow up till 3 months, no patients in this study had infection of wound these results are also consistent with the study done by Agarwal et al.^{9,13} The results of this study are important but somewhat limited, studies with larger sample size and longer follow-up periods are needed to confirm results of the lightweight mesh.

CONCLUSION

The data from our study suggest that laparoscopic TEP repair for inguinal hernia using light weight mesh yields excellent early outcome in terms of postoperative morbidity. The lesser number of patients experiencing immediate and chronic post-operative pain is encouraging. In addition chronic pain associated was mostly mild and transient without any associated sensory disturbance or stiffness. So we can conclude that light weight mesh is fulfilling important role in successful hernia repair as it is associated with very less morbidity.

Funding: No funding sources

Conflict of interest: None declared

Ethical approval: The study was approved by the Institutional Ethics Committee

REFERENCES

1. Kingsnorth A, LeBlanc K. Hernias: inguinal and incisional. *Lancet*. 2003;362(9395):1561-71.
2. Cobb WS, Kercher KW, Heniford BT. The argument for lightweight polypropylene mesh in hernia repair. *Surg Innov*. 2005;12:63-9.
3. Junge K, Rosch R, Krones CJ, Klinge U, Mertens PR, Lynen P, Schumpelick V, Klosterhalfen B et al . Influence of polyglecaprone 25 (Monocryl) supplementation on the biocompatibility of a polypropylene mesh for hernia repair. *Hernia*. 2005;9(3):212-7.
4. Bruce JP, Balan AS, Smith WCS. Quantitative Assessment of Chronic Post Surgical Pain Using McGill Pain Questionnaire. *Clin J Pain*. 2004;20:70-5.
5. Cunningham J, Temple WJ, Mitchell P. Operative Hernia Study, Pain in the Post Operative Patient. *Ann Surg*. 1996;224:598-602.
6. Prakash P, Bansal VK, Misra MC, Babu D, Sagar R, Krishna A, et al. A prospective randomised controlled trial comparing chronic groin pain and quality of life in lightweight versus heavyweight polypropylene mesh in laparoscopic inguinal hernia repair. *J Min Access Surg*. 2016;12:154-61.
7. Mir IS, Nafae AA, Malyar AA, Nafae M, Watali Y, Farooq M, et al. An Experience of Short-Term Results of Laparoscopic Inguinal Hernioplasty Using 3D Mesh in a Developing Country. *Int J Clin Med*. 2015;6:64-9.
8. Tamme C, Scheidbach H, Hampe C, Schneider C, Köckerling F. Totally extraperitoneal endoscopic inguinal hernia repair (TEP). *Surg Endosc*. 2003;17(2):190-5.
9. Bringman S, Wollert S, Osterberg J, Heikkinen T. Early results of a randomized multicenter trial comparing Prolene and Vypro II mesh in bilateral endoscopic extraperitoneal hernioplasty (TEP). *Surg Endosc*. 2005;19:536-40.
10. Chowbey PK, Garg N, Sharma A, Khullar R, Soni V, Bajjal M, Mittal T. Prospective randomized clinical trial comparing lightweight mesh and heavyweight polypropylene mesh in endoscopic totally extraperitoneal groin hernia repair. *Surg Endosc*. 2010;24:3073-9.
11. Heikkinen T, Wollert S, Osterberg J, Smedberg S, Bringman S. Early results of a randomized trial comparing Prolene and Vypro II-mesh in endoscopic extraperitoneal inguinal hernia repair (TEP) of recurrent unilateral hernias. *Hernia*. 2006;10:34-40.
12. Chui LB, Ng WT, Sze YS, Yuen KS, Wong YT, Kong CK. Prospective, randomised, controlled trial comparing lightweight versus heavyweight mesh in

chronic pain incidence after TEP repair of bilateral inguinal hernia. *Surg Endosc.* 2010;24(11):2735-8.

13. Agarwal BB, Agarwal KA, Mahajan KC. Prospective double-blind randomized controlled study comparing heavy- and lightweight polypropylene mesh in totally extraperitoneal repair of inguinal hernia: early results. *Surg Endosc.* 2009;23:242-7.

Cite this article as: Sivakumar SH, Arora JK, Mandal NS. Assessment of early outcome in laparoscopic totally extraperitoneal inguinal hernia repair using lightweight mesh. *Int Surg J* 2021;8:2566-71.