

Original Research Article

Ultrasound guided direct puncture percutaneous nephrostomy: a single tertiary centre observational study

Suresh Kumar Rulaniya^{1*}, Samir Swain¹, Vishal Kumar Neniwal¹, Shweta Bhalothia²,
Kishor Tonge¹, Piyush Agarwal¹, Zaid Ahmad Khan¹, Datteswar Hota¹

¹Department of Urology, SCB MCH, Cuttack, Odisha, India

²Department of Diagnostic and Intervention Radiology, AIIMS, Jodhpur, Rajasthan, India

Received: 06 August 2021

Revised: 16 August 2021

Accepted: 01 October 2021

***Correspondence:**

Dr. Suresh Kumar Rulaniya,

E-mail: drsureshjpr@gmail.com

Copyright: © the author(s), publisher and licensee Medip Academy. This is an open-access article distributed under the terms of the Creative Commons Attribution Non-Commercial License, which permits unrestricted non-commercial use, distribution, and reproduction in any medium, provided the original work is properly cited.

ABSTRACT

Background: Percutaneous nephrostomy (PCN) is indicated to drain the upper urinary tract collecting system in cases of obstruction. Objective of our study is to evaluate the safety and efficacy of Ultrasound guided direct puncture PCN in our populations.

Methods: This observational study was conducted from May 2020 to April 2021 in department of urology and renal transplant. The total 65 patients with upper urinary tract obstruction requiring PCN were enrolled. All parameters were recorded and statistical analysis was performed using the Statistical package for the social sciences (SPSS 16.0) for windows.

Results: In our study Ca Cervix with ureteric infiltration (35%) was the most common indication for PCN tube placement. Majority of patients (83%) had Grade IV and Grade III hydronephrosis. Single attempt for tube placement was sufficient most of the time in (86% cases). Direct Puncture PCN tube placement was successful in 62 (95.4%) cases. The mean duration of procedure was 12.4 minutes. Loin pain was the most common procedure related complication observed in 58 patients. There was no evidence of visceral injury, no need of blood transfusion in post procedural duration in our study.

Conclusions: USG guided direct puncture PCN technique is simple, low cost, less time consuming, less chance of loss of tract and effective procedure for drainage of urine in case of upper urinary tract obstruction. We recommended this procedure in grade III and IV hydronephrosis and this procedure suitable for developing countries like India because of procedure related low cost.

Keywords: Nephrostomy, Percutaneous, Hydronephrosis

INTRODUCTION

Therapeutic percutaneous nephrostomy (PCN) is indicated to drain the upper urinary tract collecting system in cases of obstruction at an intra renal location, at the pelvi-uretero junction or anywhere in the ureter. Diagnostic PCN is popular to perform Whitaker test. The first therapeutic PCN was described by Goodwin, since then various direct and seldinger methods of PCN tube placement have been described¹. The standard seldinger technique uses

puncture needle, guide wire, tract dilatation which increases the cost of procedure. In developing country like India the ultrasound (USG) guided direct puncture PCN tube placement is cost effective as compare with seldinger technique. Direct puncture PCN is simple, less time consuming, less traumatic and better outcome with high grade hydronephrosis. Aim of our study is to evaluate the safety and efficacy of Ultrasound guided direct puncture percutaneous nephrostomy (PCN) in our populations.

METHODS

This was an observational study that conducted in department of urology and renal transplant, SCB medical Collage, Cuttack. Study conducted from May 2020 to April 2021. Total 65 patients were enrolled with varying degree of upper urinary tract obstruction.

Methodology

All Patients were investigated with USG (KUB), plain X-ray (KUB), NCCT (KUB), others investigations included- complete blood count, BT and CT, serum urea, creatinine, electrolytes, serology and urine routine with culture.

Inclusion criteria

The subjects were included in the study based on following criteria- hydronephrosis associated with varies disease profile.

Exclusion criteria

The subjects were excluded from the study based on following criteria: non dilated pelvicalyceal system, Hb <8 gm/dl, bleeding disorders, severely co morbid patient, refuse to consent.

The study was conducted in adherence to the ethical guidelines of the declaration of Helsinki and its amendments. Statistical analysis was performed using IBM Statistical package for social sciences (SPSS) version 27, and $p < 0.005$ was considered statistically significant. Written consent was taken from all patients prior to the procedure and clinical details for academic purpose. Patients who refused to give consent were excluded from this study. We confirm the availability and access of all original data reported in this study.

Procedure

Every patient had taken antibiotic tab fluoroquinolones as prophylactically.

Procedure- we used 12-F/14F, 22cm PCN pigtail catheter with metallic tip in all cases (Figure 1).

Steps as followings

Step 1: Under all aseptic precautions painting & draping had done in prone position of patient.

Step 2: USG scan of affected kidney was done and localization of puncture site confirmed along the longitudinal axis. (Figure 2)

Step 3: Puncture site was marked and injection lignocaine 2% infiltration done upto muscle layer.

Step 4: A small incision of about 1cm given over puncture site and extended upto muscle.

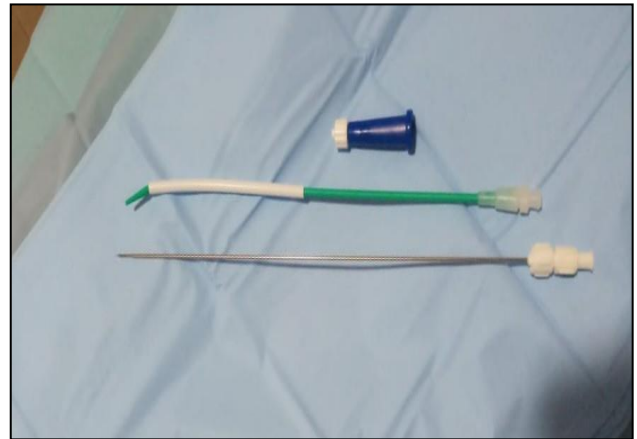

Figure 1: PCN Pigtail catheter with metallic tip and connector.

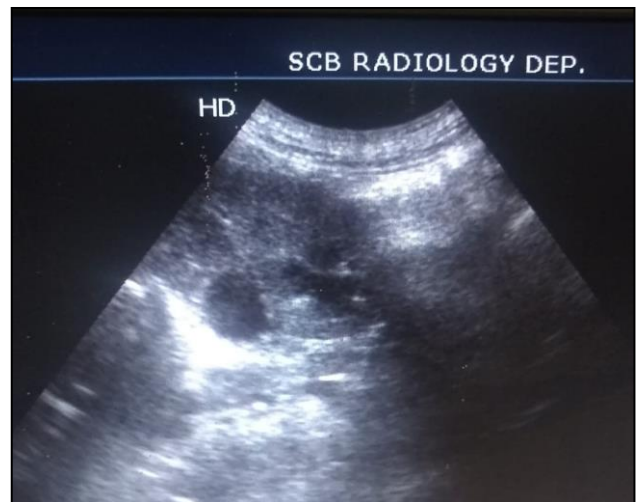


Figure 2: USG scan shows hydronephrosis.

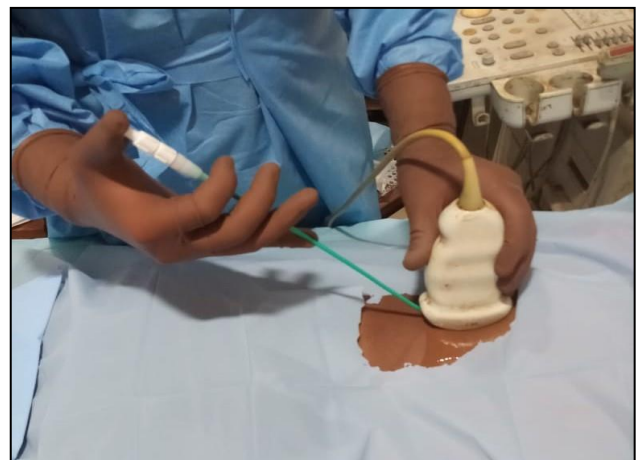

Figure 3: Placement of USG probe and PCN tube with needle insertion.

Step 5: In most of cases lower calyx puncture was done and in few conditions where upper and middle calyceal puncture was done. (Figure 3)

Step 6: PCN tube with needle was inserted and advanced upto Renal pelvis under real time USG guidance. (Figure 4)

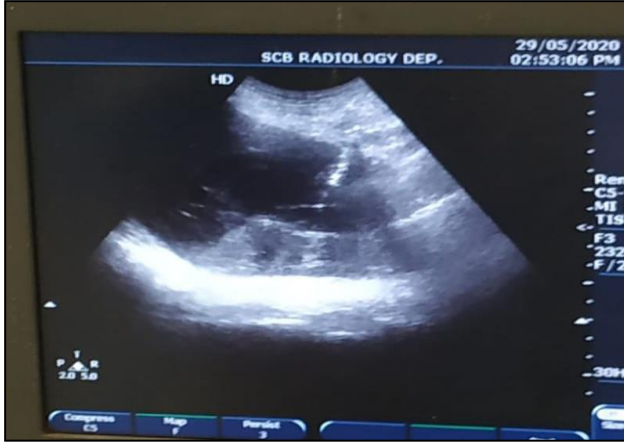

Figure 4: PCN tube with metallic tip is advanced under vision.

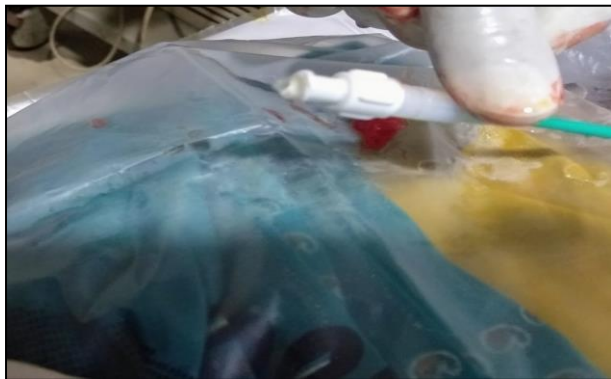

Figure 5: Free flow of urine.

Step 7: After confirmation of the tip in pelvis inner cannula was removed, free flow of urine was noted from catheter for confirmation. (Figure 5)

Step 8: Catheter was connected to urobag and fixed with skin using 1-0 mer silk.

Post procedure care- Broad spectrum antibiotic was advised to all patients.

All preoperative, intra operative and post-operative data were collected and statistical analysis was performed using the SPSS 16.0 for windows.

RESULTS

A total of 65 patients underwent Direct puncture PCN between May 2020 to April 2021 for different indications

at our tertiary care centre (Table 1). Ca Cervix with ureteric infiltration was found most common etiology of hydronephrosis (Figure 6). The average age of patients operated is 47.3 years (range: 13-79 years) with a male: female of 36:26. Out of 65 patients 30 underwent left PCN, 16 right PCN and rest 19 bilateral PCN.

Majority of patients (83%) had grade IV and Grade III hydronephrosis. Single attempt for tube placement was sufficient most of the time in 86% cases (Table 2).

Table 1: Causes of hydronephrosis.

Cause of HDN	No of patients (n-65)
Ca Cervix with ureteric infiltration	23
Impacted ureteric calculus	12
Ca urinary bladder	8
Pyonephrosis	5
Failed DJ stenting	6
PUJO with renal impairment	5
Emphysematous pyelonephritis	3
Stricture ureter	3

Table 2: Summary of results.

Total number of patients	65
Age (mean ± SD)	47.3
Range	13-79
Male: female	39: 26
No. of cases underwent Right PCN	16 (24.6%)
No. of cases underwent Left PCN	30 (46.1%)
No. of cases underwent Bilateral PCN	19 (29.2%)
Grading of HDN	
Grade I	3 (4.6%)
Grade II	8 (12.3%)
Grade III	20 (30.7%)
Grade IV	34 (52.3%)
Attempts for tube placement	
Single attempt	56 (86.1%)
More than one	9 (13.9%)
Tube placement	
Successful	62 (95.4%)
Unsuccessful	3 (4.6%)
Duration of procedure (mean± SD) in minutes	12.4
Mean serum Creatinine (mg/dl)	
Preprocedural	4.61
Postprocedural at day 7	3.5

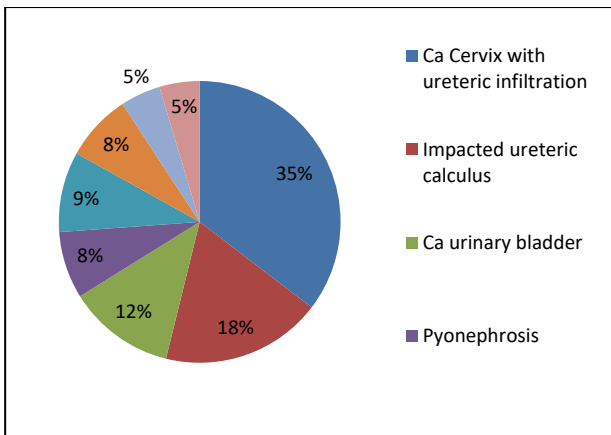


Figure 6: Causes of hydronephrosis.

Table 3: Procedure related complications.

Loin pain	58
Hematuria	4
Tube placement failure	3
Fever	8
Urinary tract infection	1
Urinoma/Absecess	2
Wound infection	0

DISCUSSION

Percutaneous nephrostomy (PCN) was first described by urologist Dr. Willard Goodwin in 1955 as a minimally invasive, x-ray guided temporary or permanent procedural alternative to traditional surgery in patients with hydronephrosis.¹ Classically it involves fluoroscopy guided puncture followed by tract dilatation and insertion of the tube with or without use of guide wire.

Pederson et al performed first Ultrasound guided PCN and since then various studies on USG guided PCN tube placement have been carried out with good success rate. The conventional technique uses a needle puncture, guide wire, serial tract dilatation and nephrostomy tube which increase the length and cost of the procedure.²

Karim et al started USG guided direct puncture PCN technique at their institute which was departure from standard protocol. They started this procedure because some patients could not afford high cost (5000 INR) of standard protocol procedure but patients required early decompression and functional recovery to improve the final outcome. They reported less than 30 minutes for this procedure. In our study we found that this procedure has low cost, approximately 800-1000 INR as compared to standard Seldinger technique, which has approximately 3500-5000 INR cost that is suitable for our poor patients.³

Selection of the patient, skill of operators and base line investigations are the keys to success. As the grade of hydronephrosis decreases the puncture difficulty

increases. PCN tube placement was successful in 96.60% of cases and only 9.66% required more than a single attempt of puncture. The average length of the procedure was 9.07±2.79 (6-15) minutes. Severe procedure related pain (VAS score 8-10) was observed only in 18 patients (10.23%). In their study, impacted ureteric calculus was found to be most common indication of PCN tube placement.⁴ Our study shows 95.4% successful rate of tube placement with Ca Cervix is most common indication. The mean duration of procedure was 12.4 minutes in our study. Duration of the procedure is less than 15 minutes after we had become familiar with the technique.

Efesoy et al in their study “The results of ultrasound-guided percutaneous nephrostomy tube placement for obstructive uropathy: A single-centre 10-year experience” concluded that placement of nephrostomy tube via percutaneous route under the guidance of ultrasound for therapeutic purposes may be applied effectively, and safely by urologists. In patients with low-grade hydronephrosis, it is appropriate to use Seldinger access technique. However, it should not be forgotten that this method takes longer time when compared with the direct puncture technique, and it has higher equipment costs.⁵

Cangüven et al in their study “Comparison of direct and Seldinger percutaneous nephrostomy insertion techniques” concluded that the ultrasound-guided direct one-stab and Seldinger techniques are safe PCN procedures. These techniques can be applied successfully with minimal complications in outpatient clinics if performed by experienced operators. We recommend PCN applications as successful procedures for obstructive uropathy and/or in prevention of organ loss in addition to their good results.⁶

Montvilas et al in a study ‘Single-centre review of radiologically guided percutaneous nephrostomy using “mixed” technique: Success and complication rates’ concluded that Percutaneous nephrostomy using the “mixed” technique is very successful in dilated systems, is not superior to other PCN techniques in non-dilated systems and has a very low rate of major complications.⁷

The potential complications of the PCN are; sepsis, perirenal hematoma, urinoma formation, perforation of a viscus and pyopneumothorax.⁸ Though there was no procedure related mortality in, but a figure up to 0.05-0.3% and significant bleeding requiring transfusion or surgical intervention in 1-4% has been reported.^{9,10} In our study majority of patients (58) complained of mild to moderate pain (VAS upto 7), which persisted upto 48 hours in some cases, of which most of the patients managed by oral analgesics. Only 11 patients experienced severe pain (VAS 8-10) required injectable analgesics. Tube placement failed in 3(4.6%) patients because these patients have Grade I hydronephrosis and PCS not sufficiently dilated to proceed, so procedure aborted (Table 3). There was no evidence of visceral injury, no need of blood transfusion in post procedural duration in our study.

The major limitation we feel is that urologist needs to more training in ultrasound to perform this procedure in grade I/II hydronephrosis.

CONCLUSION

USG guided PCN by direct puncture technique is simple, low cost, less time consuming, less chance of loss of tract and effective procedure for temporary drainage of urine in case of urinary tract obstruction. In an experienced hand, complication rates are very low. We recommended this procedure in grade III and IV hydronephrosis and this procedure is suitable for developing countries like India where majority of populations belongs to low socio-economical status which could not afford high cost of conventional procedure.

Funding: No funding sources

Conflict of interest: None declared

Ethical approval: The study was approved by the Institutional Ethics Committee

REFERENCES

1. Goodwin WE, Casey WC, Woolf W. Percutaneous trocar (needle) nephrostomy in hydronephrosis. J Am Med Assoc. 1955;157:891-4.
2. Pedersen JF. Percutaneous nephrostomy guided by ultrasound. J Urol. 1974;112:157-9.
3. Karim R, Sengupta S, Samanta S, Aich RK, Das U, Deb P. Percutaneous nephrostomy by direct puncture technique: An observational study. Indian Journal of nephrology. 2010;20(2):84.
4. Lodh B, Gupta S, Singh AK, Sinam RS. Ultrasound Guided Direct Percutaneous Nephrostomy (PCN) Tube Placement: Stepwise Report of a New Technique with Its Safety and Efficacy Evaluation. J Clin Diagn Res. 2014;8(2):84-7.
5. Efesoy O, Saylam B, Bozlu M, Çayan S, Akbay E. The results of ultrasound-guided percutaneous nephrostomy tube placement for obstructive uropathy: A single-centre 10-year experience. Turk J Urol. 2018;44(4):329-34.
6. Cangüven Ö, Göktaş C, Kafkaslı A, Aydemir H, Albayrak S. Comparison of direct and Seldinger percutaneous nephrostomy insertion techniques. Medical Journal of Bakırköy. 2009;5:103-5.
7. Montvilas P, Solvig J, Johansen TE. Single-centre review of radiologically guided percutaneous nephrostomy using "mixed" technique: success and complication rates. Eur J Radiol. 2011;80(2):553-8.
8. Li AC, Regalado SP. Emergency percutaneous nephrostomy for the diagnosis and management of pyonephrosis. Semin Intervent Radiol. 2012;29:218-25.
9. Ramchandani P, Cardella JF, Grassi CJ, Roberts AC, Sacks D, Schwartzberg MS, et al. Quality improvements guidelines for percutaneous nephrostomy. J Vasc Interv Radiol. 2001;12:1247-51.
10. Daglli M, Ramchandani P. Percutaneous nephrostomy: technical aspects and indications. Semin Intervent Radiol. 2011;28:424-37.

Cite this article as: Rulaniya SK, Swain S, Neniwal VK, Bhalothia S, Tonge K, Agarwal P et al. Ultrasound guided direct puncture percutaneous nephrostomy: a single tertiary centre observational study. Int Surg J 2021;8:3548-52.