

## Case Report

# Spigelian hernia: a rare case presentation

Hemant Panditrao Mhatre, Vijay Bhaskarrao Kanake, Vipul Versi Nandu\*

Department of Surgery, SVNGMC and Chintamani Hospital, Yavatmal-445001, Maharashtra, India

**Received:** 22 August 2015

**Accepted:** 03 September 2015

**\*Correspondence:**

Dr. Vipul Versi Nandu,

E-mail: [dr.vipulnandu@gmail.com](mailto:dr.vipulnandu@gmail.com)

**Copyright:** © the author(s), publisher and licensee Medip Academy. This is an open-access article distributed under the terms of the Creative Commons Attribution Non-Commercial License, which permits unrestricted non-commercial use, distribution, and reproduction in any medium, provided the original work is properly cited.

### ABSTRACT

Spigelian hernia is a variety of abdominal wall hernia occurring through a slit like defect in the anterior abdominal wall (semilunar line) at the level of arcuate lines. It is a very rare with only thousand cases reported in literature. It constitutes 0.12% of the abdominal wall hernia. Thorough clinical examination with radiological scans help in diagnosis of this rare entity. Treatment of Spigelian hernia is operative repair once the diagnosis has been confirmed given the risk of incarceration. Here we report this interesting case of Spigelian hernia in a 50 years female as a rare entity among all external abdominal wall hernias.

**Keywords:** Spigelian, Hernia, Semilunar line, Arcuate line

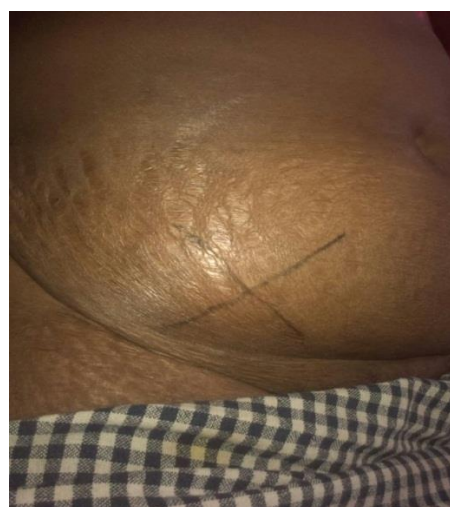### INTRODUCTION

Spigelian hernia are rare inter-parietal hernia. Most of the Spigelian hernia occurs in the lower abdomen where posterior sheath is deficient. The hernia ring is well defined defect in the transverse aponeurosis. The hernia sac surrounded by extra peritoneal fatty tissue is often intra-parietal passing through transverse and internal oblique aponeurosis and spreading out behind the intact aponeurosis of external oblique. Good clinical examination can detect this entity. The hernia may be intra-parietal with no obvious mass on inspection or palpation. The Spigelian hernia have been repaired by both conventional and laparoscopic approaches.

### CASE REPORT

A 50 year old lady, presented with chronic dull aching pain in right iliac fossa associated with a palpable lump at the right lower quadrant of the abdomen since 6 month. She denies any history of bowel or bladder alteration. No associated history of fever, vomiting, nausea, constipation, abdominal distension. The swelling

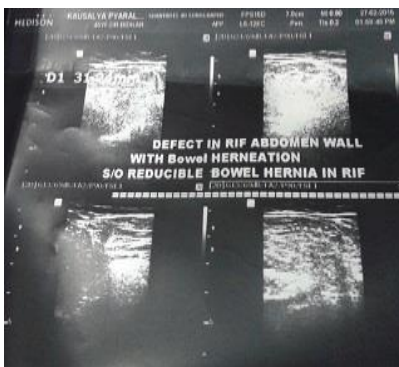
appeared on walking, straining and subsides on rest. Initially it was small and gradually progressed in size and was reducible.



**Figure 1:** Site of Spigelian hernia in the patient.

On clinical examination (Figure 1), vital parameters were within normal limits. On local examination, fullness was noted in right iliac region. On palpation she had a 4cm x 4cm well demarcated swelling in right iliac fossa lateral to rectus margin. It had a smooth surface and skin over the swelling had no scars sinuses or dilated veins. The swelling was reducible with a defect of size 3 x 3 cm palpable in right iliac fossa. There was a positive cough impulse. The swelling was non tender and without any sign of raised temperature. Rest of the hernia orifices were within normal limits. No inguinal lymphadenopathy noted.

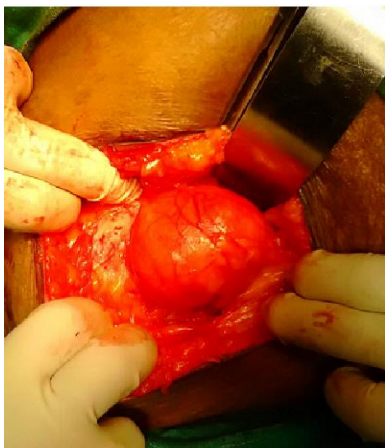Abdominal ultrasonography (Figure 2), done revealed a defect in abdominal wall in right iliac fossa suggestive of reducible bowel hernia in RIF.



**Figure 2: USG suggestive of Spigelian hernia.**

On basis of clinical and sonological examination, a diagnosis of Spigelian hernia was made. Her routine investigations were WNL. X ray abdomen showed no sign of obstruction. Pre op USG supported our clinical diagnosis of Spigelian hernia. CT scan not done due to financial constraints.

After adequate preparation she was explored under spinal anaesthesia by an oblique incision over the swelling and was found to have herniation of omentum through a defect along the lateral border of rectus sheath (Figure 3).



**Figure 3: Intra op photo showing spigelian hernia.**

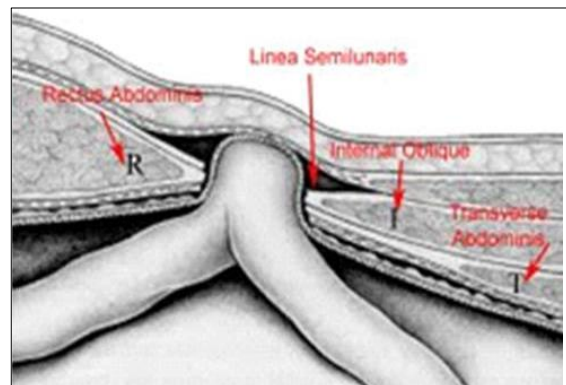
The defect measuring 3 cm in length was identified and anatomical repair was done with prolene 2-0, suturing medial border of internal oblique and transverse abdominus muscle to the lateral border of rectum abdominal wall followed by mesh reinforcement (meshplasty).

Post operatively, patient had an uneventful recovery. Suture removal was done on post-operative day 10. She followed up in OPD for 3 months after surgery where the patient was asymptomatic and clinical examination was unremarkable.

**DISCUSSION**

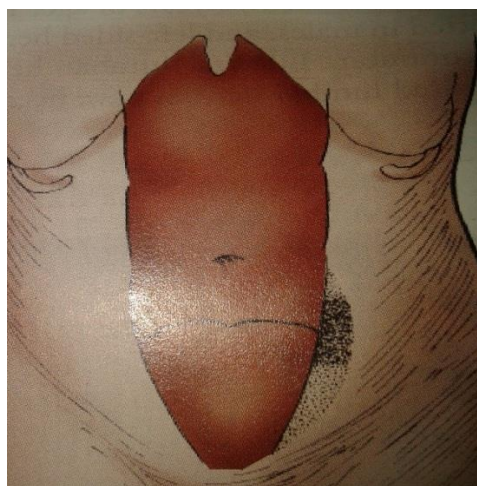
Spigelian hernia is named after Adrian Van der Spigel<sup>1</sup> who described semilunar like (linea spigeli) in 1645. The hernia was first described Klinkosch<sup>2</sup> in 1764.

Spigelian hernia are rare inter-parietal hernia. It is also called “spontaneous lateral ventral hernia” or “hernia of semilunar line”. It is usually locked between the different muscle layers of the abdominal wall, therefore it is called as intraparietal, interstitial, intramuscular or intra mural hernia.



**Figure 4: Anatomical planes in Spigelian hernia.**

Spigelian hernia (Fig 4), is a protrusion of preperitoneal fat, a sac of peritoneum or an organ through a congenital defect or acquired weakness in the Spigelian fascia.<sup>3</sup> The semilunar line run from the 9<sup>th</sup> rib cartilage superiorly to pelvic tubercle inferiorly. Spigel<sup>1</sup> originally intended this structure to represent line of transition from the muscular fibres of the transverse abdominal muscle to the posterior aponeurosis of rectus. The Spigelian fascia varies in width along the semilunar line and it gets wider as it approaches the umbilicus. The widest portion of the spigelian fascia is the area where the semilunar line intersect the arcuate line of Douglas (the line semilunaris) (Figure 5). The majority of Spigelian hernia are found in transverse band lying 0 to 6 cm cranial to a line running between both anterior superior iliac spines referred to as the Spigelian hernia belt where the Spigelian fascia is the widest.<sup>4</sup>



**Figure 5: Most common site of Spigelian hernia.**

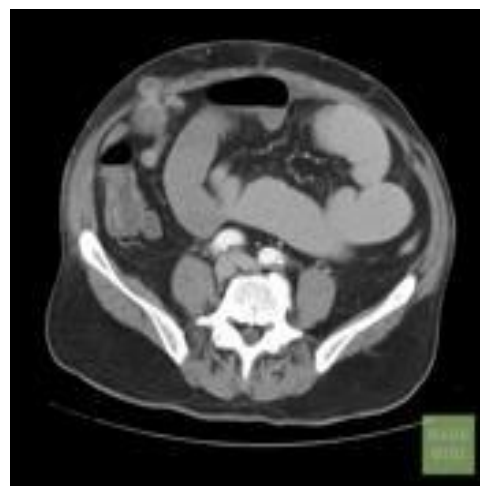The overlying external oblique muscle and fascia remain intact as it does not undergo rearrangement of aponeurotic fibres at the arcuate line. The hernia also cannot develop medially as due to resistance for the intact rectus muscle and sheath. Therefore a large Spigelian hernia is most often found lateral and inferior to its defect in the space directly posterior to the internal oblique muscle.

Spigelian hernias are very uncommon and constitute only 0.12% of all the abdominal wall hernia. The hernia appear to peak in 4<sup>th</sup> to 7<sup>th</sup> decades.<sup>5</sup> The male to female ratio is 1:1.18.<sup>6</sup> The most common sac content is omentum but intestine, appendix, gall bladder, stomach or ovary have been reported.<sup>6</sup>

20% of Spigelian hernia will present as incarcerated hernias.<sup>7</sup> Symptoms can vary from abdominal pain, lump in the anterior abdominal wall or patient may have history of incarceration with or without intestinal obstruction.<sup>7</sup> Pain aggravates on manoeuvre that increase in the abdominal pressure and is relieved by rest.

Spigelian hernia occurs in two variants - acute and chronic incidental. In first type patient presents as acute abdomen, require urgent investigation and surgical treatment. In second type it is diagnosed incidentally while investigating recurrent abdominal pain. The appearance of lesion is comparable with other structures and around abdominal wall including rectus sheath, hematoma, serosa, parietal abscess, lipoma, peritoneal tumour implants and pseudocyst at the end of the ventriculo-peritoneal shunts.<sup>8</sup>

Good clinical examination can detect this entity but when diagnosis is in doubt radiological imaging may be necessary. USG has been shown to be most reliable and easier method to assist in diagnostic workup. Ultrasound show the break in echogenic shadow of the semilunar like associated with fascial defect and also identify the sac. CT will confirm the diagnosis (Figure 6).



**Figure 6: CT scan showing right Spigelian hernia.**

Treatment of Spigelian hernia is operative repair once the diagnosis has been confirmed given the risk of incarceration. This is usually performed under GA given the need for splitting of the external oblique muscle. Nozoe et al.<sup>9</sup> performed a simple hernioraphy by suturing the internal oblique and transverse abdominus muscle to the rectus sheath. Prosthetic mesh is not required for this repair, although use of mesh plug to close the hernia defect has been described.<sup>10</sup> The advent of laparoscopy has made then conventional approach old fashioned in experienced hands.<sup>11</sup> Spigelian hernia are ideally suited to preperitoneal laparoscopic repair because the defect is more clearly identified in the preperitoneal plane and best results are offered by the extra peritoneal laparoscopic approach as compared to intra-abdominal laparoscopic approach.<sup>12</sup>

In our case, patient presented with a chronic spigelian hernia where a standard on-lay meshplasty was done.

*Funding: No funding sources*

*Conflict of interest: None declared*

*Ethical approval: Not required*

## REFERENCES

1. Spiegel, Adriaan Van Den. (also Spieghel, Spigelius, Spiegelius, Adriano Spigeli). Botany, anatomy, medicine. (b. Brussels, Belgium, 1578; d. Padua, Italy, 7 April 1625), Available at: <http://www.encyclopedia.com/doc/1G2-2830904102.html>.
2. Klinkosch JT. Programma quo divisionem herniarum, novumque herniae ventralis speciem proponit. Rotterdam: Benam; 1764.
3. Spangen L. Spigelian hernia. Surg Clin North Am. 1984;64:351-66.
4. Ray NK, Sreeramulu PN, Krishnaprasad K. Spigelian hernia: fascia lata repair is an alternative option in absence of prolene mesh. JIMA. 2002 Jun;100:370-1.

5. Spangen L. Spigelian hernia. *World J Surg.* 1989;13(5):573-80.
6. Howlihan TJ. A review of Spigelian hernia. *Am J Surg.* 1976;131:734-5.
7. Javed PJ, Grenberg GA, Brooks DC. Spigelian hernia. In: Zinner MJ, Ashley SW, eds. *Maingots Abdominal Operations.* 12th ed. New York: McGraw Hill Medical; 2013: 123-155.
8. Raveenthiran V, Pichumani S. Richter's hernia in Spigelian hernia. *Indian J Gastroenterol.* 2000;19:36-7.
9. Nozoe T, Funahashi S, Kipamura M, Ishikawa H, Suehiro T, Iso Y, et al. Ileus with incarceration of Spigelian hernia. *Hepatogastroenterology.* 1999;46:1010-2.
10. Testa T, Fallo E, Celoria G, Beatini M, Rollandi R, Nardini A, et al. Spigelian hernia: its echotomographic diagnosis and surgical treatment. *G Chir.* 1992;13:29.
11. Gedeban TM, Neubauer W. Laparoscopic repair of bilateral Spigelian and Inguinal hernias. *Surg Endosc.* 1998;12:1424.
12. Moreno-Egea, Flores B, Girela E, Martin JG, Aguayo JL, Canteras M. Spigelian hernia: bibliographical study and presentation of a series of 28 patients. *Hernia.* 2002;6:167-70.

**Cite this article as:** Mhatre HP, Kanake VB, Nandu VV. Spigelian hernia: a rare case presentation. *Int Surg J* 2015;2:717-20.