

Case Report

Ventricular migration of shunt: Chhabra shunt complication

Arvind Malhotra^{1*}, Mini Malhotra²

¹Department of General Surgery, Govt. Medical College, Chandigarh, India

²Consultant Pediatrician, Esi Hospital Ram Darbar, Industrial Area, Chandigarh, India

Received: 03 August 2015

Revised: 04 August 2015

Accepted: 20 August 2015

***Correspondence:**

Dr. Arvind Malhotra,

E-mail: arvindmalhotra74@yahoo.com

Copyright: © the author(s), publisher and licensee Medip Academy. This is an open-access article distributed under the terms of the Creative Commons Attribution Non-Commercial License, which permits unrestricted non-commercial use, distribution, and reproduction in any medium, provided the original work is properly cited.

ABSTRACT

We report a rare complication of Intraventricular migration of whole shunt and discuss the causes of this complication. A 9-month-old child presented in OPD with enlarging head and vomiting. The patient had undergone VP shunt twice before due to congenital hydrocephalus. Imaging was done which suggested of Intraventricular migration of complete shunt. The patient was posted for surgery and the shunt was removed from the lateral ventricle. Patient recovered well and has been followed up for 1 year till the writing of this report. After careful review of literature we found twenty reported cases of intra cranial migration of VP shunts. The probable causes of retrograde migration include technical issues like large burr hole and wide opening of Dura. An increasing number of reported cases are from Indian subcontinent and mostly the Chhabra shunt is implicated in this complication. The probable reasons for migration are: 1) Malnourished infant with thin cortical mantle, large ventricles having reduced pressure and raised intraabdominal pressure due to excess amount of CSF not absorbed in peritoneum. 2) Poor anchorage of shunt chamber along with indiscriminate pressing of cylindrical Chhabra shunt reservoir. To prevent it special care must be taken in neonates and infants in making smaller burr holes, smaller chamber area and stronger anchorage of shunt chamber to periosteum. Further instead of using the cylindrical Chhabra chambers which can easily migrate to ventricles, larger spherical chambers may be used.

Keywords: Ventricular migration, Chhabra shunt, Complications of shunt, Ventricular peritoneal shunt

INTRODUCTION

Shunt insertion is one of the commonest neurosurgical procedures done. It's a notorious procedure with many complications ranging from blockage, infection, migration to peritoneal cavity, bladder, pleural cavity.¹⁻⁴

We are reporting the rarest complication in which there was complete migration of whole shunt into the ventricles and discuss the reported cases and try to form a hypothesis about the causes of this complication.

CASE REPORT

A 9 month old child presented in neurosurgical OPD with enlarging head and episodes of fever and vomiting in past two days. Previously the patient had undergone ventriculo peritoneal shunt two times due to congenital hydrocephalus. The child was first operated at age of 3 months and subsequently at 6 months due to shunt blockage.

Clinical examination revealed malnourished child with enlarged head. The anterior fontanelle was bulging and non-pulsatile. Sun set sign was present and child was drowsy. There was a bulge present at the site of previous

burr hole on left side; possibly a pseudomeningocele. There was no palpable shunt chamber and a thick fibrous track could be felt in the whole course of shunt.

CT Brain and X-ray Skull lateral was done. X-ray skull suggested of intraventricular migration of complete shunt (Figure 1) showing the cylindrical slit valve chamber clearly. The CT Brain suggested of subdural hygroma with septations around the coiled shunt tubing with decompressed ventricles (Figure 2).

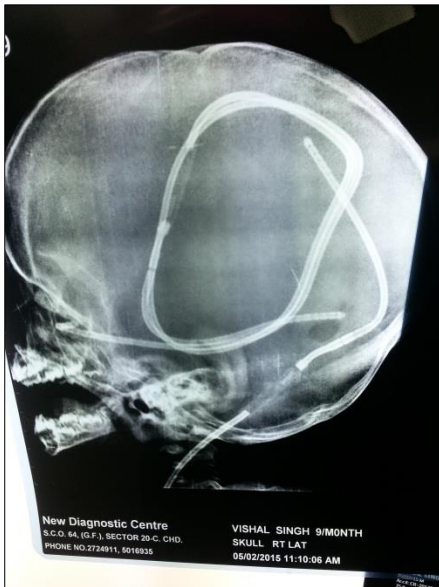

Figure 1: X-ray showing complete shunt in the intracranial cavity.

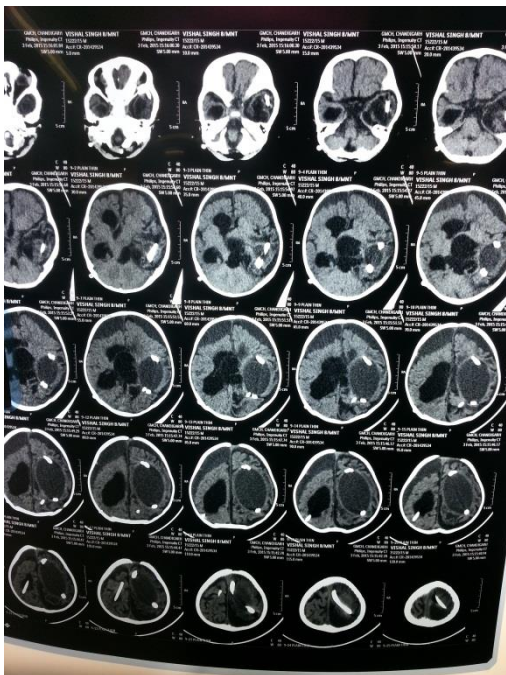


Figure 2: CT Brain (non-contrast) intraventricular ventriculoperitoneal shunt with a cyst and subdural hygroma.

The child was posted for surgery. Ventriculo peritoneal shunt was done on right side and child improved clinically.

Subsequently, the patient was again posted for surgery for removal of left sided intraventricular shunt. A small left parietal craniotomy was done around the previous burr hole. Dura was opened to reveal yellowish colored subdural fluid and septations; the lateral ventricle also had septations, which were carefully cut. There were septations in ventricle around the shunt with fluid collections and the tip of shunt was adhered to choroid plexus. Careful dissection and coagulation were used to free the end and after ensuring complete haemostasis, the wound was closed (Figure 3). Patient recovered well and has been followed up for 1 year till the writing of this report.

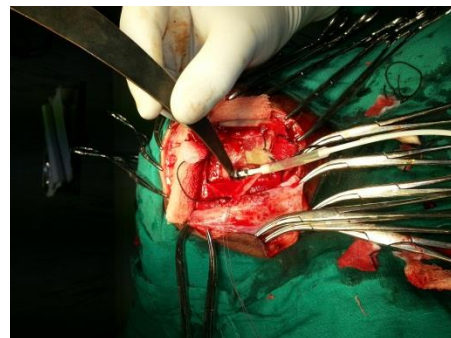

Figure 3: Operative photograph shows shunt chamber being taken out from lateral ventricle.

DISCUSSION

Complete migration of shunt has been reported as a rare shunt complication in 0.1-0.4% of shunt procedures.² After careful review of literature we found twenty reported cases of intra cranial migration of ventriculoperitoneal shunts as shown in Table 1. Vast majority of cases 70 percent were from Indian subcontinent.^{1-3,10,11,13,16,17,19,22}

Almost all have reported such cases in malnourished infants with complicated postoperative course.¹⁻²⁰ Heim and Kim have reported migration of ventriculoperitoneal shunt to subgaleal and subdural spaces.^{4,5}

The probable cause of retrograde migration is a much debated subject with numerous hypothesis forwarded in literature. One of the earliest reported cases of complete Intraventricular migration of shunt systems were in 70s by Mori & Villarejo.^{6,7} Mori explained the migration of shunt tubes to ventricle due to technical issues like large burr hole and wide opening of dura and poor anchorage of shunt chamber to periosteum.⁶ Young described two cases and implicated excessive neck movements in infants due to seizures creating a windlass effect leading to the migration.⁸ Garijo is the only author describing retrograde migration in adult ventricle and suspects a

peritoneal cyst formed at end of shunt tube as a cause.¹⁰ Further thin mantle of skull in these debilitated infants is associated with reduced intracranial pressure and peritoneal scarring leading to reduced absorption of CSF and in turn increasing intraabdominal pressure which pushes the shunt into the ventricles.⁹ The straight course of shunt from occiput to peritoneum, short distance in infants and large ventricles have also been thought to be probable causes of retrograde migration.⁸

Table 1: Review of literature we found twenty reported cases of intra cranial migration of ventriculoperitoneal shunts.

Name of author and year	Number of cases reported
Mori k 1975	1
Gariejo JA 1979	1
Villarejo F in 1979	1
Drigo G in 1983	2
Young HA in 1983	2
Abou el Nasr HT in 1988	1
Eljamel MS in 1995	1
Gupta PK in 1999	1
Acharya R in 2002	1
Shimzu in 2002	1
C. Pereira 2004	1
Nadkarni TD in 2007	1
Oluwole KE in 2007	1
Ali MN in 2008:	1
Aggarwal A in 2011	1
Vikas Naik 2013	1
Rakesh Kumar Sharma in 2015	1

An increasing number of reported cases are from Indian subcontinent and mostly the Chhabra shunt is implicated in this complication.^{1-3,10,11,13,16,17,19,21,22} The cylindrical soft chamber and the practice of repeated pressing of chamber to flush the chamber may be one of the important causes along with the above ones in pushing the shunt retrogradely into ventricles. A case of intracranial migration has known to cause visual disturbances; maybe due to pressure on optic pathways and raised intracranial pressure.¹⁰

Intraventricular shunts can be safely removed by endoscopic use² or by craniotomy.¹¹ However extreme precaution is to be exercised in achieving complete hemostasis as cases of death are reported while removing these shunts.¹² The tip of shunt is generally adherent to choroid plexus and has to be carefully excised.²

CONCLUSIONS

Total migration of ventriculoperitoneal shunt into the lateral ventricles is a rare complication. The probable reasons for migration are

1. Malnourished infant with thin cortical mantle, large ventricles having reduced pressure and raised intraabdominal pressure due to excess amount of CSF not absorbed in peritoneum due to varying reasons.
2. Irritable infant with excessive crying, neck movements and a straight course of shunt from occiput to peritoneum.
3. Poor anchorage of shunt chamber along with indiscriminate pressing of cylindrical Chhabra shunt chamber.

To prevent it special care must be taken in neonates and infants in making smaller burr holes, smaller chamber area and stronger anchorage of shunt chamber to periosteum. Further instead of using the cylindrical Chhabra chambers that can easily migrate to ventricles, larger spherical chambers may be used and the relatives counseled carefully on how to press the chamber.

Abbreviations

VP - Ventriculo peritoneal
OPD - Outdoor patient department
CSF - Cerebro spinal fluid

Funding: No funding sources

Conflict of interest: None declared

Ethical approval: The study was approved by the institutional ethics committee

REFERENCES

1. Choudhury AR. Avoidable factors that contribute to the complications of ventriculoperitoneal shunt in childhood hydrocephalus. Childs Nerv Syst. 1990;6:346-9.
2. Naik V, Phalak M, Chandra PS. Total intracranial shunt migration. J Neurosci Rural Pract. 2013;4:95-6.
3. Ghritlaharey RK, Budhwani KS, Shrivastava DK, Gupta G, Kushwaha AS, Chanchlani R, et al. Trans-anal protrusion of ventriculo-peritoneal shunt catheter with silent bowel perforation: report of ten cases in children. Pediatr Surg Int. 2007;23:575-80.
4. Heim RC, Kaufman BA, Park TS. Complete migration of peritoneal shunt tubing to the scalp. Childs Nerv Syst. 1994;10:399-400.
5. Kim KJ, Wang KC, Cho BK. Proximal migration and subcutaneous coiling of a peritoneal catheter: Report of two cases. Childs Nerv Syst. 1995;11:428-31.
6. Mori K, Yamashita J, Handa H. "Missing tube" of peritoneal shunt: migration of the whole system into ventricle. Surg Neurol. 1975;4:57-9.
7. Villarejo F, Alvarez-Sastre C, Gimenez D, Gonzalez C. Migration of an entire one-piece shunt into the ventricle. Neurochirurgia (Stuttg). 1979;22:196-8.

8. Young HA, Robb PJ, Hardy DG. Complete migration of ventriculoperitoneal shunt into the ventricle: Report of two cases. *Neurosurgery.* 1983;12:469-71.
9. Garijo JA, Pecourt JC, de la Resurreccion M. Migration of ventriculo-peritoneal shunt into lateral ventricle of an adult. *Surg Neurol.* 1979;11:399-400.
10. Shimizu S, Mochizuki T, Nakayama K, Fujii K. Visual field defects due to a shunt valve migrating into the cranium. *Acta Neurochir (Wien).* 2002;144:1055-6.
11. Nadkarni TD, Menon RK, Dange NN, Desai KI, Goel A. Cranial migration of complete ventriculoperitoneal shunt assembly. *J Clin Neurosci.* 2007;14:92-4.
12. Sharma S, Gupta DK. Intraventricular migration of an entire vp shunt. *Indian Pediatr.* 2005;42:187-8.
13. Abou el Nasr HT. Modified method for prophylaxis against unishunt system complications with presentation of total intraventricular migration of unisystem ventriculoperitoneal shunt. *Childs Nerv Syst.* 1988;4:116-8.
14. Acharya R, Bhutani A, Saxena H, Madan VS. Complete migration of ventriculoperitoneal shunt into the ventricle. *Neurol Sci.* 2002;23:75-7.
15. Ahmed Ammar, Munear Nasser. Intraventricular migration of VP shunt. *Neurosurg Rev.* 1995;18(4):293-5.
16. Ali MN, Atif SM, Khan S. Intracranial migration of a ventriculoperitoneal shunt. *J Coll Physicians Surg Pak.* 2008;18:382-3.
17. Agarwal A, Kakani A. Total migration of a ventriculo-peritoneal shunt catheter into the ventricles. *J Pediatr Neurosci.* 2011;6:88-9.
18. Chauhan H, Jain R, Rath G, Prabhakar H. Upward migration and subcutaneous coiling of the ventriculo-peritoneal shunt catheter: a case report. *Internet J Neurosurg.* 2006;3:1.
19. Eljamel MS, Sharif S, Pidgeon CN. Total intraventricular migration of unisystem ventriculoperitoneal shunt. *Acta Neurochir (Wien).* 1995;136:217-8.
20. Gupta PK, Dev EJ, Lad SD. Total migration of a ventriculoperitoneal shunt into the ventricles. *Br J Neurosurg.* 1999;13:73-4.
21. Oluwole KE, Abiodun AA. Complete intraventricular migration of a ventriculo-peritoneal shunt-a case report and brief literature review. *Afr J Neurol Sci.* 2007;26:69-74.
22. Sharma RK, Bansal M, Agrawal M, Gupta A, Sinha VD. Complete intracranial migration of a ventriculoperitoneal shunt: rare complication of a common procedure. *Neurol India.* 2015 Jan-Feb;63(1):106-7.

Cite this article as: Malhotra A, Malhotra M. Ventricular migration of shunt: Chhabra shunt complication. *Int Surg J* 2015;2:706-9.