

Original Research Article

A comprehensive study of diabetic foot ulcer with special reference to magnetic resonance imaging

Manoj Kumar¹, Akash Chandra^{2*}, Krishna Gopal¹

¹Department of Surgery, IGIMS, Patna, Bihar, India

²Department of Pharmacology, SNMMCH, Dhanbad, Jharkhand, India

Received: 21 July 2021

Revised: 13 December 2021

Accepted: 15 December 2021

*Correspondence:

Dr. Akash Chandra,

E-mail: drakash1984@gmail.com

Copyright: © the author(s), publisher and licensee Medip Academy. This is an open-access article distributed under the terms of the Creative Commons Attribution Non-Commercial License, which permits unrestricted non-commercial use, distribution, and reproduction in any medium, provided the original work is properly cited.

ABSTRACT

Background: This pictorial review aims to illustrate the various manifestations of the diabetic foot on magnetic resonance (MR) imaging. The utility of MR imaging and its imaging features in the diagnosis of pedal osteomyelitis are illustrated. There is often difficulty encountered in distinguishing osteomyelitis from neuroarthropathy, both clinically and on imaging. By providing an accurate diagnosis based on imaging, the radiologist plays a significant role in the management of patients with complications of diabetic foot.

Methods: This is a prospective and observational study conducted on 50 patients with diabetic foot ulcer admitted in general surgical ward of Indira Gandhi Institute of Medical Sciences (IGIMS), Patna, Bihar. Required pathological or biochemical assessments like complete blood count (CBC), fasting blood sugar (FBS), post prandial blood sugar (PPBS), random blood sugar (RBS), hemoglobin A1c (HbA1C), liver function test (LFT), kidney function test (KFT), serum electrolytes and other relevant investigations will be done on admission. Further magnetic resonance imaging (MRI) will be done in radiological investigations and findings will be noted.

Results: In the case of early osteomyelitis, the rate and accuracy of detection is at best 50–60%, as the soft tissues are not adequately demonstrated. For the assessment of soft tissue infection and osteomyelitis involving the foot, MRI is the modality of choice.

Conclusions: It has been shown that MRI, in combination with radiography, is the most accurate in the detection of diabetic pedal osteomyelitis and its differentiation from neuroarthropathy. Males are more affected than females in case of soft tissue infections and joint complications.

Keywords: Diabetic foot, Diabetes mellitus complications, Foot infection, Neuroarthropathy, Osteomyelitis

INTRODUCTION

Diabetes mellitus is a group of metabolic disorders characterized by a high blood sugar level over a prolonged period of time. Symptoms often include frequent urination, increased thirst and increased appetite. If left untreated, diabetes can cause many health complications. Acute complications can include diabetic ketoacidosis, hyperosmolar hyperglycemic state, or death.¹ Serious long-term complications include cardiovascular disease, stroke, chronic kidney

disease, foot ulcers, damage to the nerves, damage to the eyes and cognitive impairment.² Diabetic foot ulcer is a major complication of diabetes mellitus, and probably the major component of the diabetic foot. Risk factors implicated in the development of diabetic foot ulcers are infection, older age.³ Other risk factors are diabetic neuropathy, peripheral vascular disease, cigarette smoking, poor glycemic control and previous foot ulcerations.⁴ Treatment of diabetic foot ulcers should include: blood sugar control, removal of dead tissue from the wound, wound dressings, and removing pressure from

the wound through techniques such as total contact casting. Surgery in some cases may improve outcomes.⁵ Hyperbaric oxygen therapy may also help but is expensive.⁵ Almost all diabetic foot infections are due to direct spread from a skin ulcer.⁶ The diabetic foot is prone to skin ulceration due to associated risk factors such as microangiopathy with peripheral neuropathy, and altered biomechanics. Unrecognized trauma, in the background of these risk factors, results in superimposed infection and restricts healing.⁷ Another significant route of infection is related to surgery or penetrating trauma, where infectious material may be directly implanted. Haematogenous spread of infection rarely involves the foot but may be seen in the paediatric population, or with atypical organisms such as *Mycobacterium tuberculosis*.⁸

METHODS

This is a cross-sectional and observational study conducted on 50 patients with diabetic foot ulcer admitted in general surgical ward of Indira Gandhi Institute of Medical Sciences (IGIMS), Patna, Bihar. Required pathological or biochemical assessments like complete blood count (CBC), fasting blood sugar (FBS), post prandial blood sugar (PPBS), random blood sugar (RBS), hemoglobin A1c (HbA1C), liver function test (LFT), kidney function test (KFT), serum electrolytes and other relevant investigations will be done on admission. Further MRI will be done in radiological investigations and findings will be noted. Patients will also be taken care of their treatment regarding insulin or oral hypoglycemic drugs dosage and to prevent any hypoglycemic episode. Patients will be followed up till discharge.

Aims and objectives

Aims and objectives include: to study the clinical features and findings in diabetic foot ulcer patients; to study complications in diabetic foot ulcer; radiological investigations like X-ray and magnetic resonance imaging (MRI) and its findings; and differentiating between osteomyelitis and neuroarthropathy using MRI.

Inclusion criteria

Diabetic patients diagnosed with diabetic foot ulcer, and patients aged above than 40 years were included in the study.

Exclusion criteria

Patients aged less than 40 years, patients suffering from other infectious disease, and patients who have left hospital against medical advices were excluded.

On the basis of MRI results two groups have been created as group A and group B. The group A contains total 21 patients possess soft tissue infections and group B contains total 29 patients possess bone and joint complications.

Duration of study

The duration of the study was from 01 October 2020 to 31 March 2021 (a total of six months).

Approval from ethical committee

This study has been approved from institutional ethics committee at IGIMS Patna, Bihar.

RESULTS

In the case of early osteomyelitis, the rate and accuracy of detection is at best 50–60%, as the soft tissues are not adequately demonstrated. For the assessment of soft tissue infection and osteomyelitis involving the foot, MR imaging is the modality of choice. Male patients are more prone to develop soft tissue infections and joint complications as compared to female patients after infection of diabetic foot ulcer (Table 1).

Table 1 shows the sex distribution. Total 21 patients have been enrolled in group A in which there are 15 male patients and 6 female patients. Total 29 patients have been enrolled in group B in which there are 20 male patients and 9 female patients.

Table 1: Sex distribution.

Characteristics of patients	Group A	Group B
Total no. of patients entering the study	21	29
Male	15	20
Female	6	9

Table 2 shows the age distribution among group A and group B in which average age of male and female in group A is 59.26 year and 59.5 year and in group B is 54 and 64.1 year.

Table 2: Age distribution (in years).

Sex	Average age of group A	Average age of group B
Male	59.26	54
Female	59.5	64.1

Table 3 shows the soft tissue infections as gangrene, cellulitis, abscess, ulcer and skin callus among 21 patients of group A in which 15 patients are male and 6 patients are female.

Table 4 shows the bone and joint complications among 29 patients in which 20 patients are male and 9 patients are female. Among male patients 7 patients showing the features of osteomyelitis and 13 patients showing the features of neuroarthropathy. Among female patients 4 patients showing the features of osteomyelitis and 5 patients showing the features of neuroarthropathy.

Table 3: Magnetic resonance imaging showing soft tissue infections in group A.

Soft tissue infections	No. of male patients suffered	No. of female patients suffered	Total
Gangrene	3	1	4
Cellulitis	1	1	2
Abscess	5	1	6
Ulcer	4	1	5
Skin callus	2	2	4

Table 4: Magnetic resonance imaging showing bone and joint complications in group B.

Bone and joint complications	No. of male patients affected	No. of female patients affected	Total
Osteomyelitis	7	4	11
Neuroarthropathy	13	5	18

DISCUSSION

Neuroarthropathy and osteomyelitis often occur concurrently in the diabetic foot, but either of them may be more prominent. It is clinically and radiologically challenging to distinguish between these two entities. Both conditions may show marrow oedema and enhancement, joint effusion, as well as adjacent soft tissue oedema. Apart from analyzing the MRI features, correlation with clinical findings is also necessary in order to arrive at an accurate diagnosis.⁹

In this pictorial review, we illustrate the MRI appearances of diabetic foot complications, including osteomyelitis, and also discuss the MRI appearance of neuroarthropathy, both with and without coexisting infection.

On the basis of results of MRI, it is clear that soft tissue infections and joint complications are more in male patients as compared to female patients. Among male patients neuroarthropathy is more than osteomyelitis. Neuroarthropathy also known as Charcot joint after the first to describe it, Jean-Martin Charcot, refers to progressive degeneration of a weight-bearing joint, a process marked by bony destruction, bone resorption, and eventual deformity due to loss of sensation. Onset is usually insidious. Once the process is recognized, it should be treated via the—vascular management, infection management and prevention (VIPs), and pressure relief.¹⁰ Aggressively pursuing these three strategies will progress the healing trajectory of the wound.¹⁰

Osteomyelitis is an infection of bone, symptoms may include pain in a specific bone with overlying redness, fever, and weakness. The long bones of the arms and legs are most commonly involved in children e.g. the femur and humerus.¹¹

Diagnosis of osteomyelitis is complex and relies on a combination of clinical suspicion and indirect laboratory markers such as a high white blood cell count and fever, although confirmation of clinical and laboratory suspicion with imaging is usually necessary.¹²

Differentiating osteomyelitis from neuroarthropathy

While neuroarthropathy is primarily articular, osteomyelitis virtually always occurs by direct extension from skin ulcers at typical sites. The presence of marrow oedema and periarticular disease with no adjacent ulcer is highly suggestive of neuroarthropathy. Superimposed osteomyelitis usually shows diffuse marrow changes, whereas neuroarthropathy often shows periarticular marrow changes, since the pathology centres on the joint (Figure 2).

Location is the most helpful feature in discriminating between osteomyelitis and neuroarthropathy. Most of the time, neuroarthropathy involves the tarsometatarsal and metatarsophalangeal joints, while osteomyelitis commonly involves the calcaneum, malleoli and bones distal to the tarsometatarsal joint. The biggest diagnostic problem arises in the midfoot, particularly when pre-existing neuroarthropathy is present. In such cases, secondary signs of infection are invaluable in determining the presence of osteomyelitis.

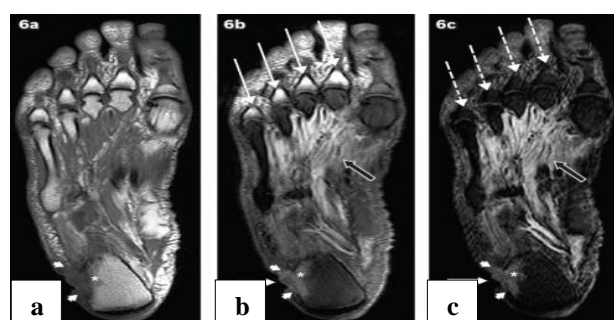


Figure 1: A 60-year-old man presented with a chronic ulcer on the lateral aspect of the right heel, with symptoms of infection. Axial (a) T1-W, (b) T2-W FS and (c) STIR MR images of the right foot show an ulcer (white arrows) along the lateral aspect of the heel with surrounding cellulitis (arrowheads). Low T1-W and high T2-W marrow signals in the adjacent calcaneum, with associated cortical ill-definition, suggest osteomyelitis.

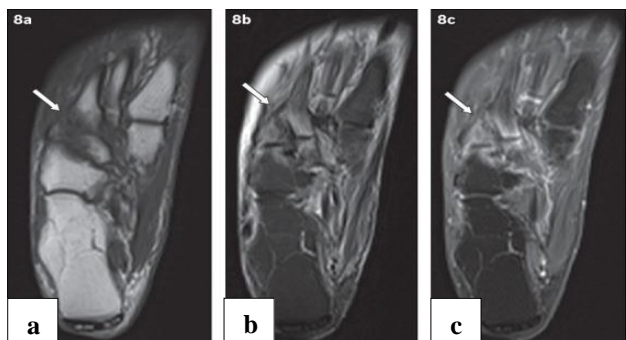


Figure 2: An 81-year-old woman presented with tenderness over the dorsum of the right foot, with associated inflammatory skin changes. Axial (a) T1-W, (b) T2-W FS and (c) contrast-enhanced T1-W FS MR images of the right foot show periarticular high T2-W signal with corresponding enhancement, centred on the tarsometatarsal joints (arrows). The typical location, coupled with the absence of other secondary soft tissue signs of infection (e.g. ulcer, cellulitis, abscess, sinus tract), indicated the diagnosis of acute neuroarthropathy.

Limitations

MRI is currently most sensitive modality for evaluation of soft tissue and bone marrow changes in diabetic foot. Bone marrow oedema is early detected in MRI which is present in neuroarthropathy and osteomyelitis. MRI also helps to accuracy in delineation of extension of infection in diabetic foot. It helps in differentiation among soft tissue infection, osteomyelitis, neuroarthropathy and marrow effusion which is more sensitive in early stage of infection and opened wound.

CONCLUSION

MRI is increasingly available and currently the imaging modality of choice in the assessment of osteomyelitis and soft tissue complications in the diabetic foot. Due to the myriad manifestations and at times overlapping features of these complications, diagnosis via MRI can be challenging. It was the objective of this article to illustrate the MRI appearances and provide a strategy in the interpretation of MR images of diabetic foot complications. Familiarity with the specific technical requirements of MRI and the imaging features of these conditions will enable the radiologist to contribute significantly to patient management.

Funding: No funding sources

Conflict of interest: None declared

Ethical approval: The study was approved by the Institutional Ethics Committee

REFERENCES

1. Kitabchi AE, Umpierrez GE, Miles JM, Fisher JN. Hyperglycemic crises in adult patients with diabetes. *Diabetes Care*. 2009;32(7):1335-43.
2. Saedi E, Gheini MR, Faiz F, Arami MA. Diabetes mellitus and cognitive impairments". *World J Diabetes*. 2016;7(17):412-22.
3. Turns M. The diabetic foot: an overview for community nurses. *Br Comm Nurs*. 2012;17(9):422.
4. Boulton AJ. The diabetic foot. *Medicine*. 2019;47(2):100-5.
5. Yazdanpanah L, Nasiri M, Adarvishi S. Literature review on the management of diabetic foot ulcer. *World J Diabetes*. 2015;6(1):37-53.
6. Lipsky BA, Pecoraro RE, Wheat LJ. The diabetic foot. Soft tissue and bone infection. *Infect Dis Clin North Am*. 1990;4:409-32.
7. Stadelmann WK, Digenis AG, Tobin GR. Impediments to wound healing. *Am J Surg*. 1998;176(2):39-47.
8. Chen SC, Huang SC, Wu CT. Non spinal tuberculous osteomyelitis in children. *J Formos Med Assoc*. 1998;97:26-31.
9. Marcus CD, Ladam-Marcus VJ, Leone J. MR imaging of osteomyelitis and neuropathic osteoarthropathy in the feet of diabetics. *Radio graphics*. 1996;16:1337-48.
10. Snyder RJ, Frykberg RG, Rogers LC, Applewhite AJ, Bell D, Bohn G, et al. The management of diabetic foot ulcers through optimal off-loading: building consensus guidelines and practical recommendations to improve outcomes. *J Am Podiatr Med Assoc*. 2014;104(6):555-67.
11. El-Sobky T, Mahmoud S. Acute osteoarticular infections in children are frequently forgotten multidiscipline emergencies: beyond the technical skills. *EFORT Open Reviews*. 2021;6(7) 584-92.
12. Howe BM, Wenger DE, Mandrekar J, Collins MS. T1-weighted MRI imaging features of pathologically proven non-pedal osteomyelitis. *Academic Radiology*. 2013;20(1):108-14.

Cite this article as: Kumar M, Chandra A, Gopal K. A comprehensive study of diabetic foot ulcer with special reference to magnetic resonance imaging. *Int Surg J* 2022;9:133-6.